LANE MEDICAL LIBRARY STANFORD
L656 .B29 1926 OLD
The surgical treatment of goiter / by Wi
24503231435

LANE

MEDICAL LIBRARY

LEVI COOPER LANE FUND

# THE SURGICAL TREATMENT OF GOITER

# THE SURGICAL TREATMENT OF GOITER

BY

WILLARD BARTLETT, A.B., A.M., M.D., D.Sc., F.A.C.S.

ST. LOUIS

WITH FOREWORD BY

DR. CHARLES H. MAYO

ROCHESTER, MINN.

*WITH 130 ORIGINAL ILLUSTRATIONS*

ST. LOUIS

THE C. V. MOSBY COMPANY

1926

COPYRIGHT, 1926, BY THE C. V. MOSBY COMPANY

*(All rights reserved)*

Printed in U. S. A.

*Press of*
*The C. V. Mosby Company*
*St. Louis*

B29
1926

THIS BOOK IS DEDICATED TO

GENEVIEVE WILSON BARTLETT

MY WIFE

WHOSE EVERY INFLUENCE HAS BEEN STIMULATING

©1921

Digitized by the Internet Archive
in 2025

https://archive.org/details/surgicaltreatmen0000will

# PREFACE

A glance backward now and then convinces one anew that environment subtly forces us into paths we often think we choose to tread. This seems true in the career of the physician at least. One becomes interested, as a matter of course, in the type of malady that afflicts his neighbors, especially if many of them happen to be his acquaintances or even some of them his friends. My predilection for this subject has been stimulated no little, I am sure, by the fact that the valleys of the Mississippi and Missouri rivers constitute endemic goiter regions tributary to St. Louis.

It is not claimed by any surgeon having authority in this field that all goiters are to be operated upon, still I must, with a regard for brevity, confine myself to the needs of those that are commonly thought suited to this kind of treatment.

Every surgeon familiar with thyroid work realizes the need of a highly specialized operative technic, if due respect is to be accorded a gland of altered consistence, vessels increased in size or number, and near-by structures of undoubted importance. Especially fortunate in this field is the operator possessing an innate delicacy of touch akin to that displayed by the cat in playing with the mouse. One can, no doubt, cultivate this to some extent at least by practicing upon the piano or upon the smaller stringed instruments and thus acquire the highest degree of finish possible in a given instance. Goiter surgery seems to me to demand the light sure hand of the man who can shave himself rapidly using the old-type straight razor without accident; but no matter what the degree of native or acquired refinement, it is only by daily participation in thyroid operations that the reflexes become trained to know exactly the force that will separate areolar tissue about the gland without tearing the communicating veins. I believe I am safe in saying that a special technic, comparable to that of the brain surgeon, applied to this field is indispensable to the future development of it.

I hardly see how the operations for goiter can fail to make a strong appeal to the man who leans toward the artistic in surgery, who is something of a practical mechanic, and who has the patience to attend to every one of the many small details which make up one of these sometimes complicated procedures. But the lure of this field grows when the student begins to realize that goiter types differ in infinite variety, that treatment entails individualization, and indeed that operative technic of appropriate sort must fit into each picture.

The ultimate of success in this branch of surgery is attainable only when one contemplates in every thyroid patient the individual as a whole rather than concentrates on the goiter alone, though it may for the moment obtrude itself as the most conspicuous of the many interdependent components, now temporarily out of balance, which together constitute the organism.

All patients on whom this study is based were treated under similar conditions in one hospital where it was possible for me to be in most intimate touch with them. Every observation was immediately and faithfully recorded in the hope that when all were blended a composite picture of thyroid disease and its treatment might be presented. I shall not burden my readers with a statistical report of our results. They differ in no wise from those attained in other clinics where special study is accorded this subject by a group of men whose efforts are combined toward shielding the patient until he becomes a reasonably safe surgical risk.

One is inclined when in the mood for speculation to borrow from the nomenclature of the chemist and compare the qualitative and quantitative phases of goiter surgery. Under the former we do not kill the patients, we get the gland out and cure many. Future advances, however, must come along the latter line, viz., we must give more regard to the period of disability, the cosmetic results, and a guarantee against recurrence. I trust in this connection that an idealistic tendency may seem to prevail in what is to come.

Treatment may be said, by way of simile, to represent the apex of a pyramid, which has in its supporting layers all the

important fundamental considerations involved in the goiter problem. It has seemed better to avoid repetition by omitting all but passing reference to these latter, since they have all been so recently and adequately covered in the more general works of Crile, Grotti, Hertzler, and DeQuervain.

This monograph is intended as a study in detail of the elaborate procedure involved today in the preparation, operation, and after-care of the goiter patients who present themselves at the clinic with which I am connected. It is written in the hope that it may appeal to the well-trained young general surgeon who is inclined to broaden his experience in the special field of thyroid surgery. If it proves to be a short cut for him or if it adds anything to the safety and comfort of his patients, its mission will have been accomplished.

I desire to express my gratitude to Doctors Louis B. Wilson, Samuel B. Grant, and French K. Hansel for the chapters which they have contributed.

I am indebted to Dr. H. W. Harper, Jr., and to Miss Charlotte McElroy, my assistants, for their many suggestions based upon their knowledge of our own handling of these patients. Mr. Wm. H. French in illustrating this book has matched his artistic ability with his devotion to the task, while Miss Marguerite Stadelhofer in an editorial capacity has relieved me of many incidental details, including the compilation of the index.

WILLARD BARTLETT.

St. Louis.

# CONTENTS


CHAPTER I

PAGE

HISTORICAL AND PERSONAL - - - - - - - - - - - - - - - - - - 21
Mortality, 23; Sepsis, 25; Thyropriva, 26; Tetany, 26; Laryngeal Paralysis, 27; Skin Incision, 28; Present Era of Thyroid Surgery, 28.

CHAPTER II

PATHOLOGY. BY LOUIS B. WILSON, M.D., ROCHESTER, MINNESOTA - - - - 32
Inflammations, 33; Exophthalmic Goiter, 35; Endemic Goiter, 38; Malignant Tumors, 44.

CHAPTER III

THE HEART IN GOITER. BY SAMUEL B. GRANT, M.D., ST. LOUIS - - - - - 49
Introduction, 49; The Cause of Cardiac Symptoms in Goiter, 49; Morbid Anatomy, 51; Symptoms, 51; Physical Signs, 53; Electrocardiography, 55; Prognosis, 57; Treatment, 59.

CHAPTER IV

UNUSUAL MANIFESTATIONS OF GOITER - - - - - - - - - - - - - - 64

CHAPTER V

INDICATIONS IN GENERAL FOR THE SURGICAL TREATMENT OF GOITER - - - - 74

CHAPTER VI

CONSIDERATION OF THE PATIENT WHO NEEDS TWO OPERATIONS, ONE OF THEM BEING A THYROIDECTOMY - - - - - - - - - - - - - - - - 85
Adenoma Thyroid—Prolapse of Uterus, 86; Adenoma Thyroid (Toxic)—Tuboovarian Abscess, 87; Adenoma Thyroid (Toxic)—Myoma Uteri, 87; Adenoma Thyroid (Toxic)—Hydrosalpinx, 88; Colloid Goiter—Prolapse of Uterus, 89; Adenoma Thyroid (Toxic)—Prolapse of Uterus, 89; Exophthalmic Goiter—Gallstone Disease, 90; Adenoma Thyroid—Postoperative Hernia, 90; Adenoma Thyroid—Gallstone Disease and Appendicitis, 91; Adenoma Thyroid (Toxic)—Appendicitis and Chronic Metritis, 91; Exophthalmic Goiter—Gallstone Disease, 92; Conclusions, 93.

CHAPTER VII

PREPARATION OF THE PATIENT FOR THYROIDECTOMY - - - - - - - - - 95
Rest in Bed, 97; Diet, 102; Circulation, 105; Specific (Exophthalmic), 105; Operative (Exophthalmic), 111.

CHAPTER VIII

PAGE

LIGATION - - - - - - - - - - - - - - - - - - - - - - - - - - - - 122

On Which Patients Shall Ligation Be Done? 122; Anesthesia, 126; Technic, 128; After-Treatment, 138; Complications, 139; Benefit to Patient, 140; Interval between Ligation and Thyroidectomy, 142.

CHAPTER IX

POSITION ON TABLE AND DRAPING OF PATIENT - - - - - - - - - - - - 146

CHAPTER X

ANESTHESIA - - - - - - - - - - - - - - - - - - - - - - - - - - - 152

Preliminary Sedatives, 152; General Anesthesia, 158; Infiltration, 160.

CHAPTER XI

DETAILS OF TECHNIC - - - - - - - - - - - - - - - - - - - - - - - 169

Skin Incision, 169; Accuracy in Marking Line of Incision, 172.

CHAPTER XII

DETAILS OF TECHNIC—CONTINUED - - - - - - - - - - - - - - - - - - 176

The Division of the Platysma Muscles, 176; The Ribbon Muscles, 178; The Upper Pole, 181; Display of the Goiter, 184.

CHAPTER XIII

DETAILS OF TECHNIC—CONTINUED - - - - - - - - - - - - - - - - - - 191

The Actual Resection, 191; With Tourniquet, 191; Without Tourniquet, 203; Clamps Left in Place, 208.

CHAPTER XIV

DETAILS OF TECHNIC—CONTINUED - - - - - - - - - - - - - - - - - - 212

Packing and Draining, 212; Method of Introducing Rubber Tube, 215; Gauze, 216; Pack of Rubber Dam, 218; Closure and Dressing, 222; Primary Closure, 222; Partial Primary Closure, 226; Secondary Wound Closure, 229; Dressing, 232.

CHAPTER XV

THE FOUR TYPES OF THYROIDECTOMY—INDICATIONS FOR EACH - - - - - - 234

Analysis of Various Types of Procedure, 235; Ideal Bilateral Resection (Closed), 236; Cross-Cutting Bilateral Resection (Drained), 236; Unilateral Resection (Open), 246.

CHAPTER XVI

SIMPLIFIED UNILATERAL RESECTION TECHNIC - - - - - - - - - - - - 265

## CHAPTER XVII

PAGE

COMPLICATIONS - - - - - - - - - - - - - - - - - - - - - - - - 277

Acute Anemia from Hemorrhage on Table, 277; Surgical Rotation of the Trachea, 278; Collapse of the Trachea, 278; Shock, 279; Postoperative Hemorrhage, 280; Postoperative Hyperthyroidism, 280; Difficulty of Swallowing, 281; Edema and Paralysis of the Larynx, 282; Retention Fever, 282; Tetany, 283; Pulmonary Complications, 285; Pulmonary Embolism, 286; Hematoma, 286; Infection, 287; Referred Pain, 288; Complicating Acute Surgical Lesion, 288; Foreign Body in Wound, 289; Central Nervous System, 290; Intracardiac Thrombosis and Embolism, 290; Hypothyroidism and Myxedema, 292; Adhesions to Trachea, 296; Disfiguring Scar, 296; Malignancy, 299; Remote Cardiac Failure, 300; The Nursing Mother, 301.

## CHAPTER XVIII

LARYNGEAL COMPLICATIONS. BY FRENCH K. HANSEL, M.D., ST. LOUIS - - 302

Anatomy, 302; Disturbance of Laryngeal Function, 307; Technic of Thyroidectomy in Relation to Recurrent Laryngeal Nerve, 312; Disturbance of Function after Operation, 313; Classification of Cases of Paralysis, 317; Treatment, 321.

## CHAPTER XIX

AFTER-TREATMENT - - - - - - - - - - - - - - - - - - - - - - 324

Sedatives, 324; Fluids, 326; The Wound, 328; Respiratory System, 332; Cardiac Disturbances, 333; Digestive Disturbances, 334; Deprivation, 336; Miscellaneous, 337; Hygiene, 339.

## CHAPTER XX

RECURRENCE - - - - - - - - - - - - - - - - - - - - - - - - - 344

Operative Considerations in Recurrence, 349.

## CHAPTER XXI

THE IDEAL GOITER CLINIC - - - - 356

# ILLUSTRATIONS


| FIG. | | PAGE |
|---|---|---|
| 1. | Fibrous thyroiditis (Riedel's disease) | 34 |
| 2. | Exophthalmic goiter | 37 |
| 3. | "Simple" endemic goiter with "Adenomatosis" | 41 |
| 4. | Adenomatous endemic goiter | 43 |
| 5. | Malignant adenoma | 45 |
| 6. | Adenomedullary carcinoma | 46 |
| 7. | Spindle cell sarcoma | 47 |
| 8. | Exophthalmic goiter; high columnar epithelium, papillary projections, and very little colloid. Before iodine therapy | 106 |
| 9. | Same gland as in Fig. 8, but after iodine therapy for six weeks | 107 |
| 10. | Marking the line of incision for ligation. Vertical ink line or scratch marking the point where the superior thyroid vessels can be seen or felt | 129 |
| 11. | Marking the line of incision for ligation. A line marking the midline of the neck, and another marking the anterior border of the sternomastoid muscle | 130 |
| 12. | Ideal location for the line of incision for ligation | 131 |
| 13. | The skin and deeper structures infiltrated through a single opening at the outer extremity of the intended skin line for ligation | 132 |
| 14. | The skin incision for ligation | 133 |
| 15. | The skin is retracted and the platysma muscle, together with the cervical fascia, is divided (ligation) | 133 |
| 16. | The ribbon muscle layer is split longitudinally (ligation) | 134 |
| 17. | The retractor is inserted with the intention of reversing the direction of the wound when its walls are stretched (ligation) | 134 |
| 18. | The upper pole is exposed by the retraction and the group of structures entering it are grasped en masse in a clamp (ligation) | 135 |
| 19. | Bundle, consisting of artery, veins, nerves, and lymphatics, with catgut threaded needle carried around it (ligation) | 135 |
| 20. | The ligature in its relation to important surrounding structures (ligation) | 136 |
| 21. | The ribbon muscle slit has been closed by sutures (ligation) | 136 |
| 22. | Two or three sutures reunite the lips of the platysma muscle wound (ligation) | 137 |
| 23. | About three clamps closing the tiny skin wound completely (ligation) | 137 |
| 24. | Patient on table. Table inclined, elevating the head to a degree which suits the operator's convenience | 147 |
| 25. | Sand pillow at base of neck between patient's shoulders—seen from above | 147 |
| 26. | Sand pillow seen from side and above | 148 |
| 27. | Long twisted gauze strand crosses upper neck, ends being packed below field of operation. Covering sheets in position | 148 |
| 28. | Wire arch over patient's face | 149 |
| 29. | Final sterile towels in place | 149 |
| 30. | Split sheet in place so that nothing but the site of incision is exposed | 150 |

FIG. PAGE
31. Patient's face as viewed by anesthetist behind the shield – – – – – 150
32. Ethylene spray on skin protected by nail head; this protected spot remains soft in the center of an anesthetized area – – – – – – – – – – 162
33. Infiltration needle inserted at one end of marked incision line through soft anesthetized area – – – – – – – – – – – – – – – – – – 162
34. Ideal operation. Infiltration needle inserted in the different directions required to produce sufficiently extensive anesthesia for skin incision and elevation of skin flaps – – – – – – – – – – – – – – – – 163
35. Region of the upper pole is tightly infiltrated as are other portions of the lobe not shown in drawing – – – – – – – – – – – – – – – 164
36. Ideal operation. Marking the intended collar incision site over a chain of beads – – – – – – – – – – – – – – – – – – – – 171
37. Ideal operation. A pair of calipers determine the length of the intended midribbon muscle split – – – – – – – – – – – – – – – 173
38. Ideal operation. The distance determined in Fig. 37 is laid off on the collar skin mark, thus determining its length – – – – – – – 173
39. Ideal operation. Showing correct and incorrect angle of knife in making skin incision – – – – – – – – – – – – – – – – – – 174
40. Ideal operation. The collar skin incision partly through the fat – – – 175
41. Ideal operation. Undermining the skin flaps – – – – – – – – – 177
42. Ideal operation. Elevating the skin flaps with fat attached from the platysma muscles, using automatic spreaders or the single automatic spreader – – – – – – – – – – – – – – – – – – – – 178
43. Ideal operation. Making the midribbon muscle split to expose the thyroid 179
44. The curved elevator – – – – – – – – – – – – – – – – – – – 183
45. Straight elevator which is used in pinching out the upper pole when opposed to the curved elevator – – – – – – – – – – – – – – 183
46. The fine-toothed tenaculum forceps which is employed for grasping and lifting the goiter – – – – – – – – – – – – – – – – – 185
47. A strong, fairly heavy type of toothed forceps which will not cut through friable goiter tissue when tightly grasped because the blades are so greatly bent – – – – – – – – – – – – – – – – – – 185
48. Ideal operation. Shows infiltration of thyroid tissue around upper pole, division of it, goiter displayed, and the actual resection commenced – 187
49. Shows in diagrammatic cross-section of the neck how a straight elevator is thrust from the side underneath a thyroid lobe – – – – – – – 188
50. A straight crowbar is in actual use as shown diagrammatically in Fig. 49 189
51. Cross-section of the neck showing approximately where the so-called holding clamps are placed on the stump and their relationship to the intended resection line – – – – – – – – – – – – – – – – 194
52. The rubber ligature lies loosely around the pedicle behind the four holding clamps which are intended to prevent it from slipping forward – – 195
53. The rubber ligature has been tightened, caught with two clamps and the resection in front of it has been started – – – – – – – – – 196
54. Details of the holding clamps, the rubber ligature and the pedicle in relation to each other – – – – – – – – – – – – – – – – – 197
55. Same as Fig. 54 – – – – – – – – – – – – – – – – – – – – 197
56. Shows line of resection in its relation to the rubber ligature and the holding clamps – – – – – – – – – – – – – – – – – – 198

FIG. PAGE

57. One or two vessels are often caught separately in the parenchyma of the stump 198
58. One deeply placed purse-string ligation suture approximates an inner zone of divided thyroid tissue 199
59. A second ligation suture in the form of a purse-string inserted at the edge of the stump when tied institutes compression sufficient for complete hemostasis 199
60. Shows the stump in relation to surrounding structures while the rubber constrictor is in place and the compression sutures are being inserted 200
61. Illustrates a method of marking the proposed resection plane after the upper pole has been divided and the lobe completely delivered 204
62. Shows the appearance of the operative field after one lobe has been resected and a few parenchymatous vessels caught 205
63. Ideal operation. The right lobe resected by cutting across its base and catching blood vessels as encountered 207
64. Section of a discarded rubber glove about two-thirds normal size, a material employed for a rubber pack 218
65. Each defect resulting from the removal of a lobe stuffed full of rubber and the packs crossed in the midline and each brought out at an angle of the skin incision 219
66. The midribbon muscle split sutured up to the point where the packs emerge 219
67. The skin closed except for the small openings at either end to accommodate the drains 220
68. One rubber pack inserted after removal of one lobe 220
69. The single strip of rubber carried across from the midline muscle defect to one angle of the wound, from which it emerges 221
70. The skin wound closed with metal clips 221
71. The completed primary suture of the skin wound as contemplated in the technic of ideal thyroidectomy 223
72. Introducing a subcutaneous silkworm suture which is left loose so that all wound edges remain apart, displaying the rubber pack when dressings are applied 225
73. The skin edges being satisfactorily coapted when the subcutaneous suture is approximated at the end of twenty-four hours 225
74. The one skin clip approximating the middle of the two wound lips 226
75. Dressing. A strip of gauze covers the suture wound, while a large sterile cotton gauze-covered pad is seen behind the patient's neck 227
76. Dressing. A gauze-wrapped cotton pad behind the neck, a second in front, and a strip of bandage around the upper chest 228
77. Actual photograph of the dressing material in position as outlined in Fig. 76 229
78. Diagram of packs from Figs. 75 and 76 230
79. Photograph of the patient on whom the packs have been pinned together and the lower edge of the one in front pinned to a binder which encircles the patient's upper chest 231
80. A large square of adhesive plaster split at its lower edge and applied from the chin to the chest wall in such a manner as to protect the dressing from being soiled by vomitus 232

FIG. PAGE

81. The site of the intended skin incision and the site of the intended transverse platysma and ribbon muscle incision – – – – – – – – – 237
82. The knife is seen elevating the skin flap just long enough to permit of the transverse muscle incision – – – – – – – – – – – – – – 238
83. Cross-cutting bilateral resection. The platysma is being cross-divided while the upper skin flap is retracted – – – – – – – – – – 239
84. Cross-cutting bilateral resection. The platysma wound is seen wide open and the ribbon muscles are being cross-divided over a clamp which has been thrust beneath them – – – – – – – – – – – – – – 240
85. Author's automatic spreader for retracting lips of goiter wound – – – 241
86. The automatic spreader holds the upper and lower skin fat muscle flaps wide apart – – – – – – – – – – – – – – – – – – 242
87. The goiter out, the ribbon muscles closed over a guttered cross rubber drain tube, and the first suture inserted in the platysma fascial layer 243
88. Correct position of head for closure of the wound – – – – – – – – 244
89. Skin closure begun – – – – – – – – – – – – – – – – – – 244
90. Large multiple adenocystoma of thyroid illustrating well the type which is thought to indicate the technic illustrated in Figs. 81 to 89 – – – 245
91. Lateral view of same patient shown in Fig. 90 – – – – – – – – – 245
92. Front view of patient two months after operation – – – – – – – – 245
93. Lateral view of same patient after operation – – – – – – – – – 245
94. Unilateral resection. Diagram of skin bridge intended to separate the halves of a collar incision through which two resections are to be done at separate sittings – – – – – – – – – – – – – – – – 250
95. Photograph of patient illustrating plan shown in Fig. 94 – – – – – 250
96. Diagram illustrating direction of infiltration needle as well as size and location of skin and subcutaneous area to be anesthetized – – – – 251
97. The skin incision for unilateral resection – – – – – – – – – – 252
98. Method of dissecting the skin flaps – – – – – – – – – – – – 252
99. The author's automatic retractor, so employed as to transform the direction of the half-collar skin opening into one which follows the direction of the sternomastoid muscle – – – – – – – – – – 253
100. Skin flaps shown mobilized and stretched to the extent that the original half-collar opening is displaced along the course of the sternomastoid muscle – – – – – – – – – – – – – – – – – – 253
101. The sternomastoid muscle peeled off the deeper layers and retracted backward – – – – – – – – – – – – – – – – – – 254
102. Superficial layer of ribbon muscles being split longitudinally while the lower sternomastoid is retracted backward and the opposite upper platysma is retracted inward – – – – – – – – – – – – 254
103. Deep layer of ribbon muscle split longitudinally while retraction is maintained as in Fig. 102 – – – – – – – – – – – – – – 255
104. The upper pole is completely divided and drawn toward the ceiling – – 255
105. Packing with rubber dam the cavity from which the lobe has been removed 257
106. Bringing the edges of muscle and skin wounds partly together over rubber pack – – – – – – – – – – – – – – – – 257
107. Simplified unilateral resection. Line indicating the approximate location of the skin incision and its relationship to the anterior border of the sternomastoid muscle – – – – – – – – – – 267

FIG. PAGE
108. Two lines indicating approximately the relationship of the two incisions and resulting skin scars – – – – – – – – – – – – – – – – 268
109. Intended muscle incision line and its relationship to the external jugular vein, spinal accessory nerve, and other important structures in the vicinity – – – – – – – – – – – – – – – – – – – – – 268
110. Shows how the plane of incision through the skin and deeper structures is infiltrated through a single opening – – – – – – – – – – – 269
111. The skin and fat incision in simplified unilateral resection – – – – – 269
112. The sternomastoid muscle is retracted backward, together with the overlying structures, while the divided platysma and cervical fascia are drawn toward the midline – – – – – – – – – – – – – – – 270
113. The ribbon muscles incised diagonally – – – – – – – – – – – – 271
114. Clamps left in place on the superior thyroid and stump – – – – – 274
115. The clamps are wrapped with dressings – – – – – – – – – – – 274
116. Muscles of the larynx – – – – – – – – – – – – – – – – – 303
117. Muscles of the larynx – – – – – – – – – – – – – – – – – 304
118. Action of the muscles of the larynx – – – – – – – – – – – – 305
119. Dissection of the nerves of the larynx – – – – – – – – – – – 306
120. The typical image of complete left recurrent paralysis – – – – – – 310
121. The typical image of unilateral abductor paralysis – – – – – – – 310
122. Dissection of neck, showing the intimate relation of the recurrent laryngeal nerve to the inferior thyroid artery – – – – – – – – – 313
123. A variation from the typical image of recurrent paralysis – – – – – 315
124. Recent left recurrent paralysis during respiration – – – – – – – 315
125. Recent left recurrent paralysis. Phonation – – – – – – – – – 316
126. Left recurrent paralysis. Compensatory movement of right cord across midline – – – – – – – – – – – – – – – – – – – – 317
127. Left abductor paralysis during respiration – – – – – – – – 318
128. Double abductor paralysis – – – – – – – – – – – – – – – 319
129. Double recurrent paralysis. Cords midway between cadaveric and midline position – – – – – – – – – – – – – – – – – – – – 320
130. Removal of a postoperative collection of blood serum – – – – – – 330

## FOREWORD

Truth, which seems finite, is but relative, varying with the state of knowledge. Lack of knowledge is like a blindness or confusion of ideas which may be relieved by glasses or enlightenment. New facts do not destroy but advance or change the boundaries of appreciated truth.

Within the last twenty-five years all science has made great progress, new discoveries in one branch becoming tools for many eager and appreciative workers in other branches.

General knowledge of disease and its treatment has developed slowly, but within the last twenty-five years more progress has been made in scientific medicine than during any similar period in as many centuries. Within this period our growing knowledge of the glands of the body, both duct and ductless, has especially given new viewpoints on cell growth and function and advanced the boundaries of medicine. The thyroid has been one of the most interesting of all the glands studied. Within the last two decades the definite relationship of pathology of the thyroid to the clinical symptoms of disease of the gland has been shown. The active principle of the thyroid has been isolated and its physiologic activities determined. The metabolic rate of patients with and without goiter has come to be measured with accuracy. The relationships of metabolic rate to normal and abnormal rates, to hyperfunction and dysfunction of the thyroid are now interpretable, and our knowledge of these relationships in turn are of great aid in making diagnoses of diseases and in selecting proper methods of treatment. It has been shown that thyroxin, the active principle of the thyroid, is apparently a catalyst that accelerates the formation of bodily energy in the cells of the organism and that iodine apparently neutralizes the toxic effects of altered thyroxin in exophthalmic goiter. These facts and contingent hypotheses in regard to the function and dysfunction of the thyroid are most interesting subjects of discussion because they deal intimately with the mysteries of life concerned with health and disease. The knowledge derived

from the study of the thyroid during the past two decades has given us greatly added power for the relief of human suffering which is the art of medicine.

Certainly the time has again arrived for assembling the many new truths concerning the thyroid and for showing their clinical applications. This has been well done by the author. His formulae for their application in diagnosis and treatment have been carefully thought out. His classification system is practical and has been developed from an extensive experience in the field of goiter and from a study of the methods practiced in other clinics, from which he has selected special measures, and all of which he has arranged to meet the requirements of the general surgeon in search of the new for practical application with the best of the old.

Charles H. Mayo, M.D.

# THE SURGICAL TREATMENT OF GOITER

## CHAPTER I

## HISTORICAL AND PERSONAL

My interest in this subject began when, as a child, I was afforded almost daily opportunity of contemplating with curiosity and aversion an enormous tumor which hung down upon the chest of an elderly lady, who had migrated from a German goiter district to our home town in the middle west, where she was a unique object of popular attention. From that day to this an overfull neck has always attracted my notice, especially so during the years, when as a medical student abroad, I spent protracted vacations among the mountains and on the high plateaus of Central Europe, the hotbed of endemic goiter.

The **historical** side of the subject began to appeal to me in the summer of 1916 when I was a guest of Professor Wm. S. Halsted on his estate in the country, which the North Carolina mountaineer loves to call "the land of the sky," not far from Lake Toxaway in the very heart of the sapphire country. It so happened that it was I who brought the first tidings of Kocher's death a year later to Halsted's secluded mountain retreat, about twenty miles from the Toxaway terminus of an obscure branch railway line, at a time when, as the irony of fate would have it, I found him engaged in working on Chapter 3 of his "Operative Story of Goiter" in which he accords the immortal Swiss master the leading rôle in the development of thyroid surgery. Small wonder that the historical phase of this subject should have appealed to one intimately associated with him at that time, since to Dr. Halsted, more than to any other student of medical history, we owe our familiarity with the remote past of goiter surgery. This chapter of my own, for example, could never have been written in its present form without the historical data which were taken from his "Operative Story of Goiter," since much of the literature abstracted therein is not available to one less fortunately situated than he; my deep obligation is hereby acknowledged.

We have every reason to believe that goiter is as old as the human race, and when of appreciable size, it probably never escaped notice. The reason of wild men and the instinct of wild beasts have, since the world began, told them how vulnerable the neck is. Little wonder then that a goiter, fastened like a giant parasite on this vulnerable vital region, should have attracted more attention than other lesions less strikingly situated. Victims of the malady must have suffered and died from it all down through the ages until its surgical relief was instituted about one thousand years ago.

According to Mandt, the Arabian surgeon, Albucasis was probably the first to attempt the removal of a goiter at Bagdad A.D. 939, although he seems to have known of hemorrhage from some *earlier* operative attack on one. With the exception of this somewhat doubtful procedure so long ago, the first one hundred six authentic operations ranged from 1596 to 1861, far the greater number must have been performed before the introduction of ether in 1846. Of this number forty-one had been collected by Gunther in 1864, to which Halsted added sixty-five more. A few of these one hundred six were lobectomies, the most, however, being ligations, enucleations, or partial resections. Germany furnished thirty-nine; France, twenty-five; England, fifteen; Italy, thirteen; United States, eight; Switzerland, four; Russia, one; uncertain, one.

Two names stand out prominently in France and Germany among the pioneers who blazed the way to success in what must have been a bloody field. One was Desault, who in 1791 was the first to dissect an adherent thyroid from the trachea. Halsted feels that no surgeon, excepting a few Germans, improved upon his operations prior to 1883. Halsted considers the other outstanding figure in goiter surgery up to Kocher's time J. A. W. Hodenus, of Dresden, who in 1821 published an account of the removal, without a death, of six thyroids that were almost completely suffocating their victims.

No one of us living today ever saw major surgery done without an anesthetic of some sort, still, the ancient history of the subject furnishes so many such dramatic episodes, that one can visualize the impetus given to operating by the introduction of anesthesia merely by noting that four hundred

eighty-nine major goiter attacks were made between 1861 and 1883, although only one hundred six had taken place in more than two and one-half centuries antedating this period. Of course, this is only one of the factors which can be given credit for the great increase in the number of such operations between 1861 and 1883, as well as for the improvement in mortality rates during this period, the end of which marked the complete development of a standardized technic chiefly in the hands of German surgeons. Indeed it was in the latter half of this era that the most notable contribution ever made to surgical science was afforded by Lord Lister, who built upon the well-known studies of Pasteur. Halsted reminds us that the surgeons of the German speaking countries adopted "Listerism" in 1876, the Italians in 1878 and 1879, the French and British in 1880, and the Americans quite generally about 1890.

In 1883, three hundred ninety-five thyroid operations of major character had been done in Germany, Austria and Switzerland against fifty-three in France, fifty-three in Italy, forty-nine in Great Britain and forty-five in our own country. In order to understand how this branch of surgery gradually evolved up to the high plane it occupied in 1883, one had best scrutinize the reports of the German speaking surgeons who wrote during that era, taking special thought of mortality with its chief contributing factors of sepsis and hemorrhage, thyroid deficiency after operation, destruction of the parathyroids, and injuries to the recurrent nerves.

## Mortality

Just as in every other field of surgical endeavor, so here, a discussion of immediate mortality must take precedence over every other consideration—such as postoperative complications, end-results, etc.—relatively important as they become, once the leading issue is out of the way.

There was little enough to encourage the pioneers whose experience paved the way for the brilliant results of today. The stout-hearted Billroth found a mortality of 40 per cent in his first twenty major thyroid operations done by 1869, and one only slightly lower, viz., 36 per cent in all the thirty-six which he performed in pre-antiseptic times. Then, just before this

era dawned for Germany, Bruberger collected from the literature the reports of eighty-two such procedures, as a result of which 34 per cent of the patients had lost their lives. In the same year (1876) Victor von Bruns, though more fortunate than Billroth, had to admit that he had seen 21 per cent of his twenty-eight patients die. According to Halsted, the operative mortality up to 1883 was 28 per cent in France (with fifty-three operations), 13 per cent in Italy (with fifty-three operations), but only 11 per cent in the United States (with forty-five operations), most of this work having been done previous to the antiseptic regime. Witness, now, the triumph of "Listerism" when Billroth reports in 1882 his second group of forty-eight operations with a mortality of only 8.3 per cent as contrasted with that of 36 per cent for the previous era.

With Kocher's advent at Berne the "golden age" in goiter work began, though his first one hundred one operations, between 1872 and 1883, have no bearing on a mortality study because antisepsis was introduced about the middle of the period. But marvelous progress is apparent in his next series of two hundred fifty cases, between 1883 and 1889, in which we witness the drop to a hitherto undreamed of figure of 2.4 per cent operative fatalities. This figure was, however, still further reduced to about 1 per cent in his first thousand operations performed on nontoxic patients up to 1895 (leaving out of consideration the original hundred in which sepsis played a rôle). After 1896 all of his work was done under local anesthesia. By 1917 five thousand thyroidectomies had been performed in his clinic; then the master laid the scalpel aside after he had known the satisfaction of reducing the mortality to one-third of one per cent in his last thousand nontoxic patients.

Now, six years later, all the well-known goiter clinics show a mortality far under 1 per cent; any other record would constitute an indictment on three possible counts, (a) unwise choice of patients, (b) faulty technic (hemostasis, anesthesia), (c) postoperative neglect. Still, all things are relative, hence, I beg you to glance back once more over the statistics of a little more than half a century which read 1 per cent, 2.4 per cent, 8.3 per cent, 11 per cent, 13 per cent, 21 per cent, 28 per cent,

34 per cent, 36 per cent, and even 40 per cent, as a manner of visualizing the development of goiter surgery.

The more one studies the history of this subject, the more he will be impressed, as was Halsted, with the fact that hemorrhage and sepsis were chiefly responsible for the almost prohibitive mortality in pioneer days. Hemorrhage caused death in but one of Billroth's eight fatal cases, but he was probably the most accomplished operator of that time (the sixties); von Bruns lost, in this manner, but one of his first six fatal cases (this a secondary bleeding due to sepsis, no doubt). However, seven of the first fifteen lost in France, and but one of the first five in the United States succumbed to loss of blood (Halsted).

The farther back one goes into the past, the more he is impressed with the grave danger of invading a highly vascular field at a time when styptics, heat, pressure and mass constriction were largely depended upon to control bleeding; when the last word in hemostatic refinement was the passing of two ligatures on some sort of pedicle needle as a hook, then cutting between them. Apparently the modern practice of keeping the field dry by leaving dozens, scores and even hundreds (Johns Hopkins breast amputation) of clamps hanging in it originated with the introduction in 1879 of the Halsted forceps of its present length. Nowhere is this consideration more important than in goiter surgery, to which our brilliant countryman was destined to make so many other important later contributions.

In writing of hemostasis I am reminded again of my father's amputating outfit, dating from Civil War days, equipped with its many formidable knives—one or two of unbelievable length—and the two puny toy hemostatic forceps, all of them the outgrowth of the destructive phase in the surgery of that day, which unfortunately greatly outweighed the constructive until recent times.

## Sepsis

Infection accounted for seven out of Billroth's eight fatalities and for five out of the six which von Bruns experienced. The same is true up to 1883 of three out of the fifteen deaths in France, for four out of the seven in Italy and for one out of the five in the United States. The same magical improvement

which took place in surgical results, no matter what the part of the body involved, was also seen in goiter work about this same time, viz., 1880. The tale has been told so often and in terms so much more dramatic than any at my disposal, that I should merely be burdening my reader by further repetition of it.

## Thyropriva

Having disposed of the question of *death* from operation, we come to thyropriva, one of the three minor pitfalls along the path of progress in thyroid surgery; the others are tetany and laryngeal paralysis. Kocher found a postoperative deficiency in 16 of 18 patients he reexamined in whom total removal had been made and, as Halsted remarks, made as great a contribution to physiology as to surgery when he explained the condition, though Reverdin had described myxedema one year earlier, in 1882. From this time on Kocher practically never removed but one-half the thyroid, preferring to play safe in this particular. The later cost to the patient of this conservation was, however, impressed upon me years ago when I removed the second lobe of the thyroid in a patient who had first been operated upon by the master. No doubt everyone else doing this type of work has had similar experience at one time or another.

## Tetany

Billroth saw what was, no doubt, parathyroid tetany, as we now recognize it, in 8 of his patients previous to 1883. At that time the manifestations of tetany were blamed on the nervous system as such, it being considered that a primary, instead of a secondary disturbance of it was to blame. It was not until the discovery of the parathyroid glands in the early nineties that a rational explanation was given for symptoms which had first been noted some twenty years earlier. Many have commented on the fact that these distinguished pioneers, Kocher and Billroth, should have had diametrically opposite experiences in that Kocher never saw tetany and Billroth never observed postoperative thyroid deficiency. Many explanations have been furnished by those interested in the riddle, though none of them appeal to me as wholly solving it.

Cushing* has the following to say of the significance of the thyroid tumor upon the clinical studies which developed our fundamental knowledge of thyroid and parathyroid physiology.

"Were it not for the tumor, indeed, clearly indicating the seat of trouble, how little would we now know of the thyroid, for it is only of late years with some knowledge of basal metabolism that we have ventured in its absence to speak, at least with any assurance, of hyperthyroidism. Certainly without the combination of tumor and modern principles of surgery we might still be groping in the wilderness over thyroid insufficiency. But certain goiters pressed on the windpipe and demanded removal. Kocher and Reverdin found the way to do so and the cause of myxedema was disclosed, and then of cretinism and finally of tetany. In the bare statement, this seems simple enough today, but even the technical difficulties of these early thyroidectomies were such that only the boldest operators, whose exciting adventures Professor Halsted has so vividly described, dared to undertake them. Still, formidable as these surgical difficulties appeared to be, they were as nothing when compared with the subsequent intellectual tasks, that were necessary for an interpretation of the results."

## Laryngeal Paralysis

Billroth injured the recurrent nerves thirty-one times in eighty-four patients. Since his time no operator of wide experience has been wholly without some such experience, although fortunately it is becoming more and more rare. There probably never will be a time when we can positively guarantee patients against secondary damage to these nerves, although the resection method of Mikulicz, almost universally followed, has done more than any other one development in this field of surgery to protect them, as well as the parathyroids, and guarantee the proportion of residual thyroid tissue, which should in all likelihood insure against postoperative deficiency, while at the same time a well-balanced operation is done by the removal of a greater portion of *both* lobes.

*Cushing, Harvey: Disorders of the Pituitary Gland, Jour. Am. Med. Assn., June 18, 1921, lxxvi, No. 25, p. 1721.

### Skin Incision

It is not without interest in this connection to mention that every conceivable skin incision has been employed in the removal of the thyroid. All but one of them seem to have been made without regard for the cosmetic idea. In 1880 Boeckel devised the low collar incision for which Kocher seems to have been accorded almost universal credit, although a perusal of the master's writings will show that he did not accept it for universal employment until fifteen years later.

Halsted's admirable "Operative Story of Goiter," ends with the development of the subject up to this era. My obligation for the foregoing historical data has been duly acknowledged.

### Present Era of Thyroid Surgery

The development of thyroid work during the forty years which have intervened since 1883, in connection with which Kocher has been mentioned more than once, owes very much to the contributions of three Americans, W. S. Halsted, C. H. Mayo, and George Crile. Frequent mention has been made of Halsted's historical work. He also planned a most refined operative procedure, which is beautifully illustrated by Broedel, in his "Operative Story of Goiter." He established the truth of "Halsted's Law," according to which, the transplant of an endocrine gland will live only if a physiologic need for it is created. His contribution to hemostasis has already been commented upon. It will further not be forgotten that his pioneer research work with local anesthesia did more than that of any other individual to give it its prominence in surgery today. Hence it goes without saying that he in this way did much to rob thyroid operations of their danger, especially those of a respiratory nature. C. H. Mayo, who has operated on far more goiters than any other surgeon, did, to his undying fame, for this work in America what Kocher had done abroad, but early supplemented the former's unilateral with a bilateral procedure as routine. He was probably the first in this country to fully recognize the value of carrying out the step-by-step operation

in toxic goiters, at least in so far as this means preliminary ligation in exophthalmic cases. He was the first also to call attention to the fact that preliminary ligation avails nothing, but probably does harm in the treatment of a toxic adenoma. Great as have been Dr. Mayo's own personal contributions to goiter surgery, be it remembered further that in the laboratories at his goiter clinic Kendall isolated the active principle *thyroxin* and at a later period discovered the paucity of iodine in hyperplasia thus enabling Plummer to influence the metabolic rate in exophthalmic goiter for the first time with a specific drug.

(It was interesting to note in this connection, as Halsted states, that Sir William Blizzard was the first [1811] to ligate a thyroid artery in an attempt to cure a goiter, though death resulted. It had been proposed in 1707 by Lange and first done successfully by von Walther some years after Blizzard.)

George W. Crile, with the physiologist's viewpoint, added the last word in safety to toxic goiter operations when he suggested doing them amid surroundings presenting no disturbing element, with a combined anesthesia which has all the value of local and the advantages of general, but none of its dangers. By advocating as a routine the leaving open of such wounds with secondary closure, he protects against postoperative explosions, and in this way, too, minimizes the immediate risk. His many other contributions to the surgery of the thyroid have had a widespread influence in decreasing mortality and minimizing morbidity.

I cannot in a chapter of this length do more than mention the contributions of those who laid down the cardinal principles of thyroid surgery. If I were to give due credit to every man who aided in the development of the subject, I should come near to calling the honor roll of the glorious names whose possessors made surgical history during the last quarter of the eighteenth and the first three quarters of the nineteenth century.

In reviewing the developments of this subject, one is struck by the fact that four factors in the chronologic order of their introduction are to have the major share of the credit for the high degree of perfection to which this branch of surgical therapeutics has developed. They are (1) general anesthesia,

(2) antisepsis and later asepsis, (3) modern hemostasis, and (4) local anesthesia. The last of these four major additions to the subject was made during the years of my student life abroad, from 1895 to 1898. In Berlin and Strassburg in the busy clinics of W. Bergman, Koenig and Madelung, I cannot remember a thyroid operation, showing that they were not very frequent even in all the large German clinics at that time. I shall never cease to regret that I failed to see the mighty Kocher, though twice I visited Berne, both times unfortunately in the vacation season. He was always Halsted's ideal student of this subject, as well as his close personal friend; they are said by Cushing to have been much alike in many ways. If, then, this be so, one may have obtained something from both their lives through being privileged to sit at the feet of one of them.

The typical standardized thyroidectomy of today is a composite of many contributions. This will not be disputed, I suppose, in as far as the nontoxic thyroid is concerned. We are all pretty well agreed upon the Boeckel collar incision, the Kocher midribbon muscle split and gland exposure, Halsted's treatment of the upper pole and the hemostasis in general, the Mikulicz resection of the lobe leaving a relatively small mass of thyroid tissue clinging to the trachea, and the Mayo insistence on the operation being a bilateral one with a symmetrical neck in consequence. Others have made minor contributions of undoubted value which we all employ at times, but I am sure we are all a unit in feeling that the operation would not be complete in its present form if we left out any one or more of the five essentials which have just been mentioned.

Before Halsted laid aside for all time the pen that had indited so many of the surgical thoughts which have proved best, he epitomized his ripe knowledge of this subject in the following words:

"The extirpation of the thyroid gland for goiter typifies, perhaps better than any operation, the supreme triumph of the surgeon's art. A feat which today can be accomplished by any really competent operator without danger of mishap and which was conceived more than one thousand years ago might appear an unlikely competitor for a place in surgery so exalted.

"There are operations today more delicate and, perhaps, more difficult, but they have followed naturally and easily in the paths made clear for them. But is there any operative problem propounded so long ago and attacked by so many which has cost so much thought and endeavor and so many lives before its ultimate solution was achieved? And further, is there any problem in surgery having required for its solution such intrepid throbbing and prolonged striving of the world's greatest surgeons which has yielded results so bountiful and so adequate?"

# CHAPTER II

## PATHOLOGY

Louis B. Wilson, M.D., Rochester, Minnesota

From the standpoint of the surgical treatment of goiter the principal interest in the pathology of the thyroid centers around those conditions which warrant its partial destruction or removal. Early in the history of thyroid surgery the gland was partially removed because it was very greatly enlarged. Then the surgeon came to partially remove the gland when it was not so much enlarged but when the enlargement was associated with constitutional symptoms. In many instances the patient's health was improved by operative procedure. In others it was not. In this early period of the operative treatment of goiter the pathologist attempted to determine the possible relationship between the morphologic condition of the removed gland and the symptoms, if present, which the patient had exhibited before operation. Twenty years ago the relationship between the morphology of the gland and symptoms of goiter was in great confusion chiefly because of two factors:

1. Clinicians were in radical disagreement concerning the grouping of the various symptoms of goiter into syndromes, the order of the development of these syndromes and their usual terminations either with or without treatment.

2. No pathologist had examined a sufficiently large number of thyroids from patients whose symptoms had been accurately observed clinically to extend the incidence of the morphology and symptoms beyond the limits of very wide error.

During the last twenty years both these factors have been greatly improved. Clinicians, with the aid of our very greatly increased knowledge of (1) the pathology of goiter, (2) the active principle of the thyroid, (3) the physiologic function of the gland, and (4) the relationship of basal metabolic rates to thyroid activity have been able to so check, extend and refine their clinical observations that syndromes are now accurately defined and are readily recognizable by experienced diagnosticians. Coincident with this the very great increase in the number of cases in which partial thyroidectomy has been per-

formed has given the pathologist an opportunity to study sufficient material from patients whose clinical conditions have been definitely diagnosed to make his classifications of real value.

By no means are all clinicians or all pathologists in agreement concerning either the classification of the various syndromes of goiter or of their relation to the pathology of the thyroid in all the minor ramifications of the subject. There is, however, general agreement. The limits of this chapter will not permit the discussion of undecided phases of the subject. What is here stated purports to be only the mass results of the study of material in the Mayo Clinic in which for years there has been substantial agreement between clinicians and pathologists as to the relationships of symptoms and morphology of the gland. This experience covers the study of resected portions of thyroid from more than 20,000 patients with goiter and of more than 4,000 entire thyroids removed at necropsy from patients dying of diseases other than those of the thyroid. All this pathologic material has been studied primarily or reviewed by only five pathologists, four of whom still have charge of the work, although a large number of able assistants have also studied the material.

The material has included an unusually large proportion of glands from various types of symptomatic goiter. It has been deficient chiefly in material from cretins and patients with various other forms of hypothyroidism. As a result of the intensive clinical study of this large number of patients with goiter and of the equally intensive study of the pathologic tissues therefrom in the Mayo Clinic, the disagreements between the clinician and the pathologist in the field of goiter are as few as those concerning any other field of medicine.

From the standpoint of their origin and symptoms, primary diseases of the thyroid may be grouped as (1) inflammations, (2) exophthalmic goiter, (3) endemic goiter, and (4) malignant tumors.

## Inflammations

Inflammations of the thyroid may develop in the previously unchanged gland (thyroiditis), or in the previously goitrous gland (strumitis). More than half the thyroids removed at

routine necropsies contain inflamed areas. A very large percentage of thyroids from exophthalmic goiter patients show some degree of inflammation which is usually acute. It is less common and more chronic in diffuse colloid and adenomatous thyroids. Inflammation in either case may be due to demonstrable bacterial invasion, for example, by staphylococci, streptococci, pneumococci and colon, typhoid, and tuberculosis bacilli. It may also be due to what are apparently toxic agents, (certainly without bacteria being demonstrable in the gland

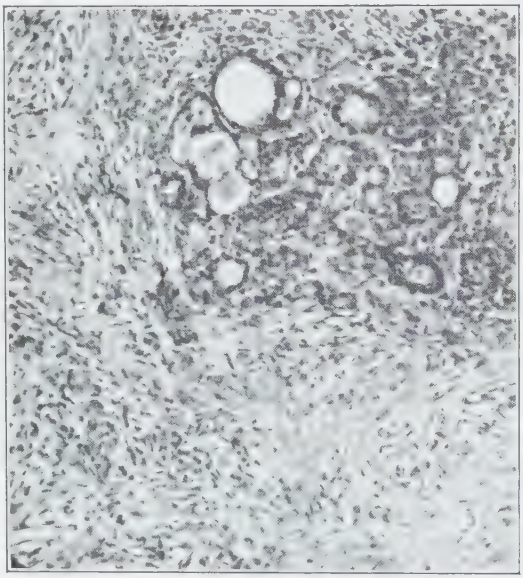

Fig. 1.—Fibrous thyroiditis (Riedel's Disease). Typical section (x120 diam.) showing inflammatory cell infiltration and compression of follicles by bands of dense fibrous connective tissue. The entire gland had the same structure.

itself) as in association with uremia, chronic nephritis, alcoholism, and so forth.

The pathologic picture of inflammations of the thyroid is usually not materially different from that of inflammations of other glandular organs. The process may be nonpurulent or purulent. There is hyperemia, leucocytic infiltration, epithelial desquamation, usually decrease or absence of colloid and more or less increase of fibrous connective tissue. When suppuration occurs there is necrosis and more or less extensive destruction of all the tissue-elements of the gland.

The lesions produced by tuberculosis or syphilis of the thyroid are not materially different from the lesions in other organs, fairly typical tubercules and gummata being formed.

Riedel's disease is an intensive chronic primary thyroiditis usually occurring in patients between thirty and fifty years of age. Usually by the time operation is resorted to the inflammation has transformed the thyroid into a hard sclerotic mass of fibrous connective tissue in which the parenchyma may have almost entirely disappeared, although some follicles may still show desquamating epithelium and some colloid (Fig. 1). Whatever its cause, the condition is analogous to that occasionally, though rarely, met with in salivary and lacrimal glands and in the pancreas.

A parasitic thyroiditis has been described by Chagas in South America which is transferred to man and to domestic animals by the bite of various insects. Besides the thyroid, the liver, spleen, cervical glands and sometimes the testicles, ovaries, and nervous and muscular systems are affected. In the acutely fatal cases the affected glands show inflammatory changes closely resembling those produced by bacterial infection. In chronic cases there is an extensive formation of connective tissue and frequently also of cysts in the affected organs.

### Exophthalmic Goiter

Exophthalmic goiter, "Graves' disease" is a constitutional disease characterized by an increased metabolic rate with resulting secondary manifestations, with a peculiar nervous syndrome, and, usually, exophthalmos, with a tendency to gastrointestinal crises of vomiting and diarrhea. The disease is probably due to the delivery to the tissues by an enlarged thyroid of an excessive amount of secretion. There is much clinical and considerable complementary experimental evidence to show that this secretion, if not abnormal in the beginning of the process, soon becomes so in composition as well as in amount, although proof of this is as yet inconclusive. The basic etiologic factor is unknown.

In exophthalmic goiter the thyroid is diffusely enlarged although there may be palpable nodules. In practically all cases not previously treated with iodine the diffuse enlarge-

ment of the gland is shown on section to be the result of marked primary hypertrophy and hyperplasia of the parenchyma. This is associated with increased vascularity (overfilled capillaries), throughout the gland. Stainable colloid is absent or reduced in amount and is feebly staining.

In approximately 30 per cent of the glands from patients from the Mississippi Valley there are found imbedded in the hypertrophic and hyperplastic parenchyma one or more adenomas which by their appearance suggest that they may have existed previous to the development of the hypertrophy and hyperplasia of the remainder of the parenchyma.

The use of the term "hypertrophy" in the thyroid is here restricted to indicate an increase in the *size* of the parenchymal cells. To apply the term loosely to gross thyroid enlargement or to an increase in the *number* of parenchymal cells and follicles is inaccurate and unwarranted. A distinction must also be made between true cell hypertrophy and cellular edema. Edematous thyroid parenchymal cells are commonly found either in the lax walls of soft cysts or on papilla-form projections into such cysts. Hypertrophy of a parenchymal cell is indubitable evidence that the cell has overworked.

The term "hyperplasia" in the thyroid is here used to mean an increase in the actual number of cells within a given follicle. The term is often misapplied to simple cell hypertrophy. In the histologic examination of sections of thyroid in which the tissue has been fixed and cut so as to preserve the integrity of the follicles, it is possible to form a fairly correct estimate of the number of cells in that portion of the wall shown in cross section. Repeated counts of the actual number of cells lining the follicular rings, each constituted by a 10-micron section, through a considerable area of the normal thyroid of man, show that there are from ten to sixty nuclei visible in each ring. Similar counts of rings, constituted each by 10-micron sections through a considerable area of thyroid tissue from patients with exophthalmic goiter not previously treated with iodine, demonstrate a very great increase in the number of nuclei in each ring. This is obvious in the most cursory microscopic examination from the infoldings and papilliform projections of the parenchyma into the cavities of the follicles (Fig. 2). Hyper-

plasia of parenchymal thyroid cells is even more unequivocal evidence of hyperfunction than is simple cell-hypertrophy. It cannot be mistaken for edema and it indicates greater functional stress.

Besides the, probably accidental, encapsulated adenomas occasionally found in the hypertrophic and hyperplastic thyroids in cases of exophthalmic goiter there are occasionally found in such glands areas of thyroid follicles with, usually, imperfectly developed epithelium but without demonstrable encapsulation. The weight of evidence is strongly in favor of the

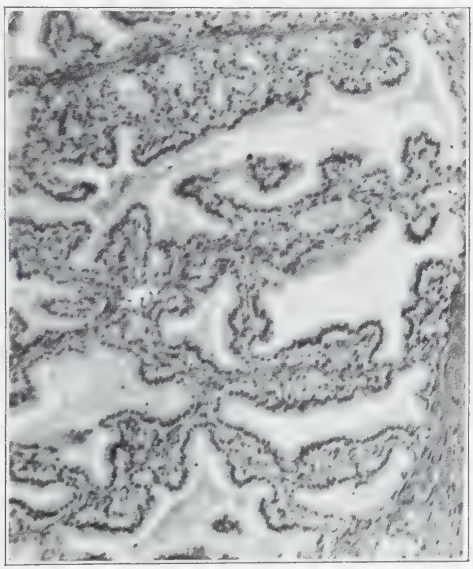

Fig. 2.—Exophthalmic goiter. The patient was a woman, aged twenty years, who had had active exophthalmic goiter for ten months prior to operation. The section (x100 diam.) shows marked hyperplasia as well as hypertrophy of the parenchymal cells with very lightly staining colloid within the follicles.

development of these groups of nonencapsulated, apparently new, follicles, as a continuation of the process causing the hyperplasia. This multiplication of follicles without encapsulation is best designated "adenomatosis."

In the thyroid from a patient with a long history of exophthalmic goiter with remissions and exacerbations, in many follicles the epithelium may be found so atrophic and flattened as to be almost unrecognizable as epithelium, while in other follicles or portions of the same follicle small groups of

parenchymal cells may be found that are not so flattened and in which the nuclei are sharply staining. These groups of cells are usually in immediate apposition to small areas of colloid within the follicle which either is freely staining or does not stain at all.

In glands from patients with exophthalmic goiter who have been recently treated with iodine a similar condition is present. The parenchymal cells are no longer columnar and hypertrophic, but are cuboidal, flattened or even markedly atrophic. The follicles are filled with thin (lightly staining) colloid, apparently of recent deposition. This change in the character of the parenchyma of the thyroid after the administration of iodine suggests that the disparity which has apparently existed between the observations of pathologists on thyroids from exophthalmic goiter patients from different geographic areas may be due to the greatly varying incidence of iodine in the different regions. Variations in the amount of iodine acquired through food and other nonmedical agencies may also account for fluctuations in the symptoms and for variations in the pathologic conditions of the thyroids from patients with exophthalmic goiter who have not been treated with iodine.

While the condition of the parenchyma in thyroids from patients with exophthalmic goiter is the fundamental element in the pathology of the disease the amount and character of the stored colloid cannot be ignored. Generally speaking the amount and density of the colloid is in inverse ratio to the intensity of the hypertrophy and hyperplasia, which in turn are in direct ratio to the symptoms.

## Endemic Goiter

Endemic goiter in human beings is a disease due fundamentally to their failure to obtain daily a sufficient supply of iodine to permit the proper functioning of the thyroid. In other words, it is primarily hypoiodism, though other factors may be very important in its development. The thyroid may be reduced in size either because of prenatal or postnatal degeneration and resulting in one type of cretinism, or, as is much more usually the case, the thyroid may be increased in size. The enlargement of the gland may be either symmetrical and diffuse

or nodular. Associated with either type of thyroid enlargement, although very much oftener with the nodular type, there may be all grades of disturbances of metabolism from marked reduction of the basal rate (frank myxedema) through slight reductions (mild hypothyroidism) and normal rates (nonsymptomatic or simple goiter) to slight accelerations (mild hyperthyroidism) and finally marked acceleration associated with the clinical symptoms due to such marked elevations (Plummer's "hyperfunctioning adenomatous goiter," "basedowized exophthalmic goiter").

**Cretinism** is associated with absence or great reduction in size of the thyroid, either from prenatal or postnatal degeneration of the gland, or with an enlarged and usually nodular (adenomatous) thyroid which, even if it contains functioning epithelium, is failing to deliver sufficient normal thyroxin to the tissues. In about one-fourth of the cases the thyroid is greatly atrophied or entirely absent. In a few it has been reported normal in size. In more than half of the cases it is enlarged. Histologically the follicles are usually small. In those containing colloid the parenchymal cells are small, cuboidal or flat. The nuclei are usually swollen and often apparently disintegrating. The colloid when present is very deeply staining. Dense fibrous connective tissue may constitute a large portion of the gland.

**Myxedema**, either in the infant or adult, is apparently associated with conditions in the thyroid which do not differ materially from those described as associated with cretinism. However, myxedematous patients do not give a history of having had colloid goiter; yet the thyroid in many patients with marked myxedema apparently contains some parenchyma more capable of being stimulated to function than does that in glands of cretins, although it is not delivering to the tissues a sufficient amount of thyroxin.

**Mild hypothyroidism**, as indicated by mental and skin conditions and a basal metabolic rate 10 to 18 per cent below average normal, is probably present at some time in the history of all patients suffering from endemic thyroid enlargement. However it is difficult, if not impossible, to evaluate even from careful histologic examination the morphologic changes indicat-

ing such slightly reduced physiologic activity of the gland. The same statement holds true with regard to the pathology of enlarged thyroids in patients who are exhibiting symptoms of mild hyperthyroidism (basal metabolic rates 10 to 18 per cent above average normal). The pathologic examination of the thyroid, microscopic as well as gross, cannot be expected to give data which may be measured with sufficient accuracy to indicate small changes in function of the entire gland. It is only when these functional changes go well beyond the limits of the "factor of safety," the "regulatory mechanism" of the gland, that their effects on the sum total of the structure can be evaluated.

No doubt before accurate estimations of the metabolic rate become a factor in diagnosis many patients with marked endemic thyroid enlargement and who had unrecognized mild hypothyroidism were subjected to surgical operations usually for cosmetic reasons or because of discomfort from conditions arising from the glandular enlargement *per se*. Pathologic examinations of the glands from such patients and also from patients with endemic goiter who have normal or but slightly increased metabolic rates show one of three general conditions: (1) A diffuse enlargement of the gland due to deposition of colloid within the follicles. The superficial blood vessels and those within the larger septums of the gland may be greatly distended. The capillaries in the follicular walls are compressed. Thus, externally the gland is "bloody," within it is "dry" and viscid from colloid. The lobules are large and the connective tissue septums thickened. The parenchymal cells if present are low cuboidal, flattened, or so atrophied as to be almost indistinguishable. They may be desquamating or have completely disappeared. Prolonged search of microscopic sections will almost always reveal scattered islands of parenchymal cells which are apparently in fairly good condition for functioning. The colloid substance is very greatly increased in amount and in density. Enlarged thyroids in this stage of evenly diffuse colloid deposition do not frequently come to operation. (2) In many large endemic goiters along with the diffuse deposition of colloid and other conditions described in (1) there are found areas of tissue composed of apparently newly formed follicles, many of which may be very small and

of the embryonic type. These groups of newly formed follicles are frequently very incompletely or not at all enclosed with fibrous capsules. This formation is best designated as "adenomatosis" (Fig. 3). (3) In a very great proportion of all enlarged thyroids of endemic goiter there are found one or many definitely encapsulated adenomas. Sometimes these are so numerous as to constitute most, if not all of the gland. Considerably more than half of these adenomas are distinctly of the so-called "fetal" type, that is they consist in large part

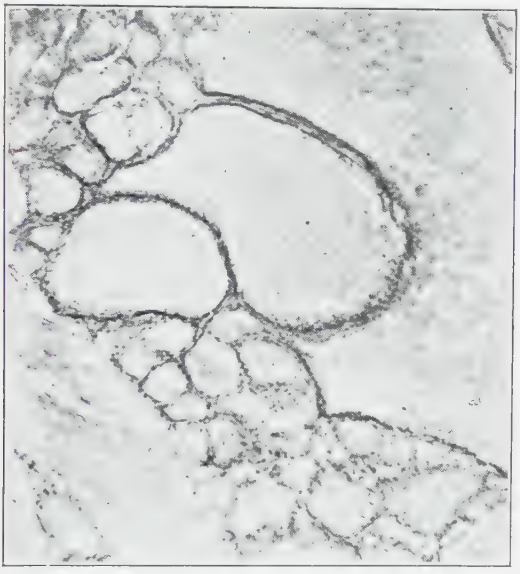

Fig. 3.—"Simple" endemic goiter with "Adenomatosis." Man, aged forty-eight years. Has had goiter without symptoms except slight pressure on trachea about seven years. Section (x100 diam.) shows follicles distended with densely staining colloid and areas of small apparently newly formed follicles ("adenomatosis").

of follicles made up of small cuboid or embryonic epithelium and without lumina. The smaller proportion of such adenomas contain many follicles, the cavities of which are packed with dense colloid. In many of the larger adenomas it may be impossible to determine within the limits of a microscopic section that the tissue is a part of an adenoma and not of a diffuse colloid goiter. This leads to the suspicion in some instances that such an "adenoma" is not primarily an entirely new growth but that it represents a lobule or other mass of thyroid tissue which has been cut off from the remainder of the gland by

chronic inflammatory thickening of the connective tissue of the normal septums with a subsequent development of some new follicles, thus causing the entire mass to have the appearance of a new growth, an adenoma.

The clinical syndrome of hyperthyroidism which Plummer has succeeded in clearly differentiating from exophthalmic goiter and which had previously been hazily recognized by the terms "basedowized" or "incomplete" exophthalmic goiter, is apparently caused by an abnormally high and unregulated concentration of normal thyroxin in the body, producing an increased basal metabolic rate with the resulting secondary manifestations. The symptoms can best be explained as increased purely physiologic reactions and may be exactly duplicated by the administration to well persons of preparations of thyroid or of thyroxin. The symptoms may be greatly exacerbated by the administration of iodine and are eliminated in three weeks by the resection of the adenoma or adenomas in the gland. The disease would thus appear to be caused by the production and delivery to the tissues of an excessive amount of normal thyroxin.

I have made a study of the nodular thyroids from about 250 patients with this syndrome and with basal metabolic rates of 20 or more points above normal in comparison with an equal number of thyroids from patients of approximately the same age with enlarged nodular thyroids but without symptoms of hyperthryoidism and with basal metabolic rates within 10 points of normal. Grossly the thyroids in both groups were nodular and this nodular appearance was found on section to be due in most instances to encapsulated adenomas. There were, however, some thyroids in both groups in which the nodular character was not due to encapsulated adenomas but rather to new follicle formation without encapsulation (adenomatosis) or was the result of increased and contracting interlobular connective tissue which was usually associated with round-cell infiltration indicating chronic inflammation. In the group of glands from patients with hyperthyroidism, there was hypertrophy and hyperplasia of the parenchyma which was, however, so moderate in degree and amount as readily to escape notice except by careful comparison in a large number of such thyroids with a

like number of the thyroids from patients who had exhibited no increase in basal metabolic rate. The parenchymal cells were apparently not under high functional pressure. In one portion of large follicles, most of the cavities of which were filled with dense stored colloid, there might appear small areas of very lightly staining colloid in immediate apposition to hypertrophic or hyperplastic parenchymal cells, while the parenchymal cells lining the other portions of the follicle were flattened and atrophic. In definitely encapsulated adenomas the new follicles

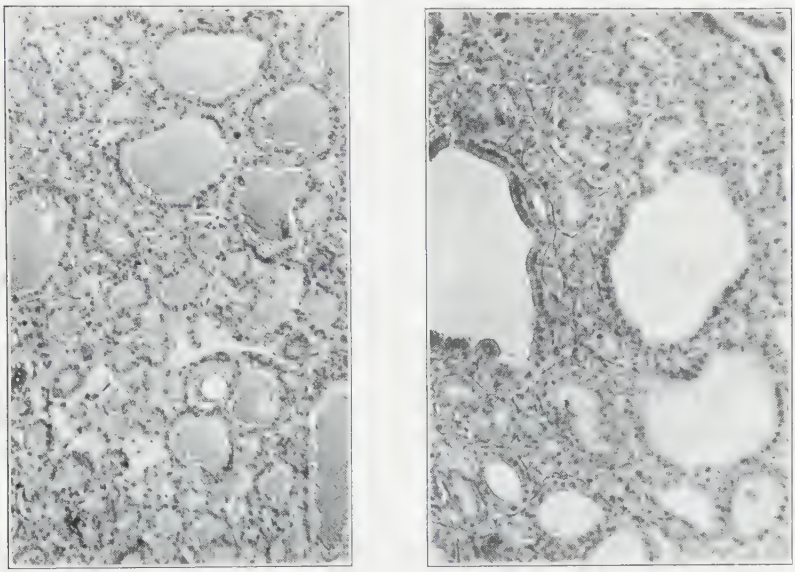

A. B.

Fig. 4.—Adenomatous endemic goiter.

A. Woman, aged thirty-nine years. Enlarged thyroid for many years. No symptoms except pressure. Section from the encapsulated adenoma (x100 diam.) shows small follicles packed with densely staining colloid.

B. Woman, aged forty years. Goiter for fourteen years. No trouble until last two months when heart began to beat faster and she became shorter of breath. Marked hyperthyroidism. No exophthalmus. Section (x100 diam.) from large encapsulated adenoma shows marked hypertrophy and hyperplasia of parenchyma with thin, feebly staining colloid.

were likely to contain dense stored colloid. Where there was diffuse new follicle formation without definite encapsulation the follicles were not so likely to contain colloid, or, if any, it was feebly staining. In the thyroids from patients without symptoms of hyperthyroidism there were moderate degrees of hypertrophy

and hyperplasia of the parenchyma in about 5 per cent of the glands examined (Fig. 4).

From this study and my previous experience I am led to believe that a detailed histologic examination of a large series of nodular thyroids from patients with endemic goiter would show so gradual a graduation in the evidences of hypofunction and hyperfunction that it would be impossible to draw a sharp line of distinction at any level. On the other hand I am confident such a study would show, as did the two series which I examined, a very great difference in the cellular evidences of hypofunction and hyperfunction in the glands from patients with high metabolic rates, for example, above +20, and the glands from patients with metabolic rates not above normal.

While there is pathologic evidence in glands from patients with this type of hyperthyroidism of the hyperfunction of the tissue, it is never so marked either in extent or degree as is that found in glands from patients with typical exophthalmic goiter unless the latter have been effectively treated with iodine preparations. There is no need of the experienced pathologist being mistaken as to the type of gland with which he is dealing. On the other hand, even the experienced pathologist may very readily find himself unable to determine from the examination of sections from a single nodular thyroid, either adenomatous or non-adenomatous, whether it came from a nonexophthalmic goiter patient with high metabolic rate, or from one with a normal metabolic rate, or from one with a moderately lowered rate. Thus, because of the relatively small histologic changes in endemic goiters from patients with such varying degrees of metabolism, we are led to the hypothesis that some disturbance of the regulatory mechanism for the discharge of thyroxin into the tissues may be a greater factor in the variation of symptoms in these cases than are the apparent changes in the producing capacity of the parenchymal cells.

## Malignant Tumors

Malignant tumors of the thyroid are much more common than is generally believed. Thus, in a series of 16,549 thyroids removed at operation in the Mayo Clinic, 207 were malignant. Besides these 207 there were 83 cases in which a diagnosis of

malignancy of the thyroid was made but the tumors were not operable. Kocher reported 235 cases of malignancy in an operative experience of about 3,500 cases of goiter. Besides these there were seventy-six cases on which he had incomplete data. I collected 1,430 reported cases up to January 1, 1921.

The pathologic diagnosis of malignant tumors of the thyroid is difficult owing to the great variation in the histology of the tumor tissue and its resemblance to that in nonmalignant processes. When the apparently rapidly growing tissue is found invading adjacent structures, such as blood vessels or the thyroid

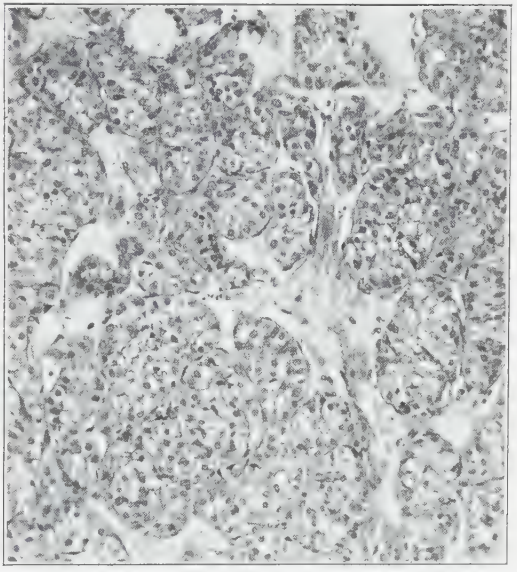

Fig. 5.—Malignant adenoma. A woman, aged twenty-seven, had had goiter for ten years; it had grown gradually until about two months before, when it began to increase more rapidly. A nodular tumor of the right lobe was extirpated. One hundred ninety grams of tissue were removed. The patient returned for examination four years after operation with recurrence of a tumor in the right lobe. The entire right lobe of the thyroid, which was fixed to the trachea and cricoid cartilage and involved the larynx, was removed. One hundred grams of tissue were removed. Two and one-half years after the second operation the patient reported that the gland was enlarging slowly; she was growing weaker and showing some cachexia. Death occurred eight years after the first operation from tracheal involvement and probably metastasis to the lungs. Section from tissue removed at first operation (x100 diam.)

capsule, the diagnosis of course is simple. But the surgeon who consistently follows up for long periods of time (five to fifteen years) patients from whom he has removed "adenomatous" thyroids will be led to conclude from the incidence of recurring tumors which are later found to be malignant that

the pathologic examination of the tissue first removed, however thorough it may have been, must have failed to reveal the existence of invasion of adjacent structures or else that the tumor was potentially malignant without having made such invasion.

While it must be granted that malignant tumors of the thyroid may develop directly from normal adult thyroid tissue, practically all of them can be traced either pathologically or clinically to previously existing adenomas. In many such tumors

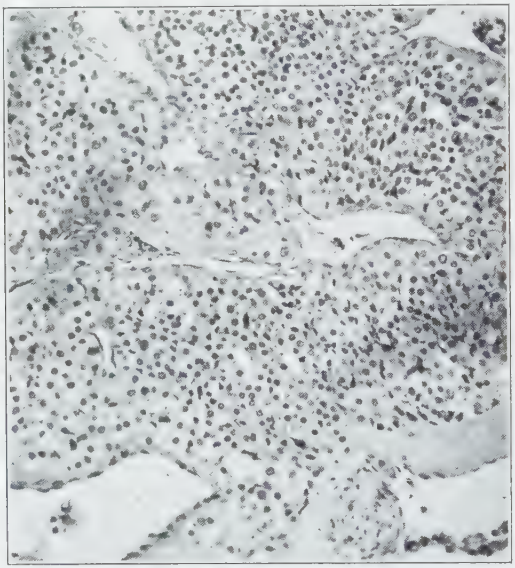

Fig. 6.—Adenomedullary carcinoma. A woman, aged thirty-four, had had goiter for eight years. A partial thyroidectomy had been performed twice elsewhere during the last two years. No pathologic examination of the tissue removed at these operations had been made. There had been a recent rapid growth. All of the right lobe except the superior pole was removed. Seventy-two grams of tissue were removed. Three months later a rapidly recurring growth, including tissue from behind the larynx, was removed by excision and cautery, and a tracheotomy was performed. Death occurred one month later. Extensive metastasis was found to the lungs, lymphatics, and left sternoclavicular articulation. Section through more solid portion of tumor removed at third operation. (x100 diam.)

their stage of development is such that the pathologist is inclined to designate them "malignant adenomas" (Fig. 5). When the carcinomatous character of the newgrowth is definite, it may be of the malignant papillomatous type, medullary type, scirrhous type, or a mixed carcinoma-sarcoma type (Fig. 6). Histologically the latter type usually contains mixed and spindle

cells (Fig. 7). The small round-cell sarcoma is usually the only type met with in which the epithelial elements of the gland are not more or less concerned in the malignant process.

The preceding discussion has been an attempt to point out the pathologic conditions of the thyroid which are met with in association with the various clinical syndromes. It seems worth while, however, to include even in so brief a statement as this the following formal grouping of the histologic conditions found in the thyroid from the viewpoint of their hypothetic development.

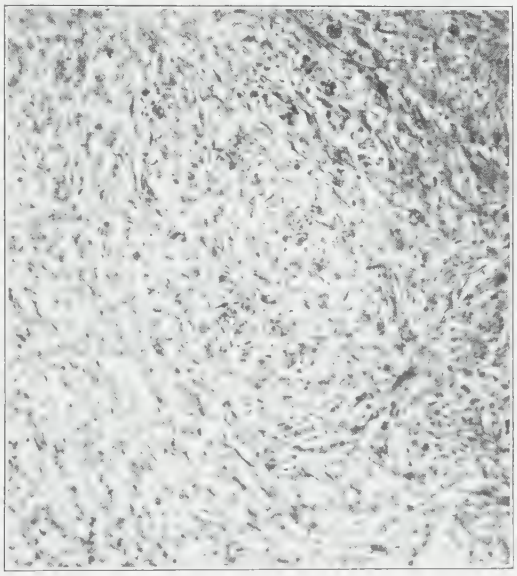

Fig. 7.—Spindle cell sarcoma. A man, aged fifty-six, had had goiter for twelve years, with accelerated growth for about three years. The left lobe and isthmus were extirpated; the tumor was infiltrating the muscle. Two hundred twenty grams of tissue were removed. The patient died two months after the operation. Section through solid area. (x100 diam.)

### Classification of Histologic Conditions of the Thyroid

I. Embryonic (undeveloped) thyroid.

II. Normal (resting) thyroid.

III. Vascular changes.

1. Hyperemia.
2. Hemorrhage (including resulting cyst formation).

IV. Inflammations.

V. Progressive changes.
   1. Hypertrophy (functional, with hyperemia).
   2. Hyperplasia ("exophthalmic" goiter).
   3. Adenomatosis (multiplication of acini without encapsulation).
   4. Regeneration (of previously atrophic parenchyma).

VI. Retrogressive changes.
   1. Retention of secretion (colloid goiter).
   2. Atrophy (of parenchyma and stroma).
   3. Degeneration.
      a. Colloid (of parenchyma and stroma).
      b. Hyalin.
      c. Amyloid.
      d. Calcareous.
      e. Cystic.

VII. Tumors.
   1. Benign.
      a. Fetal adenomas (encapsulated).
      b. Adult adenomas (encapsulated).
   2. Malignant.
      a. Malignant adenomas.
      b. Carcinomas.
      c. Sarcomas.

# CHAPTER III

# THE HEART IN GOITER

Samuel B. Grant, M.D., St. Louis

## Introduction

The importance of an intimate knowledge of the rôle played by the heart in various types of goiter is evident when one considers the fact that cardiac symptoms are very frequently present, and that cardiac failure is one of the principal causes of death in goiter patients. Among the earliest symptoms of hyperthyroidism are palpitation of the heart, tachycardia, and dyspnea. These may be present when other symptoms of exophthalmic or toxic goiter, including enlargement of the thyroid gland, are so slight as to be completely unrecognized. It occasionally happens that patients are treated for heart disease for a considerable length of time before it is discovered that goiter is the cause of the cardiac symptoms. In the late stages of goiter there may be signs of chronic cardiac failure, as evidenced by an enlarged heart, irregularities of the pulse, edema of extremities, and in some cases such extreme cardiac failure as may result in orthopnea and anasarca.

## The Cause of Cardiac Symptoms in Goiter

Overactivity of the thyroid gland causes an increase in the amount of oxygen used by the body tissues, even when the body is at complete rest. In order that this increased amount of oxygen may be supplied to the tissues, it is necessary for the heart to increase the flow of blood. To do this it must beat more *forcibly* and more *rapidly*. When the hyperthyroid patient does any muscular work, the rate and force of the heart must be further increased to supply the oxygen necessary for muscle contractions. It is evident, therefore, that the heart is constantly working under a load. The heart rate in such cases, with the patient at complete rest, varies from 90 to 150 or even more. On exercise the heart rate will necessarily be

even faster. It is not surprising, therefore, that there is palpitation, and that even slight exertion may be accompanied by dyspnea. Some idea of the increased amount of work performed by the heart in hyperthyroidism may be obtained through the following calculations. In a goiter patient whose resting pulse is 120, the heart beats 50 more times per minute than it does in the normal individual whose resting pulse is 70. In twenty-four hours, therefore, even if the patient remained at complete rest in bed, the heart would beat $60 \times 24 \times 50$ or 72,000 more times than in the normal individual. In addition each contraction would be more forcible than normal. The heart can supply these 72,000 extra contractions every day and maintain the increased force of the contractions very readily for a considerable length of time. It is generally recognized, however, that this tremendously increased amount of work, going on over a long period of time, is a principal cause of the eventual failure of the heart in goiter. Just as in the case of any other muscular tissue, the increased work is accompanied by hypertrophy of the cardiac muscle and an enlargement of the heart. Eventually, however, the heart presumably becomes fatigued as a result of the heavy and continuous demands laid upon it, and symptoms of cardiac failure result.

In searching for some other cause of the heart failure than this enormous and long-continued strain, other theories have been advanced, namely, that the cardiac disturbance results from the action of the toxic products of the goiter, affecting the heart through its nervous mechanism, or acting directly on the heart muscle itself. There is some evidence in favor of such toxic action. The force and rate of the heart beat in hyperthyroidism seem to be greater than would be necessary if the increased oxygen consumption were the only factor involved. But for practical purposes it is sufficient to consider the prolonged overactivity of the heart as the cause of cardiac failure in goiter.

It is true that the heart withstands without injury tremendous strains due to great physical exertion, and may beat very rapidly during fever, but the strain of repeated physical exertion is necessarily followed by periods of rest, and fever is usually of short duration relative to the duration of hyper-

thyroidism. However, athletes are known to develop hypertrophy of heart, and in long-continued fever, heart failure may occur. Auricular fibrillation so frequently found in goiter cases occasionally develops during the course of any febrile disease.

## Morbid Anatomy

At autopsy the muculature of the heart is usually found hypertrophied, but this may be considered as a physiologic change. In many cases no pathologic change can be discovered. In some, myocardial scarring, round-cell infiltration of the muscle may be present. In others there is fatty degeneration. These changes, however, are often entirely inadequate as an explanation of the great functional disturbance of the heart which so frequently accompanies goiter. Instances of acute myocardial necrosis have been found at autopsy of patients dying of acute heart disease complicating exophthalmic goiter. Such pathologic changes would indicate a toxic action on the heart muscle, but such changes are certainly very rarely found. Moreover, the heart disease accompanying goiter is usually not an acute heart disease, but is one that develops gradually. The vast majority of cases at death show either no pathologic changes in the heart muscle, or else the fatty degeneration, myocardial scarring or round-cell infiltration mentioned above.

It seems unnecessary to say that goiter is not a cause of valvular heart disease. In a large proportion of cases a blowing systolic murmur is heard at the pulmonic area, and occasionally the same murmur may be heard at the apex. This must be considered as a functional murmur, very probably caused by the increased amount of blood flowing through the pulmonic orifice. At autopsy all of the valves are found to be normal except in the few instances in which an independent rheumatic or syphilitic valvular disease is present.

## Symptoms

Tachycardia is one of the cardinal symptoms of hyperthyroidism, and the degree of tachycardia roughly parallels the degree of elevation of the basal metabolism. It is one of the earliest symptoms of exophthalmic goiter, and marks the onset of toxicity in adenomatous goiter. The heart rate during rest

may vary from 90 to 150, or even more, depending in a general way upon the height of the basal metabolism—or, in other words, depending upon the increase in the amount of oxygen being used by the body. The patient may or may not be conscious of this tachycardia, but he usually is, because in addition to beating rapidly, the heart is also beating more vigorously than normal.

If the resting pulse is rapid, any exertion will call for a still further increase in the pulse rate and a still more forceful heart action, and this almost invariably causes the sensation of palpitation of the heart, identical in all respects to the palpitation a normal person experiences on strenuous exertion. The act of merely walking up a flight of stairs may cause an increase in the total amount of oxygen used by the body equivalent to the amount of oxygen used by a normal individual during strenuous muscular exertion. This quite naturally results in dyspnea. When the basal metabolism is unusually high, walking across the floor may call for such a great cardiac output that the heart is unable to respond, and the patient suffers from dyspnea. The heart in these cases may be normal in every respect. The symptoms of tachycardia, palpitation and dyspnea are caused entirely by the fact that the normal heart is being required to maintain a greatly increased blood flow.

Thus we see that it is perfectly natural for a patient with hyperthyroidism to have tachycardia even when at rest, and on exertion it is not surprising that he notices palpitation and dyspnea. The symptoms are not due to disease of the heart, but are the result of the excessive amount of work required of the heart. In so far as the heart is concerned, they are physiologic and not pathologic symptoms.

These symptoms continue for long periods of time, and may be the only cardiac symptoms for months or years. In some cases the next symptom will be a slight edema of the feet and legs, noticeable at the end of the day when the patient is up and about, and disappearing overnight. In others the next cardiac development will be the occurrence of periods of transient auricular fibrillation, which eventually changes to continuous auricular fibrillation. In some instances auricular fibrillation may be continuous from the first attack. The tran-

sient periods of fibrillation may last for only a few minutes or a few hours, or may continue for several days, and terminate with the resumption of normal rhythm. During the attacks the heart action is absolutely irregular and the rate is usually very rapid, 140 or more per minute. The patient is ordinarily conscious of these transient attacks because of distress, anxiety, and an increase in dyspnea and palpitation. He may notice that the pulse is irregular.

Even in the presence of permanent auricular fibrillation the cardiac function may continue to be surprisingly good for long periods of time. Palpitation and dyspnea are increased, but there may still be no edema. Usually, however, when auricular fibrillation becomes continuous for any long period of time, symptoms of marked cardiac decompensation develop. Edema appears and increases until there is pitting edema of the feet and legs, and sometimes of the thighs; in more advanced stages effusions develop in the pleural and peritoneal cavities, and there is subcutaneous edema of the abdominal and thoracic walls, and marked pitting edema over the lower part of the back. The dyspnea at this stage is so severe that the patient is unable to lie flat, and may be so extreme that he is forced to remain sitting in a chair in order to breathe with less difficulty. When the patient is kept in bed, the edema over the sacral region and back of the thighs is usually the most marked, and with improvement of the cardiac condition it disappears last in these regions.

Although the majority of cases of advanced cardiac decompensation in goiter patients is characterized by auricular fibrillation, there are some cases in which the heart rhythm is perfectly regular and remains so while all the classical symptoms of heart failure described above develop. In our experience most of these cases have had markedly enlarged hearts.

### Physical Signs

Examination of a hyperthyroid patient with no cardiac symptoms other than tachycardia, palpitation and dyspnea usually reveals a forceful apex impulse, either at or just outside the nipple line, and on percussion the outline of cardiac dullness is found enlarged to the left. This is ordinarily inter-

preted as an indication of hypertrophy of the heart. On auscultation one finds the heart sounds at the apex loud, and particularly the first sound is loud and snapping in quality, similar to the type of first heart sound in mitral stenosis. This loud character of the first heart sound is presumably an expression of the increased force of the cardiac contraction, since this sound is caused chiefly by the contraction of the ventricular musculature.

Not infrequently one finds that the snapping first sound is not present, and the sounds may have the characteristics of a heart in a normal person, or may even be of poor quality and less intense than normal. After a period of rest in bed for several days or a week or two, the heart sounds in such cases often become loud and snapping. It is not unreasonable to assume then that the absence of the loud snapping quality of the first sound is an indication of some degree of exhaustion of the heart muscle, and it has been found wise to postpone operation in such cases and keep the patient at rest until the heart has had a chance to regain its normal vigor.

In a large proportion of cases there is a blowing systolic murmur in the pulmonic area. In some instances this murmur is quite loud and harsh, and may be transmitted to the apex. It is to be considered as a functional murmur, and does not indicate valvular disease. In rare instances when the heart is tremendously enlarged, a diastolic murmur is heard in the pulmonic area. This is probably the result of a dilatation of the pulmonic orifice with a relative insufficiency of the pulmonic valve.

Auricular fibrillation may be readily diagnosed without the aid of special apparatus in the vast majority of instances. On auscultation the cardiac rhythm is absolutely irregular, and the pulse is irregular in both rhythm and force. Extrasystoles are a rather infrequent occurrence in hyperthyroidism, so that one is safe in saying that any grossly irregular heart action in a goiter patient is due to auricular fibrillation. Even if present, however, extrasystoles are usually easily distinguished and auricular fibrillation excluded because of the fundamentally regular rhythm.

In the late stages of goiter there may be all the signs of

extreme heart failure. The heart is sometimes greatly enlarged to percussion, and the apex impulse may be visible and palpable in the anterior axillary line. Edema of the subcutaneous tissues is readily recognized, but it is important to remember that after a patient has been kept in bed the edema of the feet and legs may disappear, but edema over the lower part of the back and over the sacrum may appear and persist for a much longer time. This region becomes the most dependent part when a patient remains in bed, particularly if he is propped up on several pillows, and the hydrostatic pressure is then greater in the lower part of the back than in the feet and legs. Edema may also persist in the posterior aspect of the thighs for a long time. Often edema in these regions will be overlooked, and the patient may even be considered as ready for operation, unless the parts are specially examined for subcutaneous edema. Ascites and pleural effusion are, of course, recognized by the usual physical signs.

### Electrocardiography

A striking evidence that morphologic changes in the heart muscle are *not* common in the average goiter patient is the fact that the majority of these patients exhibit essentially normal electrocardiograms. The toxic cases with tachycardia and forceful apex impulses frequently show an increased amplitude of Q.R.S. complexes and of the T-waves, but this may be taken merely as another indication of a heart musculature contracting more vigorously than normal. On the other hand, cases that have progressed further, to the stage where exhaustion of the heart muscle has developed, may show ventricular waves of smaller excursion than normal, such as are often seen when the ventricular contraction is weak. The important feature, however, is that there is rarely any change in the general shape of the Q.R.S. complexes, particularly in regard to notching of the waves or an increase in the duration of the Q.R.S. complex. In other words, the electrocardiogram does not often show evidence of pathologic changes in the myocardium.

The most important abnormality found in the electrocardiogram is auricular fibrillation, which can be identified beyond any question of doubt in the record of cases in which the diagnosis

cannot be positively established by physical examination. Even in cases with auricular fibrillation, however, the ventricular waves of the electrocardiogram are usually entirely normal in shape and duration.

Paroxysmal tachycardia is rarely found in goiter patients. I have seen only one such case. The diagnosis is made usually by the abrupt onset and abrupt ending of the paroxysms; by the absolute steadiness of the heart rate, and by the effect of stimulation on the vagus nerve. Heavy pressure over the vagus nerve in the neck will cause no gradual slowing of the pulse, but may cause a sudden change from the unusually rapid rate to a slow or less rapid rate—in other words, vagus pressure may end the paroxysm of tachycardia. If an electrocardiographic record of the beginning or end of an attack of paroxysmal tachycardia can be obtained, it is possible to determine definitely the nature of the attack.

In long standing cases with cardiac failure, particularly those with edema, cyanosis and very marked dyspnea, other abnormalities of the electrocardiogram may be noted. The most frequent is inversion of the T-waves in the first and second leads, and this may be taken as an indication of myocardial disease. An inverted T-wave in the third lead alone cannot be considered as significant. Bundle-branch block is extremely rare in goiter patients. In some cases a slurring or abnormal notching of the Q.R.S. complex, or a prolongation of the Q.R.S. interval is found, indicating disease of the ventricular muscle. The changes suggesting preponderating hypertrophy of the left ventricle are also occasionally present. In a few instances abnormally small T-waves are found, with Q.R.S. waves of normal or large excursion, and this has been taken to indicate the presence of a diffuse scarring in the heart musculature.

In many cases of long standing adenoma of the thyroid, where the patient has reached the age of over fifty, it is difficult to determine how much of the cardiac disturbance is resulting from the toxic adenoma, and how much of it is the result of independent cardiac disease. Occasionally toxic goiter is present in patients exhibiting the classical symptoms of angina pectoris, certainly largely of independent origin, but aggravated by the hyperthyroidism. Similarly many of the electrocardiographic

changes in this group of middle-aged and elderly patients may be the result of myocardial changes not dependent upon the hyperthyroidism.

It may be said in general that the electrocardiogram shows no characteristic features in goiter patients, but is of considerable value in the general estimation of the condition of the heart.

## Prognosis

Goiter patients naturally fall into two groups when considered in relation to the heart. First, those in whom there are dyspnea and palpitation, but no signs or symptoms of actual heart failure; second, those in whom there is evidence of congestive heart failure. The prognosis as regards the heart is excellent in the first group, because if the hyperthyroidism is alleviated, by whatever means, the symptoms of palpitation and dyspnea disappear, and the patient is left with a normal heart. In the second group a long period of preliminary cardiac treatment may be necessary before it is advisable to operate, but in the patients in whom it is possible to reduce the basal metabolism to normal by operation, a most striking improvement in the condition of the heart usually results. Indeed, there is no form of chronic cardiac disease in which there is the good prospect of improvement or recovery to the degree that is obtained in the cases of cardiac decompensation caused by goiter, when the goiter is successfully removed. The vast majority of cases either completely recover compensation, or else make very satisfactory improvement.

The immediate prognosis must be considered, that is, the question of the ability of the heart to withstand the ordeal of operation. In the cases with no cardiac symptoms other than palpitation and dyspnea, where there is no marked enlargement of the heart, and where the cardiac impulse at the apex is forceful and the heart sounds are of good quality, irrespective of the presence or absence of systolic murmurs, the heart rarely causes trouble during or after operation. Death in this type of patient is not caused by heart failure, but by thyrotoxicosis. In cases where the heart shows signs of exhaustion, but without congestive heart failure, a definite period of absolute rest in bed before operation is advisable. In some instances, ten days or two

weeks is sufficient, but in a few the heart sounds will not gain a good quality at the apex until the patient has been at rest for three or four weeks. Other factors being favorable for operation, a rest of more than four weeks for the heart alone in this type of case does not seem to be of any advantage. These patients occasionally develop transient auricular fibrillation during the first few days after operation, but although alarming at the time, regular rhythm is in most cases promptly regained and the patients make uneventful recoveries as far as the heart is concerned. After recovery from an adequate operation they usually have normal heart function. I have seen only one death attributable to postoperative auricular fibrillation and heart failure in this type of case.

The pulse rate has not been discussed in relation to prognosis, because when the rhythm is regular, the rate is almost invariably fast or relatively slow in direct relation to the height of the basal metabolism, and this factor in prognosis has been considered elsewhere.

The immediate prognosis in goiter patients with congestive heart failure must be considered differently. A few will not respond favorably to preliminary treatment directed to the improvement of cardiac function. In these the outlook is almost hopeless. One must be certain, however, that the heart treatment has been of the best, otherwise the patient may have been robbed of a health-restoring operation. Most of the patients respond well to cardiac treatment in the hospital, and eventually reach the stage where operation is possible. They then usually go through the ordeal of the operation and immediate postoperative course in a satisfactory manner, and afterwards either regain full cardiac function, or else are improved to a gratifying extent. An auricular fibrillation of long standing is very often replaced by normal rhythm shortly after a successful operation, and attacks of transient auricular fibrillation almost invariably cease. The mortality even in these cases with congestive heart failure, considering the degree of cardiac decompensation which may have been present, is surprisingly low. It must be emphasized, however, that the preoperative cardiac treatment should be extremely careful, and usually necessitates

a prolonged period of rest in a hospital, where the patient can be kept under strict observation and supervision.

## Treatment

No cardiac treatment is necessary in cases of goiter in which there are no symptoms or signs of cardiac failure. There is no advantage to be gained in these cases by preoperative digitalization, and there seem to be some disadvantages. Plummer is of the opinion that digitalis may have deleterious effects in goiter patients, and it has also been our impression that these patients do better without digitalis. In a toxic goiter patient it is almost impossible to produce any significant slowing of a regularly beating heart; the digitalis can therefore be of no advantage in this respect. The action of digitalis in increasing the strength and completeness of the ventricular muscular contraction seems to be entirely superfluous, because the heart is already being overstimulated by the hyperthyroid condition. The only effect of the digitalis, therefore, seems to be a toxic effect, and this is sometimes apparently manifested by the unexpected development of auricular fibrillation during the immediate postoperative period in digitalized patients.

In a group of patients manifesting signs of beginning "exhaustion" of the heart muscle, but without any signs of congestive heart failure, the only treatment indicated concerning the heart is rest in bed, and the usual preoperative measures, such as high caloric diet, iodine if indicated, etc. These patients are particularly apt to develop transient auricular fibrillation during the immediate postoperative period, but, nevertheless, digitalis should be withheld, because in general they react more favorably without it. An example of the type of experience which has led us to adopt this opinion is the following: A patient with toxic adenoma of the thyroid gland had been kept at rest for a considerable period because the heart sounds at the apex were quite weak in the presence of a basal metabolism of +60. There was no marked enlargement of the heart, as shown by physical examination and x-ray, and there were no signs of cardiac insufficiency, i.e., no edema, cyanosis, or dyspnea other than moderate dyspnea on climbing a flight of stairs. No digitalis was given. During the night following subtotal

thyroidectomy, the patient developed an irregular pulse, as reported by an intelligent and well-trained nurse. After the irregular rhythm had persisted for several hours and before the patient was seen on morning rounds, regular rhythm was reestablished. On the second postoperative day, he again developed an irregular pulse, with a heart rate at the apex of 200 per minute. His cardiac distress was extreme. Digitalis was withheld for approximately five hours in the hope that regular rhythm would be established spontaneously. This failing, he was given almost a full physiologic dose of digifoline subcutaneously, a small part of it being given intravenously. The heart rate slowed to 170, but in spite of the administration of more digitalis within the following six hours, no further slowing was obtained. No nausea or other symptoms of toxic digitalis action developed. The irregular heart action continued and the patient expired twelve hours after the first dose of digitalis had been given. Obviously the digitalis did not produce the desired effect upon the heart rate. One cannot help but wonder whether he would not have regained normal rhythm spontaneously if digitalis had been entirely withheld. One sees so many instances of transient postoperative auricular fibrillation in which no ill effects develop in spite of the fact that digitalis is withheld, and in which normal rhythm is spontaneously regained, and so very few instances in which digitalization even *seems* to have a favorable effect in these patients, that it seems logical to conclude that digitalis had best be omitted when dealing with this class of goiter patients. It is strange that a drug which is invaluable in other forms of cardiac afflictions, and so particularly valuable in auricular fibrillation, should be of so little value, and perhaps even harmful, in certain goiter cases.

Quinidine may eventually be found of considerable value in the auricular fibrillation of goiter patients. They are said to tolerate it well, and regain normal cardiac mechanism in a high percentage of cases. Inasmuch as goiter patients with auricular fibrillation tend to spontaneously regain normal rhythm, quinidine perhaps does not deserve credit for all that it seems to accomplish. It is conceivable that it may develop that quini-

dine is of value during the immediate postoperative period. I have used it in a few cases with apparently favorable effect, but have been unusually cautious in the use of the drug because I had the misfortune of observing the death of four patients being treated with quinidine in a well-known heart clinic, the deaths being definitely attributable to emboli from mural thrombi in two instances, and apparently to a toxic effect of the quinidine in the other two. The danger from mural thrombi would probably not be present in goiter cases where fibrillation was only of very short duration, and certainly not present when it was given with the hope of preventing fibrillation during the immediate postoperative period.

**Treatment of Goiter Patients with Congestive Heart Failure.**—When a patient presents himself for relief of symptoms of congestive heart failure caused by goiter, the first consideration is the treatment of the cardiac complications. These patients may have most extensive subcutaneous edema, and in addition effusion of fluid into the pleural or peritoneal spaces, or in both spaces. The pulse is usually irregular, and may be very rapid.

Hospitalization and absolute rest in bed is the first essential. Because of orthopnea it may be difficult to arrange the patient comfortably, but in the absence of a special bed, this can usually be accomplished with a suitable back rest, and sometimes additional comfort is obtained by placing a rolled blanket or similar object beneath the mattress just under the knees, to prevent the patient from constantly slipping down from the back rest. On the first night in the hospital, at least, morphine should be administered hypodermically, and repeated in smaller doses on the following evenings, for not more than two or three days. In the meantime, sufficient improvement may be obtained in the general condition to enable the patient to sleep comfortably, either spontaneously or with the help of mild sedatives.

Digitalis should be administered and the amount given should be pushed until either the desired effect is obtained, or definite digitalis toxic action is manifested. It is never necessary to give a massive physiologic dose, but if no digitalis has been taken during the previous ten days, one-fourth or one-half

of the physiologic dose (usually 5 or 10 c.c. of a good tincture) may be given at once. Then 3 or 2 c.c. may be given at six hour intervals until a little less than the estimated physiologic dose has been given, and then, if toxic symptoms have not developed, 1 c.c. should be given every six hours. If the pulse is irregular with auricular fibrillation, the heart rate at the apex is a trustworthy guide in digitalis therapy, and the drug should be continued until the heart rate has been slowed to 80 or less. Some goiter patients require unusually large amounts of digitalis to produce the required slowing, and I have seen some who needed 2 c.c. of a good tincture twice daily constantly in order to keep the heart rate down to between 80 and 90. In those cases in which the heart is regular with this type of congestive heart failure, the pulse is of much less value as a guide to digitalis therapy, and one must be guided by the development of a diuresis, or improvement in orthopnea, or else by the appearance of digitalis toxic symptoms in judging whether sufficient or too much drug has been given.

When the heart rate in auricular fibrillation has been sufficiently slowed, it is necessary to ascertain the dose of digitalis required to maintain the slow rate. This is usually about 2 c.c. of tincture daily, but varies in different cases, so that constant observation is needed, in order that the dose may be increased if the heart rate increases, or omitted and started a day or two later in smaller doses if toxic symptoms develop.

The edema requires special attention aside from the digitalis treatment, although this alone is usually followed by a marked diuresis. Of the other measures designed to affect the edema, the fluid intake may be considered first. Because of the toxic goiter symptoms, it does not seem wise to be too drastic in reducing the fluids, but a reduction to even 800 c.c. daily at the start, in many instances using the Karell diet, has not been followed by ill effects and has aided greatly in reducing edema. The Karell diet of milk alone should not be continued more than a few days at the most, and then a little more fluid may be added, plus cereals, toast, eggs, and the diet increased as rapidly as possible in order to give a high caloric intake. As

long as any edema persists, however, the fluid intake should be kept low.

Diuretic drugs are of great value. Of these diuretin and theocin have given the best results.

After all subcutaneous edema has disappeared, and when the lungs show no signs of congestion the patient should be allowed a further absolute rest. If possible, the operation should be done in one stage; but in some it is necessary to remove only one side of the goiter, and at a later date to remove the opposite side.

## CHAPTER IV

## UNUSUAL MANIFESTATIONS OF GOITER

In this chapter no attempt will be made to cover all of the unique features sometimes seen during the course of thyroid disease; rather will a hit and miss cataloguing be made of the more interesting phases of the disease called to attention during actual hospital experience. Exact interpretation is not always easy or a matter of certainty.

We often feel when confronted by problems caused by diseases of the ductless glands as Harvey Cushing[1] must have felt when he wrote:

"We find ourselves embarked on the fog-bound and poorly charted sea of endocrinology. It is easy to lose our bearings for we have, most of us, little knowledge of seafaring and only a vague idea of our destination. Our motives are varied. Some unquestionably follow the lure of discovery; some are earnest colonizers; some have the spirit of missionaries and would spread the gospel; some are attracted merely by the prospect of gain and are running full sail before the trade wind. Traders, adventurers, even pirates are certain to follow on the heels of exploration. In every profession, even ours, are to be found those who gather up beads of information of little intrinsic value which are exchanged for the property of credulous people, as gullible as the natives of a new-found land. Thus do discoveries become exploited and there were discreditable chapters in the histories of all the Great Companies of days gone by."

In interpreting his findings in this field one relies to a certain extent on fundamental knowledge which may, perhaps be very well exemplified by the following abstract:

Aub and Taylor[2] as a result of their study of basal metabolism, conclude that the rate is influenced more by the glands of internal secretion than by any other tissue of the body, and of these glands, the thyroid plays the most active part in its variation. The different glands have peculiar effects upon the

basal metabolic rate. In leucemia the rate is above normal; in anemia it is normal or slightly elevated; removal of the gonads results in lowering of the rate, although this may be attributed to the interrelationship of the gonads and thyroid; the pituitary hypersecretion it is believed tends to raise the rate; while it is felt that the adrenal gland has a considerable influence over the basal metabolism. These workers feel that "the metabolism may be regulated by two mechanisms; by the adrenals for rapid variations in rate, and by the thyroid gland for more sluggish but more important changes."

Still the interrelation of so many ductless glands makes the interpretation of clinical facts concerning them very difficult. This is more evident when we recollect with Cushing that there is relatively little exact knowledge about some of them. Then, furthermore, one must take into consideration the fact that extraneous diseases very frequently complicate the picture, something to which extended reference has been made in Chapter VI.

An important phase of the subject has been alluded to by Miller and Raulston[3] who point out that until recently the presence of tachycardia, goiter and exophthalmus was essential for the diagnosis of hyperthyroidism. However, so many cases of hyperthyroidism have been seen in which exophthalmus and extremely obvious goiter were lacking, that frequently now hyperthyroidism is diagnosed upon tachycardia alone. They feel that hyperthyroidism should be borne in mind wherever there is a history of tachycardia on excitement, because the clinical symptoms may be lacking at the time of examination. They conclude that the "salient diagnostic points in such a history are (1) transitory tachycardia on excitement and moderate exertion; (2) nervousness without cause and beyond the patient's control; and (3) tremor on excitement or exertion."

Such a case was recalled to mind by a letter received just as this chapter was being written. Mrs. B. a resident of Tennessee, informs me that she now weighs 120 pounds and considers her health fully restored. This is rather surprising in view of the fact that two years ago she came to my goiter service weighing 87 pounds, the subject of nervousness and palpitation which could not be explained on any reasonable basis and

with but a very slight increase in her metabolic rate. Her thyroid was scarcely enlarged at all. She aroused very little enthusiasm for thyroidectomy, but when it was explained to her that a few similar patients presenting the classical picture of toxic goiter in only a very few of its details had been incredibly benefited by the removal of the gland, she and her family expressed a hearty desire to have this tried simply as an experiment. I should be far from advocating thyroidectomy as a *routine procedure* in patients presenting a picture of physical or nervous exhaustion, still there are a few patients of this type who presented very few of the symptoms of toxic goiter at the time of examination, but who were unusually benefited by the removal of the gland. To be perfectly frank, I must state that I have utterly failed to benefit some of the few such doubtful patients upon whom I have operated. Possibly the development of a more mature experience may teach us just which members of this group are to be treated surgically and which are to be subjected to other measures.

One must not fail to note all of his impressions and therapeutic suggestions when goiter patients, particularly those of the exophthalmic type, are seen for the first time, during the, to them, somewhat trying ordeal of entering the clinic and being examined. After they have been at rest a short time there are occasional marked variations in the intensity of the physical signs that chiefly characterize exophthalmic goiter. Mr. G. (April, 1924) presented a striking example of this truth. When I first saw him in bed in the hospital, his eyes certainly manifested nothing unusual, though he and his wife declared that his exophthalmus had formerly been so extreme as to attract universal attention. During the period of my observation there were, further, no thrills and bruits in the cardinal vessels; all of this in spite of the patient's still being a very sick man with a persistently high metabolic rate and many of the other characteristic symptoms of a toxic goiter. Imagine the difficulty in many such cases of distinguishing between toxic adenoma and hyperplasia (exophthalmic goiter). I have long known that the complete clinical picture of exophthalmic goiter is lacking in very many such sufferers. Is it too much to assume, in view of one manifestation disappearing while another becomes ap-

parent from time to time, that a sufficiently protracted period of observation might enable one to more nearly complete this picture in a greater number of cases than now thought possible?

I am certain that I might have committed a serious injustice against this patient if I had removed thyroid tissue in consequence of overestimating his resistance at the time I first saw him in bed rather than done one ligation as seemed indicated to those who watched him walk in for an office examination on a hot summer day under circumstances which tried him out very fully.

Studies in blood pressure seem to have been made, as far as the literature would indicate, much less frequently in connection with exophthalmic goiter than the condition warrants. We have come to believe, in making the primary examination of our exophthalmic patients, that an increase of the pulse pressure due largely to a heightening of the systolic pressure is a pathognomonic feature of the disease. We believe it never fails when the complete clinical picture is present, and we lay great stress upon it as one of the early physical signs of importance where the clinical syndrome is very far from being complete. A matter of great importance in this connection to which attention is rarely attracted is the so-called diastolic shading of about ten points, perhaps more, which is characteristic of this disease. Sometimes the diastolic shading extends down to zero when the patient is first seen, in which event the heart is not thought to belong to a good subject for surgical intervention. With rest in bed and other appropriate therapeutic measures, the shading usually is rapidly reduced to an average of ten points if at the same time a commensurate physical gain in other directions has been made.

Some of the most important blood pressure characteristics are pointed out by Boothby[4] in a discussion of adenoma of the thyroid with hyperthyroidism. Boothby finds the diastolic blood pressure distinctly higher in adenoma with and without hyperthyroidism than in exophthalmic goiter. The systolic pressure averages higher in adenomas with hyperthyroidism than in those without hyperthyroidism or in exophthalmic goiter. The size of the peripheral cross-section and the amount of blood driven through the periphery in a unit of time is one

of the principal factors to be considered in blood pressure readings. Because of the increased metabolic rate in adenoma with hyperthyroidism and exophthalmic goiter, the flow of blood is increased to meet the greater oxygen need while the patient is at rest. "In the case of exophthalmic goiter there is an average high systolic blood pressure but a rather low average diastolic, giving a high pulse pressure; this combination coupled with an increased blood flow, indicates a relatively open periphery. On the other hand, the higher systolic and higher diastolic with increased blood flow in adenoma with hyperthyroidism indicate the association of definite hypertension. Likewise, in adenoma without hyperthyroidism the high diastolic with an increased systolic, but to a comparatively less degree, together with a normal blood flow also indicates an associated hypertension." The greater difference between the average floor systolic blood pressure and the average resting systolic blood pressure in adenomatous than in exophthalmic goiter indicates the "tendency to hypertensive contraction of the vascular tree."

One of our cases brings to mind a very important phase of the blood pressure consideration which I think should be mentioned *in extenso* here, since an appreciation of it leading to a determination of blood nitrogen may prevent other surgeons from operating for goiter on nephritic patients in whom the prognosis as to life is by no means good. Blood pressure in toxic goiter has typical wide pulse pressure with very high systolic pressure. It is differentiated from that of nephritis in that the latter shows both diastolic and systolic high with 3 to 2, or normal, relationship. Mrs. M. died in July, 1920, from nephritis after thyroidectomy. She had the characteristic curves, which alone should have kept us from operating. Again both systolic and diastolic low with abnormally wide pulse pressure even for a goiter patient precludes any operation since the prognosis is bad in this type of patient.

Very frequently profound changes in blood pressure take place immediately after removal of the thyroid, of which the two cases next mentioned seem to be good examples. They are cited because this fact may not have been impressed upon one who has not had access to a large number of patients of this type.

Mrs. B. (February, 1922) came to us with a systolic pressure which had varied from 200 to 260 with approximately normal relation to her diastolic (surely not a typical exophthalmic wide pulse pressure). Thirty-six hours after operation the systolic pressure dropped to 137, then came up to 160/80, where it remained several days with all symptoms favorable. This suggests that her very large adenomatous goiter, by pressing on large neck vessels, may have created a much higher level of pressure than was warranted by the patient's definite arteriosclerosis and probably early contracted kidney.

Mr. J. (May, 1922), with enormous adenoma and aortic lesion, had blood pressure 200/75 before thyroidectomy, but 140/65 one day later, though sitting up and subjectively in satisfactory condition.

One of the most interesting physical pictures in my entire experience was shown to me by Dr. Evarts Graham in whose clinic at Washington University was presented a patient having a goiter which was immediately projected to an unusual distance upward and forward whenever the man held his breath and strained. It was quite clear that the tumor was lifted up by something beneath it, but the explanation of the phenomenon was, I think, by no means clear in the minds of most of us who observed it until the goiter had been removed, when it was readily demonstrated that the driving force behind it was a **hernia of the lung** through the right upper thoracic orifice. Possibly many of the cases cited here as unusual manifestations of thyroid disease may not seem so to those of large experience, but this one I am sure will be of interest to every surgeon.

Mr. B. presented a most acute and unusual picture. In the course of a few days of vomiting, **ptyalism**, restlessness and fever, he was in a desperate condition with the neck tight and brawny, very tender and red, the leucocyte count 30,000, stertorous breathing, voice thick and trachea partially collapsed, according to Dr. Murphy. Of course ptyalism is well enough known as one of the vasomotor manifestations caused by exophthalmic goiter; it is not frequently seen, however, to such an extent as to rather overshadow the other clinical evidences of disease, nor does it often produce more discomfort than all the other manifestations. In order to save the reader a mass

of details I shall state that this was a patient who had suffered for some months with a rather mild form of exophthalmic goiter upon which was suddenly engrafted an acute thyroiditis. He declined very rapidly and died a few days after the acute symptoms of the last complication set in.

Mrs. C. (September, 1920) had **mydriasis** to the unusual extent that though not weeping or emotionally disturbed, her tears fell like drops in the beginning of a slow shower. While mydriasis is known to occur in goiter patients, it rarely persists to the extent of rendering the individual an object of interest and preventing her from engaging in the ordinary social and business activities of life and finally being the one thing to drive her to surgical relief.

Most of our very toxic patients have lain in bed with knees drawn almost up to the chin. The amount of **knee and hip flexion** is a fair index of the degree of toxicity; it decreases as the patient improves. It has been particularly apparent after operation which experience has shown to have been premature and rather badly borne. We are always worried about the outcome in such a patient until she straightens out the legs in bed and assumes a certain degree of composure which is never associated with the high degree of flexion mentioned above.

The eye signs of goiter are, of course, very well known and have been described in greatest detail. Most of them improve and some ultimately disappear completely after the surgical cure of the disease, but most of my readers will be interested, and some of them perhaps surprised, to note that **double vision** (divergent strabismus) which had existed in one of my patients for years, disappeared a few days after thyroidectomy (July, 1923).

The **disappearance of sugar from the urine** after the cure of undoubted thyroid disease is perhaps too common to deserve more than passing mention.

One of the most interesting phases of thyroid disease has to do with the **associated endocrine activity in women** of the thyroid and the ovaries. We now rather confidently predict an improvement in menstrual irregularity when confronted by this type of patient since having a large series of clinical experiences with amenorrhea like that of Miss B. (operated upon

in 1916). She began to menstruate normally immediately upon removal of her goiter at the age of thirty.

The reciprocal relationship between the ovaries and the thyroid is most interestingly shown in the case of Mrs. S., who had large tuboovarian masses removed for chronic inflammatory disease, with the result that a thyroid which was at that time definitely known to be normal to palpation, inspection, etc., began to enlarge three months after the operation and continued to do so until the time of this writing at the end of nine months. The right lobe is about the size of a walnut hull; the tissue is firm and slightly nodular. There are mild general findings. All the signs of early menopause are present except that there is no increase in weight; instead there is a decrease in weight probably as a result of the thyroid activity. There are also symptoms of slight nervousness and slight increase in pulse rate, together with increased appetite and a sense of pressure in the neck, as might be expected in consequence of a slightly toxic adenomatous thyroid. It is common knowledge that an overactive thyroid acts as a brake on the ovaries, but after its removal ovarian function is speedily restored. May not one, then, be pardoned a certain amount of speculation as to the likelihood of thyroid development in certain instances after removal of the antagonistic ovarian influence?

As stated previously removal of the thyroid results not infrequently in restoration of the inhibited ovary to normal activity. Mrs. D., 1923, furnished an illustration of this truth, which was carried so far as to have an almost ludicrous phase to it. She missed nine consecutive menstrual periods just after going through an exophthalmic goiter crisis. As she regained lost weight, fat accumulated upon the abdominal wall to the practical exclusion of other areas, at least in so far as her attention was concerned. She quite naturally assumed that she was pregnant, in which belief she was encouraged by a careless physician whom she engaged to deliver her, and she was naturally more than disappointed when at the expiration of the normal term nothing happened. She then entered our service in excellent condition for surgical treatment and had half of the thyroid removed. She did not miss another period for six months, whereupon the second half of the gland was resected.

She is now, at the expiration of a year since we first saw her, to all intents and purposes, a normal young woman who may confidently, I believe, expect in the absence of diseased thyroid tissue typical interruption of menstruation for nine months to be followed by the outcome which she seems so much to desire.

Large goiters, particularly those of the adenomatous variety, are quite prone to have **one lobe situated more or less deeply in the upper chest.** In my experience this is so much more frequently the left lobe that all those connected with our work have been interested in seeking a solution of the phenomenon. A number of explanations have occurred to us, of which the most likely one is given for whatever it may seem worth: The aorta in crossing the midline takes a direction towards the posterior chest wall, leaving a potential opening between it and the clavicle or first rib as well as other components of the anterior chest wall. It is to this area of low resistance that a thyroid lobe glides when for any reason it slips down out of the neck. The right side of the aortic arch lies so far forward that there is no such potential dead space, hence the right lobe is inclined to remain where the tumor originates or even to enlarge in an upward direction rather than make any marked descent.

The **sternomastoid muscle** exerts paramount influence among the several mechanical forces which tend to "mould" the enlarged thyroid. It frequently pinches (partly) off from each lobe a considerable mass, which, meeting its fellow from the opposite side, gives the impression that one-third or one-fourth of the goiter constitutes a median lobe originating from the isthmus. (A tumor of the isthmus is, however, most unusual in my experience.) The greater portion of a "pinched off" median mass usually belongs to the lobe which first became enlarged, while the trachea is nearly always pushed out of the midline by it as it grows, hence the origin of such a median mass usually is revealed by a study of these two phenomena.

Many more unique instances might be mentioned to emphasize the fact that an atypical goiter picture is exceedingly common. The purpose of this chapter, however, will have been fulfilled if the reader gains the impression that a typical picture complete in all of its details is not to be expected in every

instance. Here, as in many other fields of medicine, the absolutely 100 per cent syndrome comes at a time when a diagnosis is apparent to the least experienced observer and often only when the patient has long passed the period during which surgical relief can be undertaken without a desperate risk.

## References

[1]Cushing, Harvey: Disorders of the Pituitary Gland, Jour. Am. Med. Assn., June 18, 1921, lxxvi, 1721.

[2]Aub, Joseph C., and Taylor, Martha: The Effect of Body Tissues Other than the Thyroid upon the Basal Metabolic Rate, Endocrinology, March, 1922, vi, 255.

[3]Miller, Joseph L., and Raulston, B. O.: The Recognition of Mild Hyperthyroidism, Jour. Am. Med. Assn., October 28, 1922, lxxix, 1509.

[4]Boothby, Walter M.: Adenoma of the Thyroid with Hyperthyroidism (Thyrotoxic Adenoma), Endocrinology, January, 1921, v, 1.

## CHAPTER V

## INDICATIONS IN GENERAL FOR THE SURGICAL TREATMENT OF GOITER

The indications for the operative treatment of goiter patients in general are not so easily established as might be supposed, because as stated by Ochsner[1] after classifying the variations of the thyroid gland into the usual three groups, most of the goiters seen are of a mixed type and would be classified differently by different operators.

Granting that this be true, the matter no doubt resolves itself into different operators' establishing somewhat different indications in a given instance according to their lights, all having, of course, the same end in view. The subject is perhaps best illustrated by giving at random the suggestions which have been published recently by men who speak with authority in this field.

Pemberton[2] feels that surgery is not indicated in colloid goiter, since it is caused by iodine insufficiency and can usually be cured by the administration of iodine or thyroxin. He feels that adenoma without hyperthyroidism should be treated surgically, both for cosmetic reasons and for the relief of pressure, and because of the liability of the development of hyperthyroidism later, which in most instances comes on so insidiously that serious damage is done other organs before the surgeon is consulted. Treatment of exophthalmic goiter, because of the fact that it is a constitutional disease, aims to diminish the activity of the gland.

Guthrie[3] feels that there is much unnecessary surgery employed in the treatment of goiter, and he urges the medical treatment of simple endemic goiters, as well as those of adolescence and of pregnancy. Colloid goiters he feels should be treated medically save in the presence of cyst formation or pressure symptoms. Substernal or intrathoracic goiters he grants are surgical cases, as well as cystic or calcareous nontoxic adenomata and toxic adenomata. For the sick exophthalmic goiter

patient he recommends medical treatment supplemented by x-ray and radium, but he advises operation in these cases also if the patient does not have the time to devote to cooperation in nonsurgical treatment.

Sistrunk[4] concludes that colloid goiters, which occur in young persons, are not surgical, but are amenable to iodine and thyroxin treatment. Adenomatous goiters, which also appear in young persons, he does not consider surgical unless they produce symptoms of pressure or become very large; however, when hyperthyroidism is associated with adenoma, surgery is advocated. It was found at the Mayo Clinic that hyperplasia did not frequently accompany early adenoma, this complication developing usually after the goiter had been present an average of about sixteen years. Exophthalmic goiter was found to occur at any age and Boothby advocates surgical treatment early in the course of the disease before the vital organs have been damaged. The usual preliminary ligations of the superior thyroid vessels is advised.

The three surgeons that have just been mentioned reflect the teaching of the Mayo Clinic and all of them discuss the three phases of goiter surgery with which we are ordinarily confronted. The next three men, Cheever, Blackford, and Tinker, give us their views of surgical indications with special reference to exophthalmic goiter.

Cheever[5] feels that exact criteria of operability in exophthalmic goiter are much to be desired. He points out the three disadvantages of operative treatment, mortality, ordeal of operation, and scar, of which he admits the last two are minor in expert hands. He feels that the outcome of operation is more uncertain in thyroidectomy for hyperthyroidism than in any other peripheral operation not involving the great body cavities.

The havoc wrought by exophthalmic goiter when neglected is vividly pictured by Blackford[6] in discussing thyrotoxicosis. The typical course of exophthalmic goiter is pointed out—nine months from the onset, an explosion of symptoms more or less completely prostrating the patient, with the frequent development of gastrointestinal disorder; after the crisis reaches a climax, if it does not claim the life of the patient, she improves and goes through a period of about two years of average health,

when a second crisis appears, not so severe as the first from the standpoint of toxicity, but with increased dilatation of the heart. Most of these patients recover after the second crisis, but are left with very bad hearts. Over a period from three to ten years these individuals continue to have fairly good health, with occasional manifestations of the goiter symptoms, at the end of which time the symptoms frequently disappear, but the average patient who has gone through such a course in the end is a wreck from heart, liver, and kidney degeneration. Blackford feels keenly the necessity of early diagnosis of exophthalmic goiter together with its early surgical removal, before it has had time to completely wreck other organs. He does not feel that the damaged heart should stand in the way of thyroid surgery, but rather that it should be built up through medical treatment and relieved of its load by thyroidectomy.

Tinker[7] as a result of his own experience feels that the hyperthyroid case complicated by severe gastrointestinal symptoms is a desperate risk. He has found that when nausea, vomiting, and diarrhea have persisted in spite of treatment, the patients have invariably died. Hypertension as an accompaniment of hyperthyroidism would also place the individual in the desperate risk class; operation, however, is safely done on these patients after they have gone through preliminary treatment, that usually carried out in the toxic thyroid patient—salt-free, low protein diet, elimination, and rest in bed. Under this treatment it was found that the blood pressure could be brought to a safe point. The individual suffering from myocardial insufficiency is likewise considered a desperate risk, but, like the hypertension patient, can be greatly improved by treatment. Digitalis, regardless of dose, used until the desired results have been attained, usually clears up the auricular fibrillation, and with general care, Tinker finds that the patient improves sufficiently to be considered a good operative risk.

The next four authorities quoted deal with the second form of goiter; namely, the toxic adenoma. All of them are men of unusual experience; Boothby represents the views of the Mayo Clinic, Goetsch of the Johns Hopkins Clinic, and Lahey with Hamilton conducts the largest goiter clinic in the New

England states. Two of these men are surgeons and two internists; hence their horizon is a particularly wide one.

Boothby[8] points out the necessity of distinguishing adenoma with hyperthyroidism from exophthalmic goiter because of the difference in the clinical course, prognosis, and operative procedure. Removal of the tumor is the essential thing in adenoma with hyperthyroidism, while in exophthalmic goiter, the most essential feature is reduction of the overactivity of the diffuse parenchymatous hypertrophied thyroid by a succession of surgical procedures—hot water injection, ligations and finally thyroidectomy. Preliminary ligation is seldom of benefit in adenoma with hyperthyroidism, while in exophthalmic goiter it has a marked benefit. Enucleation of the adenoma nearly always cures the patient of adenoma with hyperthyroidism, while extensive resection of both lobes and the isthmus is necessary to bring the exophthalmic thyroid to normal function, and even then recurrences are frequently noted.

Goetsch[9] feels that many patients who are considered border-line nervous cases with symptoms greatly resembling mild hyperthyroidism, asthenia, psychasthenia, incipient tuberculosis, etc., are actually suffering from a true thyroid disorder amenable to thyroid surgery. He points out that there is no exophthalmus in diffuse adenomatosis, the thyroid is but slightly enlarged, and there is an absence of bruits and thrills. There is an increase in interstitial cellular tissue with atrophy of the colloid acini. Frequently the metabolic rate may be within the normal limit and cannot be depended upon as a diagnostic factor; Goetsch, however, has found these patients to react positively to his epinephrin hypersensitiveness test and has obtained good results in a small series of cases through resection of approximately three-fourths of each thyroid lobe.

Lahey and Hamilton[10] urge the necessity of early diagnosis in cases of thyrocardiacs, with a view to their surgical treatment. Their study of thyrocardiacs has led them to use the following rules in diagnosis of this condition:

"1. Every cardiac case in decompensation (or not in decompensation for that matter) with a goiter of whatever size or shape, and of however long standing without causing symp-

toms before the heart symptoms appeared, should be suspected of hyperthyroidism.

"2. Every cardiac who has prominent or staring eyes should be suspected of hyperthyroidism.

"3. Every case showing transient attacks of an established auricular fibrillation, where there is emaciation with pigmentation should particularly be suspected of hyperthyroidism.

"4. Every case with auricular fibrillation, with or without decompensation, in which there is a discrepancy between the patient's condition, the history and the heart findings, should be suspected of hyperthyroidism."

Lahey and Hamilton feel that in cases of heart failure the result of prolonged thyroid intoxication, thyroid surgery may be undertaken with a degree of safety after even partial restoration of compensation through palliative measures. They have implicit confidence in the ability of thyroid surgery to restore the heart through relieving it of its burden, and it is their opinion that "there is no comparable condition where persistent heart failure is consistently and safely cured by surgical measures."

This is true for Graves' disease, but not for toxic adenoma in my own experience. I can show from records that it makes little difference whether or not a toxic adenoma patient is operated upon when once the heart is completely wrecked. On an average they live, with or without operation, for about six months and then die from cardiac failure.

The foregoing represents somewhat at random views on surgical indications which have been expressed by men whose opinions demand respect. I am sure that there is fairly universal agreement with them wherever modern surgical thought obtains today.

This phase of the subject might perhaps be dismissed as completed at this point, but I think it only fair to my readers to give very much more in detail my own grasp of the indications as they impress themselves upon one who is confronted daily with the individual goiter patient. I endeavor to visualize the whole subject from three points of view:

1. Age of the patient.
2. Probable pathologic anatomy of the thyroid gland.
3. Type of damage which the patient experiences.

1. In general **age incidence** exercises a predominant influence on the choice of prodecure to be undertaken, especially if the patient comes within the bounds of childhood or adolescence. Undoubtedly the patient's physical as well as mental development may be greatly impaired by any serious derangement of the endocrine system. During this formative period mere thyroid enlargements are, of course, physiologic in character in many instances. One has but to refer to puberty, menstruation, pregnancy, etc., as examples of conditions attended by thyroid enlargement which are usually self-corrected, and in the treatment of which surgery surely has no place. These are, of course, of the simple diffuse parenchymatous type.

It is my own feeling that exophthalmic goiter should be viewed with much greater conservatism in the adolescent than in the adult, other things being equal. It is sufficient often to take the sixteen-year-old girl out of school where she is overworked and worried, send her to the seacoast where she cannot fail to get change of scene, agreeable recreation in summer, and a bit of iodine, all of which tend to relieve her symptoms.

Of course, an adenoma cannot be conservatively treated successfully during youth any more than at any other period of life, but its malign influences, detailed later, do not as a rule make themselves manifest before early middle life, thus there is frequently no urgent necessity of upsetting the endocrine balance by an operation on the thyroid gland in any of these three classes of goiter before the early adult period is reached.

The goiter in adult life as distinguished from that in the child or adolescent leaves us wholly unhampered to consider the disease on its merits alone, since there seems to be very little need of thyroid tissue after the sex type is definitely established and the individual's physical and mental growth have been acquired.

2. A study of the supposed **pathologic anatomy of the thyroid gland** is of importance in determining the treatment of every goiter patient. The more one studies goiters after their removal, the more willing he will become to admit that pure

types are not so common as he might once have thought. I agree with Ochsner's statement which opens this chapter, that mixed types involving two or all three of our usual forms of the disease are not infrequently met; still one must always bear in mind that one type predominates and must be given special consideration in the final analysis.

The diffuse **parenchymatous goiter** with or without a great amount of colloid should incline one to be rather conservative because it is likely to become nothing more than an innocuous parasite and in many instances responds to iodine treatment. This is, of course, the impersonal attitude of the physician, but one should be sufficiently openminded to realize that the opinion of real importance is that of the one on whose neck the parasite is fastened and that it is difficult sometimes to harmonize these two opinions when the appearance of the patient is important (actress, public speaker, teacher) or when a certain sense of pressure is experienced.

The **adenoma** awakens considerations of a wholly different sort. No matter at what period of life discovered, it is either a present or at least a potential source of discomfort and menace to health and life. It causes pressure symptoms more frequently than do all of the other types. It has been said by no less an authority than C. H. Mayo[11] that about 60 per cent of the adenomata become toxic sometime in middle life. The adenoma is the most insidious destroyer of myocardial tissue known to us, and it is supposed to underlie malignant degeneration in nearly all the instances where that frequently hopeless complication is encountered in surgical practice. As a matter of course surgeons experienced in this work are unanimously of the opinion that the adenoma in adult life at least and sometimes at an earlier period is a strictly surgical lesion. It must be urged, too, that its removal is alone indicated since none of our other minor operative procedures have the slightest influence upon it. It must be realized that there are very distinct limitations to be placed upon thyroidectomy for adenoma which do not exist in other forms of thyroid disease. The adenoma heart is not one which tends to return to *statu quo;* therefore it does no good to operate with this end in mind when there has been extensive myocardial damage. Since such a patient will live

just as long and the heart continue to function just about as well whether or not the thyroid be removed, it must be said that the operative risk is particularly difficult of predetermination in such instances, therefore the mortality is unreasonably and needlessly high.

The *exophthalmic* type furnishes the debatable field for all of those fair-minded surgeons who adopt a conservative attitude regarding parenchymatous goiter and a radical attitude when confronted with an adenoma. The diagnosis is not always easy to establish. In the early case there are but few of the classical manifestations; it is only reasonable when in doubt that the patient should remain under medical care until all nonoperative means of securing relief have been exhausted without a result. A quotation from Crotti[12] follows:

"Medical men, says Halsted, have every right, if they so choose, to try nonsurgical measures in the early stages of the disease. But if, failing not only to arrest the disease but also to cure their patients quickly, they do not advise operation in the safe and curable stage, they should be held to as strict accountability as when they fail to call for surgical help until a patient with acute appendicitis, for example, has developed a general diffuse peritonitis. Let us recall the words of our great master, Kocher, when he said, speaking to the internists, 'Gentlemen, do not fail to send us your patients early. We will send them back to you and in so doing will find in our work better results and more pleasure.'"

The early typical exophthalmic goiter is, as Crotti says, always strictly surgical. On the other hand, those who have had their fingers burned and have learned to dread the fire will unhesitatingly agree with me that the fulminating case is never surgical when first seen. This feeling is graphically illustrated by a saying which is popular among the internes in our hospital—"We let our bad exophthalmic goiter patients do their own dying."

It must be understood that there is no such thing as an emergency relief operation for exophthalmic goiter. Hertzler has wisely advised us never to do anything of an operative nature on a patient who is on the toxic up grade. Always wait until the peak has been passed and the sufferer is distinctly on

the down grade toward a remission. If one is to err at all in the choice of procedures in exophthalmic goiter patients, let it be distinctly on the side of conservatism, since such patients are never better risks than they appear to be on first sight and will frequently furnish most unpleasant and even disastrous surprises.

Why operate at all in exophthalmic goiter? It will probably afford these patients only an indirect benefit since the primary disease may not be in the thyroid at all. By operation we do furnish a symptomatic cure or at least we can reasonably claim to prevent by surgical means the future recurrences which in the course of time completely cripple the heart and parenchymatous organs, leaving an emaciated, so to speak, "burned out," wreck who is no longer a surgical patient, but once again a subject for medical care as she was in the earliest stages of her disease or during a typical crisis. The complete relief of an exophthalmic goiter patient's symptoms sometimes entails the recognition of individual limitations after operation. Although by no means an invalid, she must lead a quiet life, as only by so doing can she remain a useful member of society.

3. **Type of Damage Experienced.**—This third consideration is the one which appeals particularly to the patient and it is likely to be about as well understood by her as by her advisers. It might be safe to go further and state that she of all concerned is best able to evaluate the considerations that follow and best recognize the necessity of their relief.

The cosmetic consideration is one which has a vital meaning for an otherwise physically attractive young woman, especially if she be not married or is dependent for her livelihood upon a position, such as that of an actress, in which her personal charms constitute one of her chief assets; still I should be far from advising a very serious risk merely to improve a mild cosmetic defect. Here again is a debatable ground where no general rules can apply.

The mechanical consideration is vastly more important. Here we are left practically no liberty of thought. We are obliged without delay to relieve pressure upon the important structures which pass up and down the neck. Where respiratory embarrassment is present, radiograms of the neck taken

in two planes which reveal distortion of the trachea influence us very materially.

A substernal goiter, especially one that is calcified, is quite readily outlined by radiogram and should always be considered a serious menace.

Paralysis of the vocal cord from pressure on the vagus or recurrent nerve must, of course, indicate immediate surgical attention with especial care of the corresponding structures on the healthy side if one is to be very sure to avoid one of the most serious calamities which can befall the thyroid patient, namely, bilateral abducens paralysis.

The toxic goiter patient must be considered in a class by herself. She may be the possessor of an exophthalmic goiter, a toxic adenomatous goiter, or a mixture of the two, and in most instances her only hope of permanent relief lies in surgical intervention.

Malignant disease of the thyroid can be dismissed with a few words. The outlook differs in no essential from that which accompanies malignancy in any other part of the body. Patients have remained well after removal of a thyroid gland in which malignant disease of one sort or another was found purely by accident after removal for definite symptoms; on the other hand, surgical removal is never of ultimate benefit in malignant affections of the thyroid which can be definitely diagnosed previously to operation.

De Quervain[13] wisely refers to contraindications to thyroid surgery in general which "are drawn from the condition of the patient; diabetes, nephritis, arteriosclerosis, cardiac insufficiency, etc."

The mortality statistics must interest one to whom indications are unfolded. They differ greatly according to the type of the goiter, proving that one may well hesitate in advising surgery when the risk is great.

The following quotation is taken from the summary of an article by Mayo and Boothby[14] discussing the mortality rate following thyroid operations.

"At the Mayo Clinic, during the year 1922, there were nineteen deaths following 1,983 operations on 1,497 patients for diseases of the thyroid gland, giving an operative mortality

rate of 0.96 per cent. Such percentages, which are the common method of presenting statistics on goiter, not only fail to reveal the real truth, but conceal facts which, when brought out by a more detailed study, prove to be of great value. Statistics on surgery for goiter should be carefully and accurately analyzed, and the results presented for each disease on the basis of the number of cases.

"In this report all patients who died while under immediate observation in Rochester after surgical intervention on the thyroid gland during their present visit, are classified as having died from surgical procedures, regardless of the cause of death. The surgical mortality by case, according to Plummer's classification of thyroid diseases, is: adenomatous goiter without hyperthyroidism, 0.15, adenomatous goiter with hyperthyroidism, 3.48 per cent, and exophthalmic goiter, 1.99 per cent. The surgical mortality represents the combined work of eight surgeons."

This frank statement is of transcendent value as demonstrating that the mortality following goiter operations depends first of all upon the type of thyroid disease present in the given instance.

## References

[1]Ochsner, Edward H.: A Non-Operative Treatment of Goiter, Nebraska State Med. Jour., July, 1924, ix, 245.

[2]Pemberton, John DeJ.: The End-Results of Surgery of the Thyroid Gland, Arch. Surg., July, 1923, vii, 37.

[3]Guthrie, D.: What Type of Goiter Should Receive Medical Treatment? Atlanta Med. Jour., 1923, xxvi, 506. (Abst. Endocrinology, Sept.-Nov., 1923, vii, 883.)

[4]Sistrunk, W. E.: The Indications for Surgical Treatment in the Different Types of Goiter, Surg., Gynec. and Obst., October, 1921, xxxiii, 348.

[5]Cheever, David: Are There Reliable Criteria of Operability in Exophthalmic Goiter? Arch. Surg., January, 1921, ii, 21.

[6]Blackford, John M.: Thyrotoxicosis, Surg., Gynec. and Obst., February, 1922, xxxiv, 188.

[7]Tinker, Martin B.: The Desperate Risk Goiter, Jour. Am. Med. Assn., October 14, 1922, lxxix, 1291.

[8]Boothby, Walter M.: The Basal Metabolism Rate in Hyperthyroidism, Jour. Am. Med. Assn., July 23, 1921, lxxvii, 252.

[9]Goetsch, Emil: Studies on Disorders of the Thyroid Gland, Endocrinology, January, 1922, vi, 59.

[10]Lahey, Frank H., and Hamilton, Burton: Thyrocardiacs; Their Diagnostic Difficulties: Their Surgical Treatment, Surg., Gynec. and Obst., July, 1924, xxxix, 10.

[11]Mayo, C. H.: Personal communication.

[12]Crotti: Thyroid and Thymus, Lea and Febiger, 1918, p. 438.

[13]De Quervain: Goiter, Wm. Wood Co., 1924, p. 92.

[14]Mayo, C. H., and Boothby, Walter M.: The Mortality Rate Following Operations on the Thyroid Gland, Jour. Am. Med. Assn., March 31, 1923, lxxx, 891.

## CHAPTER VI

## CONSIDERATION OF THE PATIENT WHO NEEDS TWO OPERATIONS, ONE OF THEM BEING A THYROIDECTOMY

When confronted with a patient presenting two such surgical needs, we must, I think, ask ourselves three questions: (1) Shall the two operations be done at the same sitting? (2) If not, which is to be done first? (3) By what interval of time should they be separated?

It will be very generally admitted, I believe, that the *toxic* goiter patient should never be subjected to removal of thyroid tissue and to a second surgical procedure at the same time. The toxic patient never comes within the "preferred risk" class; indeed her resistance is in many instances, to some extent at least, an unknown quantity. I go still further, and question the advisability of ever undertaking at one sitting two major operations of which one is a thyroidectomy on even a nontoxic patient. A real risk to life can never be justified by (1) desire to satisfy a patient's whim or by (2) an economic consideration of any kind, probably the only two arguments ever advanced for combining the two procedures. If this line of reasoning be admitted for the bearer of a simple goiter, how true it must be for the patient who is toxic and a possible subject for widespread parenchymatous damage.

Suppose that the two operations are to be separated. Which shall be done first and by what interval shall they be separated? Here are questions which cannot be answered in a given way for all cases; in fact a number of recitals from my own clinical experience would justify the conclusion that only individual consideration of each patient enables one to proceed in a logical manner in the given instance. No other phase of this wide subject is likely to prove more attractive to the surgeon interested in seeing that his therapeutic measures exactly fit the patient's needs; this was our endeavor at least in the following twelve instances:

### 1. Adenoma Thyroid—Prolapse of Uterus

The need for careful discrimination when confronted by a large goiter and another surgical lesion in the same patient is very well illustrated by the case of Mrs. C., July, 1924. She had an enormous adenomyoma of the thyroid and a prolapse of the uterus when we saw her for the first time. Her chief subjective symptoms, it must be admitted, were of pelvic origin. In fact, she said that her large goiter had never worried her; she seemed to be almost unconscious of her most unusual appearance. However, she was a woman of sixty, somewhat anemic, with respiratory difficulty and with every evidence of the cardiac involvement described many years ago by Krause as typical of the adenomata (even though not toxic in the ordinary sense of the word), especially those which are to a considerable extent intrathoracic, as was hers. Measuring up the two conditions, we decided in this instance to treat first the one which contained a potential menace to life even though the other was the one for which the patient sought relief.

The wisdom of not having done both operations at the same sitting is illustrated by the fact that she showed two separate drug idiosyncrasies at the same time, both of them unknown to us before operation. A quarter grain of morphine was administered just before the thyroidectomy which was performed without special surgical difficulty in what we term a "dream state"; still artificial respiration had to be employed at intervals for about twelve hours after operation on account of a very typical morphine intoxication. The second complication of this nature was apparently caused by nine grains of luminal administered during the thirty-six hours which antedated the operation. At least I could account in no other way for the fact that three days elapsed after the operation before the patient was wide awake and fully rational, although heart, lungs, and kidneys functioned normally, with the exception of the first twelve hour period noted above. In view of these two drug complications I have a feeling that she could have tolerated very little more in the way of surgery; it was, therefore, considered wise to postpone the prolapse operation until a later period.

Three months later Mrs. C. wrote as follows:

"Day by day strength is gained and, sad to relate, weight

also. I am somewhat unstable on my feet and my eyesight is not normal. As yet I am unable to decide about the other operation. My abdominal trouble is bad, especially since the support [ring pessary] was removed."

It seems to me that our attitude toward a second operation on patients who have already been tested to the limit is best exemplified in the reply made to the letter just quoted:

"Please do not try to decide about your second operation until you have completely regained your strength and feel perfectly well, except in so far as the prolapse is concerned."

### 2. Adenoma Thyroid (Toxic)—Tuboovarian Abscess

Mrs. B. represents another type of patient in whom it was deemed advisable to remove the thyroid as a primary operation. Typical goiter symptoms—choking sensation, hoarseness, difficult breathing, pressure in throat, nervousness, palpitation, insomnia, loss of strength and weight, also headache—as well as physical examination, led to the diagnosis of adenomatous goiter. Mrs. B. also suffered from a pelvic lesion (specific double tuboovarian abscess) evidenced by profuse menstrual flow, much leucorrhea, and severe pain in the lower abdomen. On account of the pressure obstructive symptoms produced by the large thyroid (toxic adenomata) it was decided to remove the thyroid first, contemplating operation for the pelvic condition during the same hospital stay. She herself considered the goiter symptoms the more urgent, and I also felt that a general anesthesia for the pelvic operation would be dangerous before removal of her obstructing thyroid. Thyroidectomy was done on February 2, 1921. The pelvic operation done on the tenth of the same month was marked by great difficulty in taking ether—much mucus and something like spasm of the glottis although, fortunately, the goiter was out of the way. No doubt the anesthesia would have been smoother had we but waited until all effects of thyroidectomy trauma were some weeks past.

### 3. Adenoma Thyroid (Toxic)—Myoma Uteri

In the case of Mrs. S. (July 17, 1923), age thirty-seven, diagnosis was made of large uterine fibromyoma as well as of toxic adenomatous thyroid. While her attention had been par-

ticularly directed toward the abdominal tumor symptoms, enlargement of the abdomen, constipation, leucorrhea and loss of weight, symptoms of toxic goiter were actually more in evidence—extreme nervousness, palpitation, shortness of breath, choking sensation, edemas, and loss of strength. Primary hysterectomy was chosen as a result of careful analysis of the whole case, since neither lesion produced *local symptoms* and her general condition was fair, metabolic rate +35. She came, however, for hysterectomy, having been told at home that the tumor was causing her loss of weight and nervousness, and there is a distinct *psychic* value in the elimination of what the patient considers the cause of her condition. There were several other points in favor of the primary hysterectomy, however: (1) The tumor was so hard and finely irregular that we feared malignancy. (2) Rest in bed following hysterectomy might reasonably be taken as the best preparatory treatment for subsequent thyroidectomy. (3) Hysterectomy was considered a splendid test for her "reserve," always an unknown quantity to some extent in surgery of the toxic thyroid. She was sent home for further building up before goiter surgery should be considered.

### 4. Adenoma Thyroid (Toxic)—Hydrosalpinx

In the absence of vital indications often no one but the patient is in a position to decide which of the two lesions is to be treated first, since no one else can say which is most objectionable or disturbing. Mrs. K. (April 2, 1924) a very pretty young woman twenty-six years of age, entered our service with an enormous adenomatous goiter which was most unsightly and which produced the usual symptoms. She sought relief, however, from a pelvic condition that seemed to distress her more than the goiter on account of the enlargement of her abdomen, constipation, frequency of urination, and profuse menstrual flow. An enormous double hydrosalpinx was removed first, and eleven days later, when she had regained her equilibrium, a double thyroid resection was done. She consented to have her goiter removed, but I am convinced that a longer interval should have been allowed to elapse, because the combination of these two surgical experiences came very near to ending fatally. No doubt she should have been sent home to recuperate,

in which event the thyroidectomy would have been much better borne. After a somewhat lengthy convalescence she is now again in perfect health.

### 5. Colloid Goiter—Prolapse of Uterus

On December 21, 1923, Mrs. S. was operated upon for uterine prolapse which caused symptoms accounted by the patient much more important than those arising from the presence of a medium large simple goiter (colloid) with evidence of slight pressure. Since no vital indication was apparent in either field, her natural inclination was, of course, to have the pelvic work done first and then the goiter removed one week later. This routine was advised in view of the fact that the pelvic plastic involved a hospital stay of about two weeks, whereas she was shown that she would not be confined for more than one week after a thyroidectomy. It is apparent at a glance that the total period of convalescence must have been lengthened had it not been elected to make the two recoveries concurrent. Granting that major operations should be separated by a period of at least one week, such a patient is in the hospital either two or three weeks, according to the order in which the attacks take place, a matter of no little moment, it seems to me.

### 6. Adenoma Thyroid (Toxic)—Prolapse of Uterus

Mrs. D. (October, 1924) age thirty, consulted me because of constant tired feeling, nervousness, profuse menstruation, and a sense of uterine prolapse. Examination revealed an abnormal gall bladder and appendix, with a large, retrodisplaced, nodular uterus, slight cystocele, greatly relaxed pelvic floor, and cervix in the standing posture presenting at the vaginal orifice. The patient included in relating her symptoms, all those typical of goiter—nervousness, palpitation, shortness of breath and loss of weight and strength. An adenoma could be felt in the thyroid which caused slight pressure and choking. The pelvic condition was attended to first, as it had been causing the patient the more annoying symptoms, for, as she states, she would not have consulted a physician at all had it not been for the pelvic condition.

As in the previous case, rest in bed incident to convalescence

from the pelvic operation was planned as an aid in the preparation of the patient for thyroidectomy later. Her convalescence, however, was interrupted by what proved to be a bronchial pneumonia. Being the mother of four small children, she was sent home when well to complete a convalescence before anything should be done to the thyroid growth.

### 7. Exophthalmic Goiter—Gallstone Disease

Mrs. T. (October, 1921), suffering from nervousness, tachycardia, palpitation, loss of weight and strength, headache, shortness of breath, edema, was double ligated preparatory to thyroidectomy for exophthalmic goiter. She went home following the ligations, to return several months later much improved in every way, but with a marked jaundice but no gallstone symptoms. While she was in the hospital awaiting thyroid operation, she had an acute attack of gallstone disease which necessitated immediate operation. We felt it safer by far to drain the gall bladder than handle thyroid tissue in the presence of a jaundice of several months' standing.

### 8. Adenoma Thyroid—Postoperative Hernia

Mrs. W. entered our service complaining of pain in the abdomen, belching, abdominal distention, constipation, and general discomfort attributable to a postoperative hernia following gallstone operation. Nervousness, choking sensation, palpitation, and hoarseness, confirmed by physical examination, led to a diagnosis of toxic adenomatous thyroid. The hernia symptoms were so distressing to the patient and of such primary importance to her, that it was decided to correct the hernia with infiltration first and do the thyroidectomy at a later date.

### 9. Adenoma Thyroid—Postoperative Hernia

Mr. W. when first seen, presented a tumor of the thyroid and an incisional hernia in the gall bladder region. His gall bladder had been drained four years before we saw him, and for the past eight months he had been having attacks very similar to those which had led to the operation. He had a large incisional hernia and a simple adenomatous thyroid which seemed to be quiescent and causing only very mild pressure symptoms. In view of the importance of the abdominal manifestations we

elected to treat them first. We were unable to find a trace of his gall bladder. We explored his ducts and found no stones, then we closed the abdominal wall and made a graft of fascia lata over the entire weakened area. He did not pick up sufficiently to warrant a thyroid operation during this first hospital stay. We sent him home for several weeks after which he returned in splendid condition having gained considerable weight. The thyroid was then removed six weeks after the hernia operation. A smooth and uneventful convalescence followed.

### 10. Adenoma Thyroid—Gallstone Disease and Appendicitis

Mrs. H. made no complaint about her thyroid, but because she was sixty-two years of age, had lost much strength and an equal amount of weight, and had so limited her diet on account of nausea and vomiting that she was practically starving herself, we considered the abdominal lesion the more urgent of the two. There were no attacks of pain and the diagnosis of gallstone disease was, of course, problematic. The gall bladder, however, contained many stones as did also the appendix. Both were removed, and in view of an exceptionally smooth convalescence a bilateral thyroid resection was done thirteen days later, but apparently a longer interval should have elapsed although she did fairly well so long as she was living her protected life in the hospital; she went home in what we considered a fair condition. She did not remain there but five days, when she returned to the hospital completely exhausted and unable to take up the ordinary routine of life on account of too much surgery having been done within the limits of one hospital stay. I am glad to say that she ultimately recovered and resumed her customary duties of housewife.

### 11. Adenoma Thyroid (Toxic)—Appendicitis and Chronic Metritis

In the case of Mrs. B. the thyroid symptoms were decidedly more prominent than those of an abdominal nature; hence, practically the entire gland was removed and a rather slow convalescence resulted. This was deemed all that she could stand during one hospital stay in view of the fact that she had always been somewhat frail and none too good a surgical risk at any time. She was sent home but not allowed to remain long

enough. She became impatient at the end of four months and returned for the correction of her abdominal symptoms. They were severe enough under ordinary circumstances to have warranted operation, but in this instance we feel that we should have taken the patient's constitutional defects into consideration more fully than we did. We did a total hysterectomy and removed a markedly diseased appendix, something which is ordinarily well enough borne, but in this instance very nearly produced death. The blood pressure, which had been 118/70 before the operation, was 90/66 within twenty-four hours. Under ordinary circumstances the abdominal work would have been justified by her symptoms, but the immediate effects would have been less threatening had she been allowed a much longer convalescence after the first procedure. A strangulated hernia, a suppurative appendicitis, or a perforated pyloric ulcer would have justified any risk within the first year, but a relative operative indication surely did not in this instance.

An emergency alone justifies a second operation before a thyroidectomy patient has made complete recovery of normal health or at least registered a very marked gain. Disregard of this principle nearly caused the death of this patient.

### 12. Exophthalmic Goiter—Gallstone Disease

Mrs. G., aged fifty years, gives a history of presence of goiter, nervousness, exophthalmus, palpitation, shortness of breath, and loss of weight. Although these symptoms have been present for two years, they have been becoming more severe the last year, during which time the patient has lost forty pounds. There have been signs of vascular decompensation for the last six months, such as swelling of the ankles. The patient also gives a history of attacks of pain in the right upper quadrant, radiating around into the back between the scapulae, associated with jaundice, clay-colored stools, and dark-colored urine. These symptoms have been present for twelve years. Six months ago, she had a very severe attack of gallstone colic. Examination confirms the diagnosis of mixed type of exophthalmic and adenomatous goiter which shows all toxic findings and symptoms. Examination also reveals tenderness over gall bladder region and positive inhibition. In view of the fact

that the goiter is producing the more prominent symptoms and prejudicing the strength of the patient, I recommend the removal of the goiter and later correction of the gall bladder condition.

## Conclusions

This chapter opens with three questions which I have attempted to answer by case histories. They are:

1. Shall the two major operations be done at one sitting? *They were not in this series.*

2. What interval shall elapse between the two procedures? From one week to four months intervened in those patients who have experienced both.

3. Which operation shall take precedence? The reply to this question is not so simple. When a thyroidectomy is one of two major operations indicated, it is often most difficult to choose the one to be done first. Here, perhaps more than anywhere else, is the judgment of the surgeon required; it may be said in general, however, that the lesion producing the more urgent symptoms deserves to be treated primarily. So many arguments influence us in this choice that I may be pardoned a certain summary of them as they appeal to me at least. I do not expect every surgeon to agree with any arbitrary scheme in which an attempt to cover this subject is made. I shall merely endeavor now to deduce from my experience certain conditions under which it seems to me better to remove the thyroid first.

1. Do thyroidectomy first on a patient who seems greatly embarrassed by a goiter of unusually large size.

2. Always remove the thyroid before doing any other operation, provided it is producing the more marked symptoms.

3. Remove first a goiter which might by its presence interfere with an anesthesia needed for the performance of another operation.

4. A toxic goiter had usually better be removed first since this renders any patient a better risk for subsequent surgical procedure.

On the other hand, there seem to me distinct advantages in doing the other needed operation first in many patients:

1. The patient's resistance to surgery in general is tested in this manner before the thyroid is attacked.

2. A preliminary rest in bed is the best possible preparation for thyroidectomy.

3. Operation for malignant disease elsewhere in the body takes precedence, of course, over any other.

4. Conditions elsewhere threatening life demand immediate operation to the exclusion of every thyroid consideration.

5. The eradication of a source of focal infection by a surgical operation is the best preparation for a thyroidectomy.

6. Always do the other operation first when the lesion necessitating it produces the more urgent set of symptoms.

7. It is often well to do the other operation first if the patient *merely thinks* it produces the more urgent symptoms.

8. There is an economic reason for doing an abdominal operation before that on the thyroid if both are needed during the same hospital stay for the simple reason that a stay in bed after the former is required about twice as long as that following the latter.

It is often safer, however, to allow a very sick patient to go home to recuperate between the two procedures. This is a matter that must be given careful individual attention. While some patients do very well when both operations are done during one hospital stay, one of our patients, Mrs. H., reported as No. 10, almost died as a result of just this procedure.

The arguments set forth here tend only to emphasize the truth that it is impossible to lay down general rules as to which operation is to be done first. The evidence on both sides must be carefully weighed in each case and the best procedure for that case determined.

In order that nothing may be overlooked a routine general examination as thorough as in any other department of surgery is indicated in all thyroid patients. Very frequently a goiter patient is the subject of a second surgical lesion which demands attention even more urgently than does the goiter.

The *toxic* thyroid patient is certainly to be viewed as a generally sick person; in many instances heart, kidneys, central nervous system, or some other part of the body demands treatment (nonsurgical) even more urgently than does the goiter for the time being. This is another reason that clinical study is urged.

## CHAPTER VII

## PREPARATION OF THE PATIENT FOR THYROIDECTOMY

The preoperative reconstruction of a toxic goiter patient implies at least a grasp of the subject somewhat as follows:

Bram[1] points out that while simple goiter is merely a local disease, exophthalmic goiter, or Graves' disease, as he prefers to term it, is a constitutional disease, and the prophylaxis and the etiology, therefore, are very different. The whole chain of endocrine glands, as well as the nervous system, is affected in exophthalmic goiter, and Bram sounds a note of warning against the use of diagnostic tests that cause dormant symptoms to flare up or aggravate apparent symptoms. Bram feels the disease may be traced principally to inherited predisposing factors, such as endocrine and nervous system imbalance, and acquired predisposing factors, such as faulty hygiene, diet, falls, burns, and fright during infancy, the same things during childhood together with the added burdens of school life, impressions from companions and teachers, unhealthy home life and improper recreation, and during adolescence a continuation of these conditions with in many cases inappropriate preparation for adult tasks. During adolescence the development of the sexual instinct and improper guidance in sex matters plays a rôle in the etiology. In adult life the same factors act as predisposing causes with the added responsibilities that accompany maturity —harmful occupational, business or professional factors, overactivity, *inactivity,* neglect of diet and sleep, social, sexual, mental, and recreational errors. Under the third factor "exciting causes," Bram lists physical factors—focal infections, systemic infections, autointoxications, neoplasms, occupational causes, accidents—and mental factors, psychic trauma—occupational and economical conditions, social, sexual, intense emotional strain, acute fright, shock, etc., caused by accidents. The characteristic signs of Graves' disease are heightened cerebration, emotional instability, excitable heart and labile pulse, vaso-

motor ataxia, eyes brilliant and sparkling, and palpable thyroid gland. Patients suffering from Graves' disease seem particularly fond of the very foods that they should not eat—meats, coffee, and other stimulants, but these patients are usually undernourished. Although hunger is often present, it is appeased before sufficient food is eaten. So much for Graves' disease.

The toxic adenoma patient is often no better risk, with little to be done that is effective outside the field of the heart specialist. The *anatomical* picture in toxic goiter is by no means always clear cut. In some of our *clinically* outspoken exophthalmic goiters we are finding adenomata and cysts; particularly does this seem to be true of the larger tumors as, for instance, that of Mr. M. (April and May, 1924) in whose left lobe was a cyst the size of a large walnut. On the other hand, we rather frequently feel, after a superficial examination, that we are dealing with a toxic adenoma, but upon a more careful study we find thrills and bruits in the four cardinal thyroid arteries which we regard as early manifestations of a type not yet fully developed, but which would surely show all symptoms of exophthalmic goiter if allowed to go on to full fruition. The differential diagnosis is important since the two conditions are treated differently. In the rare instances which permit the diagnosis of the mixed condition of exophthalmic goiter and toxic adenoma, one plays safe by treating the patient as though the first named malady alone were present, but omitting iodine which seems to make an adenoma patient more toxic. By way of justifying a chapter on preparation, one may safely write that the patient's condition at the time she is brought to the operating table is an absolute measure of the success which may be expected to attend a competent operator's efforts directed toward toxic goiter.

The routine preparation for goiter cases will be considered in the following order.

1. Rest in bed.
    (a) Quiet spot (in bed)
    (b) No company
    (c) Selected nurse
    (d) Drugs (Barbital group)

2. Diet.
    (a) Low protein
    (b) High caloric
    (c) Forced fluids
        Mouth
        Rectum
        Nasal tube
        Skin
        Veins
    (d) No stimulants
3. Circulatory.
    (a) Digitalis
    (b) Tapping
    (c) Dry diet
    (d) Salt-free diet
4. Specific (exophthalmic type).
    (a) Lugol's solution
    (b) X-ray
    (c) Radium
5. Operative (exophthalmic type).
    (a) Injections
    (b) Cautery
    (c) Ligations

Exophthalmic goiter patients, if they do not die in one of their crises, tend spontaneously to temporary improvement. This has proved true under so many different circumstances that one is inclined to say that temporary improvement takes place with treatment, without treatment, or in spite of treatment. When operation with a view to permanent cure is contemplated, however, certain preparatory measures are required if the best results are to be expected.

### Rest in Bed

Crile[2] points out that of the 239 drugs and methods of treatment, each of which Marine has found is credited in the literature with the cure of hyperthyroidism, physiologic rest is the only method that all authorities agree is beneficial. He con-

siders only two other methods, both of which will be taken up later, as worthy of particular consideration—surgery and roentgen rays.

A **quiet spot,** whether treatment is carried out in the hospital or in the home, is essential for complete rest, which is one of the greatest factors in the preparation of the toxic goiter patient for thyroidectomy. Wards and rooms to be occupied by toxic goiter patients should preferably be located on an upper floor, at least above the second floor, away from street noises, as well as away from x-ray and operating rooms and obstetric, pediatric, and psychiatric wards. They should be situated in a section of the building where the circulation of air is good, and they should be made as pleasant and restful as possible. These patients, on account of their high oxygen requirement occasioned by increased metabolic rate, are exceedingly sensitive to lack of ventilation. They become restless, sweat, and even show nausea as a consequence of deficiency of oxygen in a room in which its lack would hardly be noticed by a normal individual.

In the wards screens placed between the beds, at least at intervals, will afford a great sense of peace, and will encourage the patient to relax and perhaps sleep rather than talk to her neighbor. Such little services can be diplomatically planned by the tactful, observant nurse, without creating any ill will.

**Visitors** often present a serious problem. Interested relatives and friends, and sometimes uninterested ones who have a fondness for visiting people in need of rest, must be tactfully dealt with, and the simplest scheme is the sign on the door "No Visitors." This conserves a great deal of energy for doctors, nurses, and the patient's family.

Hertzler[3] feels that practically no more preliminary treatment than is given the average surgical patient is required by the nontoxic goiter patient, but that quite the contrary is true of the toxic patient. Rest as complete as possible (mental and physical) is far the most important feature. The cause of apprehension, distrust, and worry must be sought and eliminated if possible. The patient who has been forced into the hospital by relatives or friends is particularly intractable so far as mental reasoning is concerned. These patients have a type of neurosis which may develop into a mild mania. Initial fear of the hos-

pital upon entry may account for much of this agitation which can be overcome by kindness and patience on the part of the doctors and nurses, coupled with firmness however, but never scolding or abuse. A comfortable room, with things to the patient's liking, is to be recommended, indiscrete relatives and friends excluded. Carefully chosen visitors are frequently helpful if they are properly coached and do not stay too long. Continued rest in bed does not suit every type of patient; some keep much more quiet if they sit up in bed part of the time; others are less restless if they are allowed occasionally to sit out in a chair; many are too sick, however, to get up at all. In any event the patient should be cautioned against sudden movements at all times. Most patients, Hertzler believes, will take the required amount of rest if tactfully managed. An occasional patient cannot be controlled at all, and will be worse after weeks of restraint. Such are likely to finally blow up with acute hyperthyroidism and die.

The **nurse** plays a definite part in the preparation of the toxic goiter patient. She should be the type of woman who has a quiet, soothing, winning personality, who reassures the sufferer, and by her kindly smile and little attentions proves to the patient more than by words that she has his or her good at heart. Despite the feeling often expressed to the contrary, women look up with respect and confidence to other women who show poise, intelligence and skill, and men will brace up in spite of their fears under the encouragement and assurance of a sincere, sympathetic woman. The ideal nurse will study the temperament of her charge, and after handling a number of goiter cases she will be able to anticipate not only most of the patient's needs, but, even more appreciated by the neurotic individual, her likes and dislikes. Never should a nurse engage the patient in argument; rather should she seek to know the patient's hobby, for in ill or in good health, we are encouraged and made happier by a few words on the subject in which we are most interested. She should put into practice her knowledge of the various procedures that will help to quiet the restless or sleepless patient, such as brushing and rebraiding the patient's hair, and giving a warm sponge bath. A glass of warm milk will tend to induce sleep.

It is sometimes necessary to present unique and varied arguments to convince a toxic patient of the need for prolonged preoperative treatment instead of the immediate operation, which is so dangerous to such individuals. The wisdom of the more conservative course seems to have appealed to most of them since one of my interns invented the following homely simile: "Now compare yourself to a red-hot stove. Surely no sane person attempts alterations upon one until it has slowly cooled down to the point where it can be handled in the ordinary manner." This plain statement from a youth who is discerning beyond his years might with profit be adopted by the medical world in contemplating the need of the thyrotoxic patient. Such simple philosophy is rarely lost on one who may by virtue of heredity, environment, or disease be incapable of grasping reasoning of a more abstruse nature. Once the cooperation of these exceedingly sensitive patients is secured, a long step forward has been taken in the building-up process which must antedate every successful thyroidectomy.

That individualization is called for in each case and that hard and fast rules cannot be laid down is well illustrated in the case of Mr. S. (July, 1924), aged sixty-three years, who, because of a mental peculiarity, would not stay in bed. He understood all that was said to him about his broken compensation, seemed interested and inclined to cooperate, then the moment he was alone in the room, he would immediately get out of bed. He was in no wise embarrassed when caught disobeying orders, made no attempt at defense or explanation, but merely returned to bed when told to do so, then repeated the performance as soon as his nurse turned her back. Many toxic patients so disposed have shown a certain degree of cunning in their disobedience of orders obviously understood to be for their own good at a period when the fear of death was constantly expressed, enough one might think to prevent any recklessness in their disregard to conserve the slight physical resources left to them. A mental imbalance thus expressed seems to characterize this malady. In this case we finally had to compromise when the patient completely lost his appetite. He told us that he would eat if we would allow him to sit up. We let him sit

up and eat with his tray on his knees, and he never tried to get up again except on two occasions when he fell out of bed under the influence of veronal. It is well to place such a patient (if there is no diarrhea or vomiting) in a two-bed room with some good-humored companion who is making a good recovery.

In any event, one must have complete control over, and full cooperation of, the sick thyroid patient, or no proper preparation is possible. It is infinitely better to lose the patient's patronage before operation than have the patient lose his life after operation.

**Sedatives** are almost indispensable in the treatment of some goiter (toxic) patients; they must be employed, however, with a certain degree of caution until the tolerance of the individual is known. This note of warning is sounded in consequence of a most impressive series of near-tragedies known to me, most of them real surprises, and all of them avoidable. The more I use this class of drugs, the more I am convinced that the degree of tolerance to them is a highly individual matter, and we must as a matter of course individualize in their use. I am coming more and more to employ the barbituric acid compounds. At present I use luminal in 1-½ grain doses to the practical exclusion of every other sedative. I begin with a dose every eight hours, and shorten the period to six hours in case the patient does not remain perfectly quiet. I have had in some instances to give it as often as every four hours, although this not for any protracted period.

Two grains of veronal every two hours, as suggested to me by Frank R. Fry as an excellent and safe means of administering this drug, in most instances will give uniform control of the patient. Its use in this manner is reasonably safe. I have not used veronal in recent times, for while it was ideal for certain patients, all sorts of minor complaints were registered following its use. Many complained of nausea and vomiting; others were made exceedingly dizzy by it. A few became almost maniacal, and so many fell out of bed after losing their balance when reaching for some near-by object, that we finally practiced restraint on every patient to whom it was given.

In many instances it will be found possible to augment the

action of sedative drugs by the use of soothing applications or ice bags. An ice bag may be used to advantage in three situations: on the head where headache is the predominating symtom; on the neck in highly toxic individuals because it is supposed to somewhat limit thyroid secretion; and on the precordial area where rapid pulse and palpitation play a dominant rôle. Frequently throbbing in the gland, the result of palpitation, can be ameliorated by ice bags placed over the gland and over the heart. Caution must be exercised, however, in their use. There are patients in whom one must be on guard against chilling the chest wall too much for fear of producing pneumonia. It is well to remove the bag every third hour or at the outside every fourth hour. I know of one instance in which widespread skin necrosis followed continued use over an abdominal area.

### Diet

Consideration of the diet in the treatment of exophthalmic goiter is of vital importance. One of the most prominent symptoms of toxic goiter is the increase in basal metabolism rate; in other words, body tissue, as well as food, is more quickly oxidized, with the result that the body is constantly being torn down instead of being built up. In order not only to compensate for the loss by rapid oxidation but to build up the wasted body and restore the individual to normal weight, it is necessary to feed the hyperthyroid patient a very high caloric diet. In fact a diet sufficient for a laboring man is required for the patient at rest, 3,000 to 4,000 calories, or even higher, according to the judgment of the physician.

Principally because of the menaced condition of the kidneys, and the strain thrown upon the kidneys by red meats, a low-protein diet is followed. Milk and eggs are not contraindicated; in fact in various forms they can be given as extra nourishment between meals—eggnog (without whiskey), white of egg beaten in orange juice, etc.

(Many patients vomit thin yellow fluid only early in the morning, but retain nourishment all day; appetite, however, is always deficient in the class of patients who vomit, and special effort must be exerted to serve tempting foods.)

Following is the routine goiter diet used in our clinic:

### Routine Goiter Diet (High Caloric—Low Protein)

*Foods not allowed:*

A. Red meats, i.e., beef, mutton, lamb, pork (bacon excepted) sweetbreads, brains.
B. Tea, coffee.
C. Spices, ginger, mustard, pepper, cloves, etc., pepper sauces, catsup, horseradish, etc.

*Foods allowed:*

Salt in moderation.
Proteins: eggs, cream cheese, chicken, bacon and fish in moderation.
Soups: cream vegetable soups, made with 15 per cent cream, chicken broth with rice and cream.
Vegetables: all vegetables with cream and butter sauces.
All cereals with cream and sugar.
Salads, fruit and vegetable salads with whipped cream and oil dressings.
Light puddings, gelatins, custards, jellies, corn starches, whips, light cakes.
Jellies, preserves.
All fruits.
High caloric ice creams and ices.
High caloric malted milks.
Lactose with fruit juices.
Fermillac, whole milk, cream.

**Forced Fluids.**—It is essential that a patient receive approximately 3,000 c.c. of fluid every twenty-four hours. The best plan of administration is the simplest possible procedure, the one nearest the way nature intended the fluid should be taken. Quite obviously the first choice is by mouth. One glass taken every hour while awake will supply the patient's requirement in most instances. Frequently the objection to drinking so much can be overcome by a logical explanation of its benefit. Most of our patients deserve to be treated as intelligent human beings, even if they do have goiters and show nervous symptoms. The drink may be varied from plain water to break the monotony. Cocoa, milk, and fruit juices supply fluid as well as additional nourishment, so essential in the thyroid patient. In this connection Hertzler[4] recommends lemonade containing 50 grams of lactose to the glassful, given between meals, thus giving, in addition to the fluid, 200 calories per glass. Lactose in hot peppermint water is also suggested. Hertzler feels that this is the best prophylactic treatment of postoperative acidosis. There are instances in which fluids cannot be retained when taken by mouth, or in which, on account of the mental attitude of the patient, they are absolutely refused. In such cases as

much fluid as possible is to be given by mouth and the remainder of the requirement by some other method.

As nearly all of the absorption of fluids taken by mouth is accomplished in the bowel, the next procedure in order of simplicity is rectal administration, in the form of 5 per cent glucose enemas, 750 c.c. or a quart at a time, allowing an hour for its introduction. This procedure may be repeated every eight hours should the patient be unable to take sufficient fluid by mouth after the preceding proctoclysis.

Should the bowel become irritated and fail to absorb the glucose solution, returning nearly the full amount shortly after its administration, an equivalent of the amount not retained may be administered by hypodermoclysis (under the skin) as $\frac{1}{16}$ per cent novocaine solution.[5]

All of these methods failing, as a last resort, 10 per cent glucose solution in amounts of 500 c.c. may be slowly introduced directly into the veins. This procedure is seldom necessary, as in nearly all cases 3,000 c.c. can be given by one or a combination of the other three methods.

Frequently we have to deal with the problem of feeding the unconscious patient who cannot be given food by mouth or with individuals who for some mental reason refuse food. In these cases fluids rich in carbohydrates can be introduced into the stomach by way of the nasal tube. Seven hundred fifty c.c. of nourishing food can be given by this route every six or eight hours.

A very toxic patient is frequently dehydrated (sweating, vomiting, purging) and suffering from starvation acidosis as well. Miss W., September, 1921, was in the most extreme condition, in fact she had to be fed through a permanent duodenal tube (carbohydrates) to say nothing of hypodermoclysis, to the end that she could be double ligated and sent home after a few weeks.

All stimulants are contraindicated in goiter cases, because the system is already too highly stimulated. Positively no alcohol, tea, coffee, or tobacco is to be allowed. Men who are constant smokers would suffer severe nervous strain if tobacco were taken from them suddenly; in such cases the amount must

be limited and the patient allowed to adjust himself to its gradual removal.

### Circulation

The routine use of digitalis in toxic patients prior to operation is no longer employed in our clinic. There is no evidence that digitalis is of value in toxic patients unless there are certain indications for its use, such as auricular fibrillation or edema. Plummer and others are of the opinion that digitalis may be actually harmful to toxic patients in whom there are no evidences of congestive heart failure or auricular fibrillation.

For the treatment of goiter patients with auricular fibrillation, congestive heart failure, or exhaustion of the heart muscle, the reader is referred to the chapter on Goiter Heart.

Occasionally a patient comes in with such a high degree of cardiac decompensation that respiration is embarrassed, and the cardiac activity as well, by transudates in serous cavities. I have seen immediate rapid improvement through withdrawal of fluid from the abdomen and chest. In very few instances I have scarified the ankles in cases in which edema was excessive.

Dry, salt-free diet is to be employed in cases of extreme cardiac decompensation where an excess of fluid and edema is found throughout the tissues. All fluids are to be limited to the minimum necessary to avoid agonizing thirst. This is a radical measure and must be limited to selected cases where it is specifically indicated, as the usual routine and good practice in toxic goiter cases is a diet including great quantities of fluids.

### Specific (Exophthalmic)

Drs. Henry S. Plummer and Walter M. Boothby[6] of the Mayo Clinic feel that until 1923 no drug was available which was known to influence materially the natural course of exophthalmic goiter, or one the administration of which could be expected to avert impending death. These writers have found the improvement of their inoperable exophthalmic patients so great as a result of treatment with **Lugol's solution** that they have later been accepted by the surgeons as operative risks. The surgical mortality rate of these originally bad cases and the frequency of typical postoperative hyperthyroid reaction leading to death have continued to decrease.

Dr. Tate Mason read a paper at the Southern Surgical Association in December, 1925, from which I quote one of the most direct and definite confirmations that any one has presented of the value of Lugol's solution in exophthalmic goiter.

"In July, 1925, a patient with exophthalmic goiter presented himself to the clinic; we considered him just on the verge of crisis,—a very extreme case. After a few days' treatment with Lugol's solution he became much better, but was dissatisfied with his surroundings, and demanded that something be done without a prolonged stay in the hospital. Feeling that

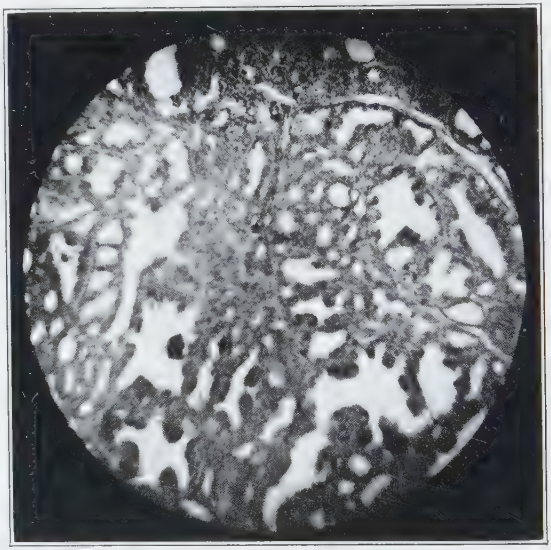

Fig. 8.—Exophthalmic goiter; high columnar epithelium, papillary projections, and very little colloid. Before iodine therapy. Low power.

it would be best for the patient, with his mental attitude, to act, we ligated one pole. At this ligation a small piece of thyroid about one-half centimeter in diameter was removed. Under the microscope this piece presented the picture typical of exophthalmic goiter (Fig. 8). This patient was then kept in bed for six weeks with forced feeding and large doses of Lugol's solution. At that time he had developed an iodine rash. His mental condition was clear, and there was marked diminution of his hyperthyroidism. A partial thyroidectomy was done. The microscope showed large acini filled with colloid material (Fig. 9), and instead of columnar epithelium lining the walls, cuboidal

was found, and very little hyperplasia. In other words, microscopically we were looking at a colloid goiter, and not at a hyperplasia, such as had been present in the same gland six weeks earlier. This change in the thyroid gland seen after prolonged iodine administration is the same involution described by Cattell."

I make use of Lugol's solution in spite of the fact that it has not in *every* instance, so far as my powers of observation go, given the same brilliant results which it has in the hands of

Fig. 9.—Same gland as in Fig. 8, but after iodine therapy for six weeks. Colloid goiter with low columnar epithelium and increased colloid. Low power.

those who have popularized it at the Mayo Clinic. Possibly this is because a very large number of our patients here belong to a mixed type where many small adenomata are found scattered through a gland in which hyperplasia is supposed to be the anatomical fundament underlying the predominating symptoms of exophthalmic goiter. If it were of no benefit I should, however, continue to use it for two reasons: In the first place,

it is expected by the patients and their physicians. Second, because of my unbounded confidence in Plummer and his coworkers in Rochester, who have made so many contributions of undoubted value to surgical progress, I feel it would ill become me to deny my patients any remedy which they endorse so heartily.

Many of our patients on whom it has been employed have not been merely thyrotoxic with a high metabolic rate, but have had every evidence of cardiac decompensation, parenchymatous damage to kidneys and other organs, to say nothing of central nervous derangement. In other words, we have been dealing with exceedingly sick persons, viewing the individual as a whole, and perhaps we have expected too much of Lugol's solution, and my estimate of its efficiency may not be quite fair.

My plan of administration of Lugol's solution is as follows: 10 drops the first day, 20 drops the second day, increasing the dose 10 drops each day, running up to 100 drops by the tenth day; operation is performed four days after the maximum benefit is observed, as suggested by Pemberton.

A few persons are made distinctly worse by its use, probably because of the fact that tiny adenomata are scattered throughout their hyperplastic thyroids. The use of Lugol's solution in exophthalmic goiter is based quite logically upon Kendall's discovery that iodine is deficient in hyperplasia of the thyroid. Its use will *rapidly decrease the metabolic rate,* but can we expect clinical miracles where degenerations of parenchymatous organs have taken place?

Hyman and Kessel,[7] of New York, instituted an interesting study of fifty unselected, fully developed exophthalmic goiter cases in which they employed no specific therapeutic measures "in order to determine the natural history (spontaneous course) of the disease" and to establish an "index for the evaluation of therapeutic procedures." The patients were observed in the general ward of a hospital, where an attempt was made to give them complete physical and mental rest. They were placed on a high caloric diet (3,000 calories), and wet packs were applied daily at a temperature of 75°. Daily colon irrigations employed in the beginning were later discontinued. Focal infections were eradicated. The only medication employed was

the administration of 1-1.2 grains of luminal as a hypnotic and syrup of ferrous iodide, 5 to 30 minims three times a day, to hasten involution of the thyroid. No particular psychotherapy was employed, save that an effort was made to protect them from psychic shock and to aid in the solution of their social and economic problems. They were sent to the country after a hospital stay of about six weeks. The results of this experiment lead the writers to conclude that the exophthalmic goiter patient under this routine exhibits a marked tendency toward spontaneous recovery, and that "skilful neglect" compares favorably with specific therapeutic measures. They employed iodine in many instances after the first six weeks "studied neglect" of these thyroid patients and found that while improvement continued for the seventh and succeeding weeks, it was at no time so rapid as it had been during the spontaneous recovery which marked the early weeks in bed without any medication.

**Electric treatment** in any form, if not too vigorous, seems to soothe a patient temporarily at least. In many it will have a psychic effect and there is no patient above wanting to feel that his doctors and nurses are extending every effort in his behalf.

I have not felt that **x-ray** is particularly helpful in toxic adenoma, and in our clinic these patients are not ordinarily subjected to its influence, but we do employ it as a part of the preparation in exophthalmic goiters where ligation is deemed too serious a procedure to be employed with safety.

Grier[8] advocates the use of **radium** or **x-rays** in the treatment of goiter with hyperthyroidism, but feels that in goiter without hyperthyroidism it is contraindicated. He believes a mild dosage of irradiation should be administered once a week, one lobe at a sitting. He does not treat the isthmus. One-half a skin erythema dose is given over each lateral area at each sitting and a free period of two weeks is allowed to intervene, when the treatment is repeated. The x-ray penetration is equal to a 9 inch parallel gap, filtered through 6 mm. of aluminum. He uses only the gamma rays of radium, the radium being placed 1 inch from the skin. The thymus area is not routinely exposed unless there is evidence that the thyroid reaches down into the chest or that the thymus is enlarged.

I have never been absolutely sure of the efficacy of x-ray treatment. I am sure of this, however, it does please the patients. They see at least that something is being done for them and a psychic influence is not to be despised in this connection. It accustoms the patient to being handled and to making trips to the operating floor. Another point not to be ignored in this plan is that the upset possible after x-ray treatment may warn one against the advisability of more radical procedures that might otherwise be attempted.

Richardson[9] in discussing the relative value of surgery and the x-ray in the treatment of hyperthyroidism feels that the improvement coincident with the use of the x-ray is too sudden and striking to be regarded as accidental. In some cases the results achieved through this agency have been as brilliant as those of any other method. The occurrence of myxedema following roentgen ray treatment is given as one of the objections to its use. Several patients developed myxedema following x-ray treatment at the Massachusetts General Hospital, from which clinic Richardson has drawn his conclusions, two within four months, one eighteen months after, and another five years after, but it is uncertain whether there was really any connection between the two. Increased difficulty of operation is held forth as another objection. Richardson, however, has noted no appreciable difference in cases operated upon at the Massachusetts General Hospital after x-ray treatment in their own laboratory. He has noted a somewhat firmer consistency of the gland with possibly increased fixation posteriorly, but he feels that operative difficulties following x-ray treatment are no greater than those following preliminary ligation.

McGuire,[10] on the other hand, points out the disadvantages of the use of x-ray in goiter treatment—increased length of invalidism, operative difficulty if surgery is later required, tissue shrinkage, probable production of myxedema, burns, and the complete failure to benefit colloid and cystic goiters.

I have had no experience in the preparatory treatment of exophthalmic goiter with radium, but I see no reason to disagree with those who have noted benefit from its use. It occurred to Terry[11] that radium emanations might be used to advantage in bad risk cases of exophthalmic goiter. He intro-

duced eight tubes of radium emanations, representing ten millicuries, into the substance of the thyroid gland in an extreme case on August 16, 1920, and subsequently employed the same procedure in ten more cases. Four of the eleven patients showed sufficient improvement after four to ten weeks for partial lobectomies. The other seven patients at the time of the report were still under observation, but had shown improvement. Terry does not feel that radium treatment will supplant ligations, but he believes it offers a lessened risk. Terry's[12] conclusions at a later date (July, 1922) are that the radium tubes can be introduced into the gland substance, that the amount of emanations and number of tubes should vary with the size of the goiter and the intensity of the symptoms—"from 4 to 10 millicuries contained in six to eight tubes." He feels that the emanations are valuable in the preparation of the bad surgical risk, but that they should not be used in adenomatous goiter cases.

### Operative (Exophthalmic)

Each one of the various preparatory treatments, x-ray, hot water injections, ligation, etc., has benefited some patients, though the effect of none but ligation is constant. In refractory cases it is well to combine most or all of them until an effect is produced, beginning with the least dangerous and stepping the patient up until all have been employed.

**Injection of various chemicals** into the thyroid has been entirely given up on account of the many bad results which have followed their use, but the subject gained a new impetus in some quarters when Porter advocated the use of boiling water injections. Opinions regarding the safety and efficacy of the procedure vary.

McGuire[13] feels that the injection of boiling water or a solution of quinine and urea into the thyroid to diminish the thyroid secretion by destruction of cells and obstruction of blood supply is to be used very cautiously because of its disadvantages. He believes that this procedure may in very sick persons set up an acute or fatal hyperthyroidism, while in other cases no benefit will be derived, and the adhesions caused by the treatment will render subsequent surgical procedures very

difficult. He feels that the irritation caused by the injection may eventually lead to malignancy.

My technic for injecting the thyroid with boiling fluid was suggested by the observation that patients suffered very acutely for an hour or two after the introduction of boiling water. It was rather obvious that one interested in local anesthesia should substitute boiling 1 per cent novocaine and thereby afford an absolute guarantee against the period of distress just mentioned. But I go much further than this in trying to rob the ordeal of all its many unpleasant and painful details by proceeding as follows: A whiff of gas is administered to cover the pain of introducing a needle so large and short that the fluid will not cool off unduly by slowing the passage through it. To it is attached a filled Luer glass syringe (10 c.c.) just taken with its contents from a basin of boiling water, being handled with two pairs of gloves. The position of the needle point is changed once or twice while making the injection as taught by Porter.[14] Then after its withdrawal an ice collar is clapped on the neck, the curtains are drawn, and a fourth grain of morphine is administered. Before the patient awakens the novocaine has taken full effect, and in turn the morphine exerts its general influence long before the local anesthesia has worn off. The maneuvers take much less time than it takes to read about them. That they are efficacious is proved by the observation that no patient manifests dread of a second injection when it is proposed.

Boiling 1 per cent novocaine injections in addition to x-ray and ligations have made it almost impossible to remove the thyroid gland within the period of a few months' improvement following this preliminary treatment in exophthalmic patients considered too ill for primary resection. Miss E. (January 22, 1924) returned with a perithyroiditis (three months after injection, five months after ligation) so extensive that the peripheral portion of the lobe could not be removed at all; the major central part of it was torn out, however, and clamps were left on, the defect about them being tightly packed. Ligation scars and those from x-ray are slightly embarrassing, but injections shall in my future experience be reserved for those difficult cases in which the patient does not make satisfactory improvement after ligation, x-ray treatment, and the employ-

ment of other well-known methods used in preparation for thyroidectomy. Under exceptional circumstances I might use the injection in a second class of patients, although I have not done so—those who positively refuse to improve sufficiently in the hospital to seem safe for ligation.

If the injection is used at all, it should be limited to one lobe at a time as demonstrated by a recent unpleasant experience. Mr. W. (July, 1924) had 10 c.c. injected into both lobes at one sitting with early onset of the following distressing symptoms which persisted for about ten days: general edema of the neck with extreme tenderness, temperature rise to between 102 and 103 degrees, hoarseness, partial paralysis of left vocal cord and difficulty in swallowing. Meantime the patient felt fairly well generally speaking, thus distinguishing irritative and chemical thyroiditis and perithyroiditis from similar lesions of infective nature. Under local treatment with ice and glycerin packs the local manifestations gradually subsided.

The **cautery** is rarely used; in fact, it is employed only where ligation has been missed. I have retracted edges of the tiny ligation incision, and thrust the cautery directly into thyroid tissue. Patients have improved, still I am somewhat uncertain as to the efficacy of the cautery; and it has made bad looking scars and will probably not be used again in our clinic, although favorable results seem to have followed its use in the hands of one or two well-known surgeons.

**Ligation en masse** of the structures entering the upper pole is commonly regarded as the most effective surgical measure ever employed in the preparation of an exophthalmic goiter patient for resection, though it seems to be of no value in the toxic adenomata and is thought by C. H. Mayo[15] to be harmful. There is every clinical evidence of its value in very toxic patients to say nothing of the laboratory confirmation gained by recording an almost uniform lowering of the metabolic rate in consequence of long series of such minor operations at the Mayo and other large clinics. It would be difficult for any one to prove just how this is accomplished; of course we interrupt the activity of the superior thyroid artery and vein, and also the sympathetic nerves said to enter the upper pole as well as the lymphatics which leave it. Mastin[16] showed the interference of blood supply

to be transient, hence of minor importance. As to the other factors involved, probably very little is accurately known.

Ligation of the inferior arteries seems to have very few advocates and seems to me at least to be a much more difficult and dangerous procedure when the condition of these patients is considered. The blood supply of the parathyroids comes wholly from branches of these vessels, which surely is an argument against preferring them for ligation though admitting a rich anastomotic arrangement. They labor under the further disadvantage, it is said, of having no accompanying secretory nerves and lymphatics, hence the less promise in ligating them. To avoid repetition here, the reader is referred to the special chapter on Ligations, page 122, for a technical consideration of the subject as well as for illuminating clinical examples of what has been accomplished by its employment in our clinic, although we are using it less and less frequently in patients who are not severely ill. We now realize that those patients who might profit by it will in the course of a longer time, if not ligated, reach a *free interval* which is hastened by the use of Lugol's solution. Where there has been not much loss of weight, we now devote our energies toward perfecting a technic of nonoperative preliminary care extended over a period long enough that the patient can safely undergo thyroidectomy during one hospital stay.

**Eradication of foci of infection** is to be considered in the preparation for thyroidectomy. Correction of infected teeth, tonsils, gall bladder, or appendix will in some instances greatly improve the toxic condition and render the patient a better operative risk, although in general it may be said that these patients are far too sick for any such preliminary treatment. The matter should always be considered, but in my experience it has usually seemed more practical to first attempt the restoration of thyroid equilibrium and then make these other foci the subjects of very remote postoperative treatment.

A number of patients have responded well to treatment for focal infection. Dr. N's eighteen-year-old daughter (January 24, 1921) came to the office with symptoms of (1) mildly toxic adenoma and deflected trachea, (2) enormous tonsils, (3) chronic nephritis. She had just recovered from a tonsil attack.

Interference with respiration is the leading goiter symptom. Preparation here consists of getting her well over the tonsil attack while treating the kidneys in the hospital, and possibly removal of the infected tonsils first if the thyroid obstruction permits.

Another patient was sent to our clinic from a small country town. Upon examination, in addition to a markedly enlarged thyroid gland, we found toxic symptoms which in part could be accounted for by enormous jagged tonsils, meeting in the midline, from which a great amount of pus could be expressed on light pressure. Tonsillectomy was done which relieved the patient's condition materially and made her a better risk for thyroidectomy.

A case in point is one which Evarts A. Graham related to me from his own clinical experience. A young woman who had a benign goiter suddenly became afflicted with all the clinical manifestations of thyrotoxicosis. Fortunately the attention of those in charge of her became fixed upon an acutely infected tooth socket. As soon as her febrile symptoms had subsided, the offending tooth was extracted with the liberation of considerable pus, whereupon the thyrotoxic symptoms instantly subsided as far as that crisis was concerned.

Mrs. W. (Spring, 1921) had marked suppuration around all of her teeth while presenting all the toxic symptoms of exophthalmic goiter. She was hardly well enough for ligation, so after a prolonged rest, all of her teeth were extracted. She improved so markedly that two ligations of superior thyroid poles could be done successfully.

Preparation of the patient must be continued and absolutely no operative procedures undertaken in the presence of

1. Mental derangement.
2. Loss of weight.
3. Extreme restlessness.
4. Cardiac decompensation.
5. Metabolic rate very high.
6. Vomiting.
7. Diarrhea.

Practically every exophthalmic patient will go over into an interval if properly treated long enough.

I have seen so many patients suddenly grow worse on entering the hospital for preliminary treatment that possibly it were better carried out elsewhere in these few. In the minds of many people a hospital is merely a house of torture, and instead of feeling that it is a haven of rest where their every need is anticipated and little attentions are bestowed upon them by a corps of well-trained, sympathetic men and women, it is either chosen by them or forced upon them as a last resort. This attitude borders on morbidity in some cases. Mr. B. (September, 1920), a man forty years of age, showed extreme fear upon entry, while another patient, Mr. L., a young man of twenty-eight, formerly in the army service, developed an acute mania as a result of hospital fright.

The abnormal mental attitude of the toxic thyroid patient to surroundings affords an interesting study and must be given due consideration. An interesting example follows: A small private room is maintained off the large ward in which patients are placed whenever they become so noisy as to annoy the other patients or when they become so ill that other patients annoy them. This is done without extra expense to the individual and has almost always been gratefully accepted. As a matter of fact, the mortality in this room is higher than in the ward because the worst patients are placed there, although the attention of physicians and patients has never been focused on that point. Frequently, however, patients observe such things and many times allow the imagination to override the better judgment. Mrs. M. (October, 1924) during a lengthy hospital treatment occupied at all times the same bed in the large ward. Then, after a ligation she awoke to find herself in the small private room. She had been placed there merely because the room was temporarily without an occupant and we considered in view of her many trying experiences that she was, perhaps, entitled to all protection that we could give her. When she recognized her surroundings, she became panicky and begged to be put back into her old bed. We immediately sensed the reason and gratified her request, whereupon she fell asleep. While she was asleep, her sorrowing relatives gathered around her bed, and, when

ordered to depart, told us that they had assembled with the intention of paying their last respects as soon as they had learned that she had been placed in the "death chamber," as *she* termed it.

This is a typical illustration of the abnormal mental attitude of the thyroid patient towards surroundings which have been gratefully accepted by all other inmates. The fears of this type of patient must be anticipated by sane explanations of procedures.

It must be remembered that the thyroid patient is mentally ill as well as physically ill, that the nervous system and brain centers have been the victims of the toxicity produced by the hyperactive gland, and that he is far more given to exaggeration of details than the average surgical patient. What is merely daily hospital routine to the surgeon is a mysterious nightmare to the patient who through lack of experience thinks of each procedure as a most terrifying ordeal, even to the prick of the hypodermic needle.

One of our patients claimed an emergency case across the hall kept him from sleeping; then he worried about the squeaking of a rocking chair in his room, became really very nervous over it; finally he complained that the coupling pins in the bed were too loose and that he felt as though he were constantly rocking as in a boat, and he expressed great fear of falling from the bed.

The toxic exophthalmic cases I have seen with marked mental abberations have as a rule given a bad prognosis. Mrs. K. (January, 1921), suffering with some sort of depressive psychosis, though seemingly holding her own physically, died a few days after I saw her and refused to operate largely on account of her mental state.

**Management of the Patient after Leaving the Hospital.** Improvement of the toxic goiter patient during the interval between leaving the hospital after preliminary preparation and entry for thyroidectomy depends largely upon the patient's environment, her ability to adapt herself to her surroundings, intelligent interpretation of instructions given her upon leaving the hospital, and sane cooperation of relatives and friends. I

have had these patients go home and fail to improve and I have not known why until I have visited the home.

To obtain best results those in charge of the patient during this interval must put forth every effort to make her physically as comfortable and mentally as free from worry and anxiety as possible. Improper sanitary surroundings, poor heating in winter, overheating in summer that might easily be avoided by use of fans, awnings, etc., are not conducive to comfort. A disagreeable or abusive husband or weary hours spent over a chronically sick baby, unnecessary physical labor beyond the capacity of the patient, all tax the mental and physical strength of the toxic thyroid patient to an alarming degree. The importance of such factors frequently is unrecognized, and only a little instruction is needed for intelligent cooperation.

It is essential that both the patient and the family have an understanding of what is actually meant by rest. Often leisure time the result of freedom from household duties is occupied with entertaining loquacious friends whose eloquence on the morbidity and mortality of thyroidectomy is superlative, much to the detriment of the patient's peace of mind. The patient whose life is one continual round of social "duties," is in perhaps even more danger than the housewife who often welcomes rest; that is, it is apparently more difficult for the society woman to readjust herself to the quiet life.

Lack of sleep is a potent factor; inability to sleep, however, is only aggravated by anxiety over it, and this should be explained. Of prime importance in this connection is rest and relaxation in bed. Late parties or the getting of breakfast for some member of the family positively must not interfere with the time actually spent in bed each day. Rather should breakfast be served to the patient in bed. The patient must realize that though she may not actually sleep the whole time she is in bed, her body weight and her strength are being restored as a result of the food intake being converted into tissue instead of energy. Rest is imperative after every meal if increase in weight is to be expected.

Admonitions against the abuse of stimulants, alcohol, tea, coffee, tobacco, are frequently entirely forgotten, and sufficient

strain through their use is thrown upon the heart, kidneys, and nervous system to counterbalance any benefit gained through rest in bed.

Few persons consider it possible to give a sick person too much care; however, this is sometimes more annoying to a nervous patient than indifference. An instance of this is shown in the W. case (August, 1924) where every possible attention was given to a male patient thirty-seven years of age who did not improve satisfactorily, did not gain weight, and after his lying at home for some weeks, suddenly died as a result of an acute thyrotoxic flare-up after only two days' duration. The man was properly fed, exceedingly well cared for so far as physical things went, but an overanxious, highly emotional wife who was in direct charge of the situation apparently kept him so badly stirred up all the time that his appetite suffered, his sleep was greatly disturbed, and he gradually declined and died.

The psychic factor must never be lost sight of in instructing the patient. The surgeon, physicians, and nurses should anticipate the patient's apprehension by assuring her that if she will follow instructions, she will come back in good condition for operation and that she will go through the operation successfully, just as thousands of others have. It is always comforting to be assured that the road has been successfully traveled. Suggestion is the physician's best assistant. It works faithfully in his absence through the subconscious mind of the patient.

Many patients simply cannot or will not gain through rest at home. They are vitally interested in everything that goes on in the home, which is quite natural, and instead of remaining in bed, they will get up to do some little task or to join in some form of entertainment in which the remainder of the family are engaged. It seems impossible to impress upon them the necessity of staying in bed. Mr. S. remained in the hospital five days after ligation and was sent home to gain strength. Upon the slightest excuses he would get up and move about. He failed to improve at home, so that it was necessary to have him return to the hospital for absolute rest before any further operating could be done.

The state of nutrition is in my experience the best guide as to a choice of surgical procedures in toxic patients. The patient

who has lost a large amount of weight is invariably sent home after the preliminary hospital stay until a fair proportion of it has been regained, before resection can be attempted with safety. This is particularly true in exophthalmic goiter cases where so much can be accomplished by ligation, etc., toward starting the sufferer up hill. A low metabolic rate, fair self-control, restored circulatory balance and functioning kidneys are all duly emphasized, but extreme loss of weight is a *vital* indication in my experience, and no patient is a good surgical risk until substantial regain has been accomplished.

An illustration of how one must individualize according to circumstances is given in the case of Mrs. L. F. (November, 1924) who came into the office reporting a gain of fifteen pounds since ligation just six weeks before. Her improvement was in every particular commensurate with a gain in weight of a little more than 15 per cent, since she weighed only 97 pounds when the ligation was made. Under ordinary circumstances I would have allowed her to progress further for several more weeks preparatory to thyroidectomy, but I learned from another source that her husband was the subject of a rapidly growing abdominal tumor which gave a most doubtful prognosis. She naturally wanted to be with him, but I feared that disappointment and grief at seeing him fail would quickly rob her of all the gain she had made; I recommended immediate thyroidectomy before she learned of her husband's serious outlook, being sure that after her gland was removed she would be very much better able to withstand the shock of his expected death.

## References

[1]Bram, Israel: The Prevention of Exophthalmic Goiter, Endocrinology, May, 1923, vii, 415.

[2]Crile, George W.: Surgery Versus Roentgen Ray in the Treatment of Hyperthyroidism, Jour. Am. Med. Assn., 1921, lxxvii, No. 17, p. 1324.

[3]Hertzler, Arthur E.: Diseases of the Thyroid Gland, 1922, C. V. Mosby Company, p. 156.

[4]Hertzler, Arthur E.: Diseases of the Thyroid Gland, 1922, C. V. Mosby Company, p. 159.

[5]Bartlett, Willard: Painless Hypodermoclysis, Ann. Surg., February, 1921, lxxiii, 161.

[6]Plummer, Henry S., and Boothby, Walter M.: The Value of Iodin in Exophthalmic Goiter, Collected Papers of the Mayo Clinic and the Mayo Foundation, 1923, xv, p. 565.

[7]Hyman, Harold Thomas, and Kessel, Leo: Studies of Exophthalmic Goiter and the Involuntary Nervous System, Arch. Surg., January, 1924, viii, No. 1, p. 149.

[8]Grier, G. W.: X-ray and Radium Treatment of Goiter, Atlantic Med. Jour., 1923, xxvi, 516. (Abst. Endocrinology, Sept.-Nov., 1923, vii, 882.)
[9]Richardson, Edward P.: Relative Value of Surgery and Roentgen Ray in the Treatment of Hyperthyroidism, Jour. Am. Med. Assn., March 24, 1923, lxxx, No. 12, p. 820.
[10]McGuire, Stuart: Treatment of Certain Types of Goiter, Virginia Med. Monthly, September, 1923.
[11]Terry, Wallace I.: Radium Emanations in the Treatment of Goiter, Jour. Am. Med. Assn., 1921, lxxvi, No. 26, p. 1821.
[12]Terry, Wallace I.: Radium Emanations in Exophthalmic Goiter—Blood Vessels of Adenomas of Thyroid, Jour. Am. Med. Assn., July 1, 1922, lxxix, 1.
[13]McGuire, Stuart: Treatment of Certain Types of Goiters, Virginia Med. Monthly, September, 1923.
[14]Porter, M. F.: Goiter, A Clinical Study of 139 Cases, Ann. Surg., August, 1920, lxxii, 129.
[15]Mayo, C. H.: Personal communication.
[16]Mastin, E. V.: Blood Supply of the Thyroid and Its Surgical Significance, Surg., Gynec. and Obst., January, 1923, xxxvi, 69.

# CHAPTER VIII

## LIGATION

### Upon Which Patients Shall Ligation Be Done?

Preliminary ligation is always to be considered one of the steps in the preparation of a really sick exophthalmic patient for thyroidectomy which her condition does not justify at the time treatment is undertaken. Preliminary ligation is probably never properly indicated in any other phase of thyroid disease. In doing it, we merely speed up the natural tendency of these patients to the spontaneous improvement characteristic of this disease which runs its course through cycles.

My impression is that we prepare here a much worse type of goiter in spring than in fall as shown by the greater numbers of ligations done. This is due, no doubt, to the stress imposed by our winter climate (wet, changeable, etc.) which reduces the iodine intake to the absolute minimum because the patients are shut up indoors and do not get the maximum amount of fresh vegetables to which they have access in the warm weather and in general they have their vitality lowered by lack of sunshine, fresh air, and all the favorable circumstances which surround an outdoor life.

It may be properly said that we do preliminary ligation only where there is evidence of hypervascularity in the cardinal thyroid vessels as expressed by visible rapid pulsation as well as thrills and bruits. These form, of course, one of the three characteristic features of exophthalmic goiter, although these vascular signs are frequently so early that exophthalmus has not yet developed. On the other hand, it is our observation that the vessels sometimes, though rarely, appear to be more or less normal even though exophthalmus be present. In just these cases we have seen very little benefit from ligation.

One may ligate every patient who has thrills and bruits, although it is by no means always necessary. I have seen the most marked benefit from it. Practically every one returned to the hospital in sufficiently good condition to stand thyroidectomy, some in two stages, however.

In a patient with no thrill or bruit, the vessels are much smaller, show much less pulsation, are distinctly harder to find, and double ligation in one of our cases, at least, immediately gave the reverse of improvement.

One may go still further in discussing pure toxic adenoma where no thrill or bruit occurs and agree with C. H. Mayo that ligation is positively harmful here; no surgeon with experience in this line, therefore, is likely to consider it indicated in this type of thyroid disease.

When in doubt as to the choice between resection and ligation in exophthalmic goiter it may be safer to ligate. There can be no mistake in "playing safe" in goiter (toxic) surgery. We have all made serious mistakes by "taking a chance."

It is almost impossible to judge accurately the *recuperative* power of an exophthalmic patient with thrills and bruits. It is, however, certain to be less than one might estimate it. Such a patient is practically never seen by the surgeon until there has been loss of strength and weight, to say nothing of heart damage; therefore the safer plan may be to ligate as a preliminary measure, and thereby avoid the occasional tragedy which may occur if a surgeon does many immediate thyroidectomies as a routine in even the best risks among this class of patients. Mrs. R. (January 11, 1921) walked into the office and hospital, seemed in relatively good condition, stood operation perfectly, under local anesthesia (no sutures), then grew toxic and died in forty hours. Such an experience naturally inclines the surgeon to speculate on all the possibilities. This has occurred to me: when one finds it difficult to estimate the possible risk in a ligation, might this not be made easier by some manipulation of the gland calculated to cause an increase in toxic products, thus testing out the individual's capacity twenty-four hours in advance of operation? Theoretically it is analogous to squeezing out toxic products at operation.

For ligation or emergency thyroidectomy one may establish negative operative indications by testing will power to cooperate in the following manner: Give no morphine, then under light gas "dream" infiltrate, after which one may desist if the patient acts as did Mrs. L. (October 15, 1921) when she became unmanageable. This is merely one of the many clinical

manifestations which go together to convince the operator that the patient is not ready for any surgical procedure.

If the patient cannot be controlled, postpone the operation and experiment with morphine in order to ascertain the proper preliminary dose for a second operative attempt. The tolerance is always high, therefore the dosage considered normal is of no avail.

By sending back to bed the ligation patient who is brought to the operating table bereft of self-control, not only is a risk avoided for the moment, but after one, or at most a very few, such experiences, the invalid learns that a certain self-discipline will be exacted before surgical help is to be expected, whereupon a surprising degree of composure, and a most satisfactory effort at cooperation are at once manifested. An example was Mrs. C., a very toxic young mother, who came up crying (March 25, 1924). She was told that nothing could be done until she controlled herself, and further, that a return home to her seven months' old baby would be possible soon after two ligations. The next day she was brought up smiling and was easily ligated though no preliminary drug had been used. One is reminded in this connection that "half of all insanity is just meanness," as I once heard a distinguished alienist remark.

The operators connected with the Mayo Clinic tell me that the use of **Lugol's solution** has limited the incidence of ligation in their hands, but while I am appreciative of the value of iodine in exophthalmic goiter, I cannot say that I have found this to be universally true in my own work. Perhaps this is explained by the fact that a mixed type of disease is very frequently encountered in this vicinity, characterized by multiple small adenomata distributed throughout a hyperplastic thyroid.

Before we employed Lugol's solution as a routine, ligation (April 28, 1923) killed Mrs. J. and Mrs. D. within thirty hours. They belonged to the class termed "total loss," had been through many cycles for eight and nine years, respectively. After prolonged rest in bed, they ate well, decompensation and kidney upset disappeared, rate was about 90; still they had no margin of safety left for a procedure lasting less than five minutes. Both became acutely toxic and the hearts failed. Perhaps in this era of Lugol's solution we might have saved these

two worst risk patients. A very old disease may be in its last cycle. If so, ligation will kill the patient; if not, she will automatically reach a free interval; "hands off," therefore, if the picture be recognized. X-ray treatment, or possibly boiling novocaine injection, alone is indicated in this class, since these procedures give encouragement if nothing more.

There is no other test of the patient's resistance equal to a ligation when one cannot decide what to do in very mild typical hyperplasia with vascular changes. The degree of subsequent reaction will decide the surgeon as to choice of a second ligation in a few days or a lobectomy, provided there has been no upset following the first ligation.

The question of **when to ligate the second side** naturally occurs to one in this connection. In many instances the two stages are separated by an interval of forty-eight hours to one week. I do not believe that any general statement can be made covering all cases, since this must be an individual matter in each instance and many circumstances combine to determine the period of recovery from the first therapeutic attempt. One may say in general that it is safe to proceed to ligate the second side as soon as the "storm" or soreness from the first side has subsided.

In our clinic we very rarely attempt double ligation at one sitting. It must be remembered that we are working on doubtful patients, therefore one may say in general, the less done, the better, until the patient's ability to stand punishment has been fully established. It would seem logical if two ligations can be readily borne to go just a short step further and remove half the thyroid which is surely of immeasurably greater therapeutic value. Still circumstances must occasionally be considered and I will admit that we have now and then proceeded as we did with Miss C. (February, 1921), a type of patient presenting all the typical symptoms of exophthalmic goiter. Though she was able to be at her customary duties and compensated, we did not risk immediate thyroidectomy, nor did we subject her to two separate ligations. We compromised by doing double ligation the day after entrance, then x-rayed *both* sides of the neck at a single sitting three or four days later, letting her leave the hos-

pital as soon as she was strong enough, the total stay being five days.

When it is possible to keep a moderately sick patient in the hospital for one prolonged stay, during which time only non-operative procedures are used in the preparation, we have in recent times preferred this method in many instances to the other one, involving a hospital stay of two weeks for ligation and two more weeks several months later for the resection.

We shall probably never be able to dispense wholly with ligation in severely sick patients; therefore I have given the subject the full consideration that would have been accorded it a few years ago. This seems justified in view of the further consideration that many who say they never ligate may be taking an extreme stand when perhaps others who read this chapter are employing ligation with relative frequency and may in consequence deduce something helpful from my experience as set forth herein.

### Anesthesia

The anesthesia for ligation presents nothing which is not covered under anesthesia best adapted for thyroidectomy; there are a few minor indications here, however, which may be deserving of special mention in this connection. We do ligations under novocaine infiltration which is masked by a very light nitrous oxide inhalation. In many instances, however, it might be better to depend upon infiltration alone, thus leaving the patient her ability to swallow upon request, because in this way the operator is enabled most easily to identify the superior thyroid pole. There is the same preliminary dulling of the sensibility by barbituric acid compounds and morphine which has already been mentioned. We employ our maximum morphine dosage in just these circumstances. We gave two grains at one dose to Mrs. R. (April, 1920), a woman who had never had the drug before; still her extremely high metabolic rate enabled her to consume the drug so rapidly that no untoward symptoms became manifest in consequence. She was merely very quiet, with a slight tendency to cyanosis. I do not, of course, recommend recklessness in the use of morphine, although I wish to make it clear that experimentation with this drug will prove in many

instances that the patient with a high metabolic rate has established a perfectly abnormal tolerance to it, hence the doses in which we usually administer it as a sedative are relatively so small for such patients as to become merely stimulative, therefore undesirable.

As to the infiltration solution to be used, many experiments have shown me that the anesthetic effects of ½ of 1 per cent novocaine solution last about five minutes in the average, whereas the effects of a 1 per cent solution frequently last for about twenty minutes as mentioned elsewhere, certainly long enough for the average operation of the kind under contemplation here. Of course, no adrenalin is employed in these highly toxic patients for reasons too well known to justify repetition here. We have used solutions stronger than 1 per cent (although unnecessary). For instance, infiltration with 10 c.c. of 2 per cent novocaine alone made it possible to do a most deliberate ligation (superior thyroid) for Mr. S. (February, 1921) with as perfect an anesthesia as we ever obtained by using adrenalin. It was characterized by a total absence of the symptoms as commonly noted during and after ligation on very sick patients.

Massive infiltration with very large amounts of fluid stirs up patients before ligation. I never exceed 10 c.c., then if need be, I use more on the table after incision. It must be added that massive infiltration renders the neck exceedingly sore after ligation and conduces to unrest.

No preliminary drug is employed before ethylene for ligation; this spares many patients the nausea, vomiting, depression, and occasionally more serious symptoms which are thus caused. When postoperative pain or restlessness necessitates the use of sedatives, they produce no such unpleasant consequences as they do when taken in conjunction with the general anesthetic.

Ethylene or nitrous oxide is usually employed for the first superior pole ligation as stated. Most patients, however, have acquired so much confidence in themselves or in us by the time the second pole is tied a few days later that they are ready to accept an infiltration anesthesia or anything else that we have to propose. We never, though we have started with infiltra-

tion alone, impose on patience and good nature, however, by a tedious search for the vessels or by unusual retraction, but insist on administering supplementary gas before the sufferer begs for it.

## Technic

A patient sick enough to demand ligation is sick enough to be saved the upset of going to an operating room (unless completely benumbed previously). It is a good idea to ligate a very sick patient in her bed for the same reason that no short, simple life-saving abdominal operation like an enterostomy for obstruction would be done anywhere else than in bed. A rather dopy patient takes very little cognizance of the brief preparations which turn her private room into a thoroughly adequate operating room and her bed into a table which is a little too broad and a little too low for the operator's comfort, this being no concern of hers. We do all of our sterilization of hands and our dressing in the operating room; then all supplies, assorted and ready for work, are carried in at the time the anesthetist enters with the gas machine. A sterile sheet is spread over the patient and bed, gas is started, the neck is cleaned up in the simplest manner, and before the patient sees the surgeon she is oblivious to the surroundings; most of those who have taken part in the procedure have left the room by the time she is awake. One who has not done a ligation in bed may dread it, but the truth is that a well-trained group of assistants can make this procedure almost as agreeable to the surgeon as though carried out in the operating room, provided only an adequate extension light of some sort is focused on the field and maintained rigidly in position so that no heads throw shadows upon the field.

**Marking the neck,** more than any other one maneuver, enables the surgeon to locate the superior thyroid vessels. Of course, a visible superior thyroid artery with its easily palpable pulsation and thrill gives one an idea of where he is to work, but this should never be taken as the sole guide because what one sees is often the anterior branch far below the bifurcation above which the ligature must go. With this in view, we gently scratch the neck with a very sharp needle, making three lines (Figs. 10, 11, 12); (*2*) high in the midline of the neck,

(*3*) at the anterior border of the sternomastoid muscle, connecting these two marks with another which follows the oblique border of the gland (*2-3*); it often follows a skin fold and under it can be felt the pulsation of the artery and its thrill. The artery lies beneath a point two-thirds of the way from *2* line to *3* line. It thus becomes evident that our incision follows the posterior half of the line *2-3* referred to above. It must be empha-

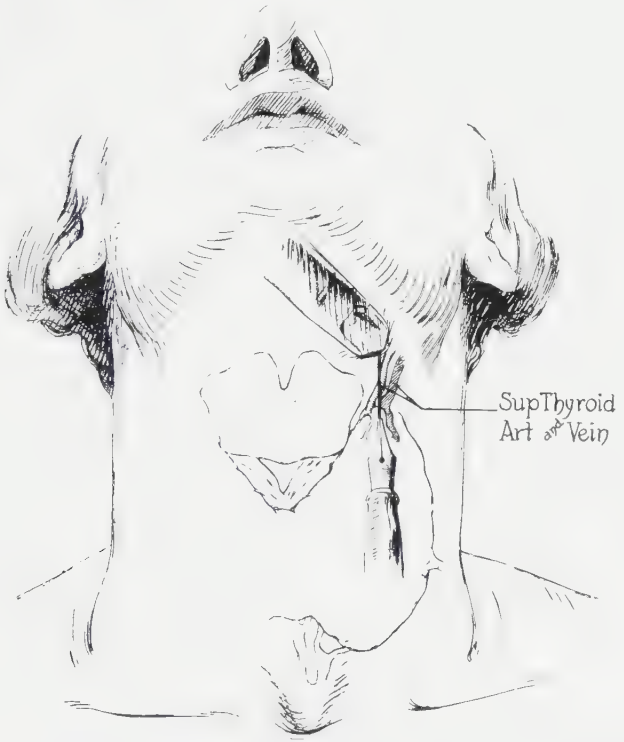


Fig. 10.—In order to facilitate finding the superior thyroid vessels, the ligation operation should have as one of its steps the making of a vertical ink line or scratch marking the point where the superior thyroid vessels can be seen or felt.

sized that the line *2-3* is to be marked *while the patient swallows* and thus elevates the gland to the highest possible point.

The importance of marking the skin before making the ligation incision can be fully appreciated only by one who has carried out the procedure a few times. The position of the head must not be changed in the slightest degree after the site of incision has been determined upon and marked (Figs. 10, 11, and 12), since the relationship of the skin area covering the

upper pole can be so completely altered by shifting the head, neck and shoulders that the operator who has made the mark with the head in one position, then operated with it in another, is completely deceived and is frequently worse off than if he had made no mark at all. The difficulty of locating the tip of the upper pole after the neck has been in great part covered up and novocaine infiltration (Fig. 13) started is certainly enough

Fig. 11.—A line (2) marks the midline of the neck, and another (3) marks the anterior border of the sternomastoid muscle. Line *1* is that described in Fig. 10.

to test the patience in many instances even without an improperly placed skin mark to upset one's locative sense.

In a very large goiter which has thinned-out ribbon muscles, or where there is need of a rapid operation, it is very simple and satisfactory to continue the line of skin incision (Fig. 14) straight down through platysma (Fig. 15) and ribbon muscles directly to goiter tissue. If this be done directly across the tip of the upper pole, one is surprised at the extreme simplicity

with which vessels and pole can be manipulated, to say nothing of the extent of exposure.

As has been mentioned, the patient by swallowing upon request moves the gland up and down, thus giving an operator great assistance in locating the upper pole, one of the best arguments for local anesthesia in ligation.

The superior thyroid vessels are encased in a muscular sheath given off the posterior surface of the ribbon muscles.

Fig. 12.—A line is drawn obliquely across half the neck following roughly the upper border of the thyroid and connecting lines 2 and 3. The posterior two-thirds of this line 2-3 is the ideal location for the line of incision.

One may split ribbons longitudinally (Fig. 16) just in front of vessels and not see them until the sheath is opened separately; an argument for the rather objectionable cross-cutting of them. Dissection of the proper layer is greatly facilitated by lifting the muscles (Fig. 17) toward the ceiling during the splitting procedure.

There is but one "sure-fire" method of isolating the struc-

tures which enter the upper pole and of applying a ligature above the bifurcation of the vessels; viz., by first clearly exposing the pole itself which is then drawn downward while the upper wound-lip is retracted in the opposite direction. Nothing would seem simpler than to cut directly down upon a tissue mass

Fig. 13.—The skin and deeper structures are infiltrated through a single opening at the outer extremity of the intended skin line. The insert in the left lower corner gives an idea of the four planes which are infiltrated.

that can be palpated, but an unpleasant surprise often awaits one who discounts the unusual appearance of an infiltrated muscle field.

After seeing and feeling through the intact skin the enormous pulsating superior thyroid artery, we can make a simple

operation difficult or even impossible by faulty retraction: (a) Two, three, or four individual retractors pulled in different directions by different assistants can so slide the tissue layers over one another that a direct approach is not made from the



Fig. 14.—The skin incision is made.

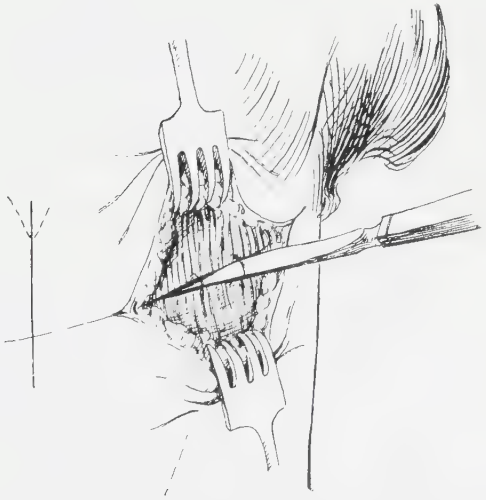

Fig. 15.—The skin is retracted and the platysma muscle, together with the cervical fascia, is divided.

skin mark to the artery. (b) Assistants are very prone to retract the tissue planes upward away from the vessels to the end that their communicated pulsation cannot guide us. This double difficulty is met by the use of light automatic spreaders

which cannot distort the wound edges, but which by their weight depress them slightly and thus throw the location of the artery into view when the more superficial structures have been divided.

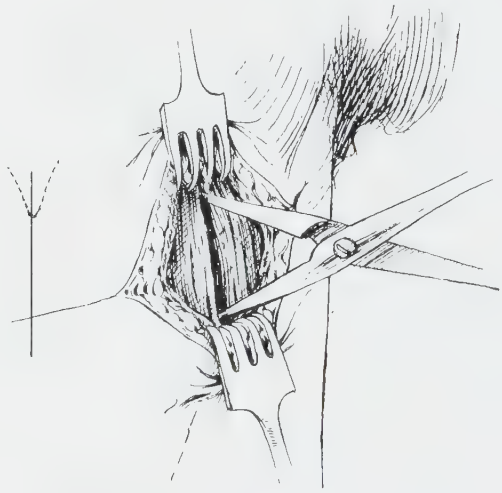

Fig. 16.—The ribbon muscle layer is split longitudinally.

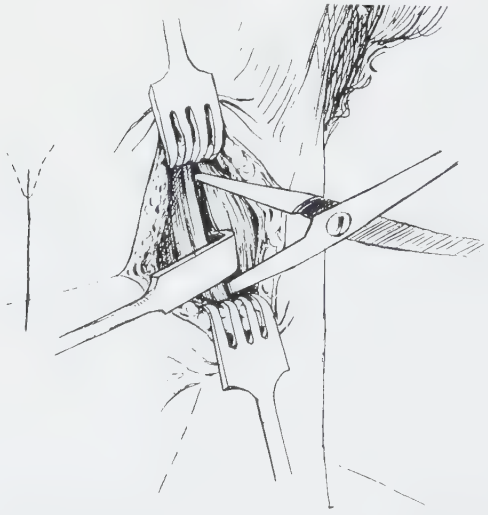

Fig. 17.—The retractor is inserted with the intention of reversing the direction of the wound when its walls are stretched.

After locating the superior thyroid artery on the upper border of the lobe, the operator should always work backward and upward until he can apply the ligature above the bifurca-

tion. In one case (June, 1921) the posterior branch was distinctly larger than the anterior. This must also happen in other cases.

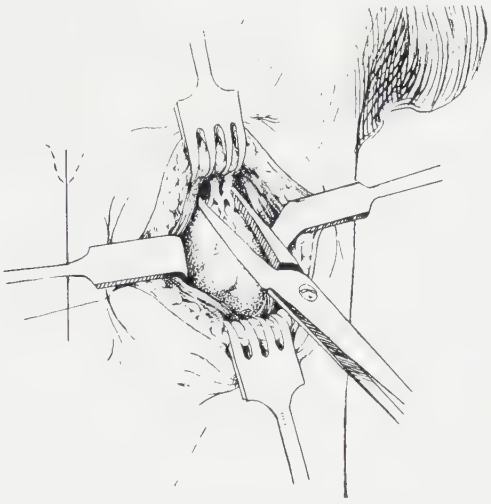

Fig. 18.—The upper pole is exposed by the retraction and the group of structures entering it are grasped en masse in a clamp.

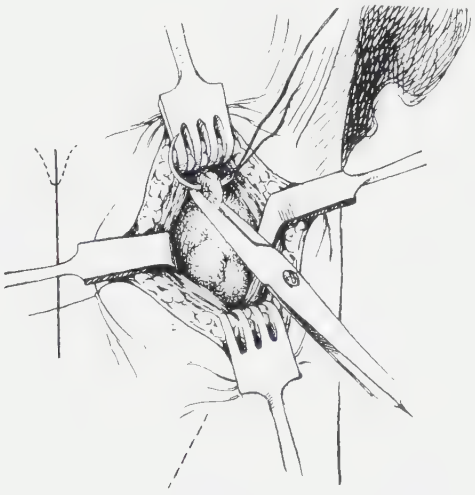

Fig. 19.—This bundle, consisting of artery, veins, nerves, and lymphatics, has a catgut threaded needle carried around it.

After thoroughly isolating all the structures which enter the upper thyroid pole (Fig. 18), we pass a ligature (Fig. 19) of "extra hard" catgut around them all in a mass and thus

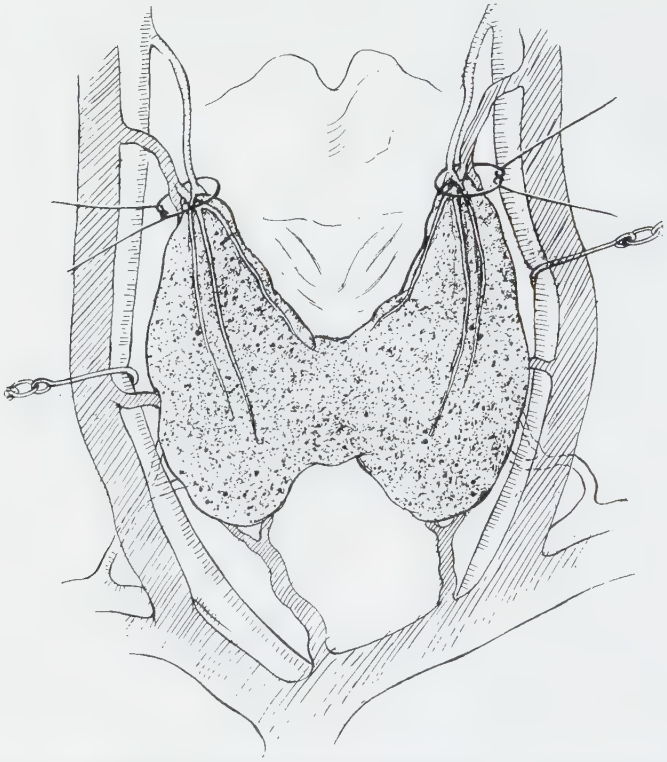

Fig. 20.—The ligature in its relation to important surrounding structures.

Fig. 21.—The ribbon muscle slit has been closed by sutures (sternomastoid muscle is sometimes drawn forward to obliterate this defect in patients whose ribbon muscles have been transversely divided).

constrict artery, veins, secretory nerves, and lymphatics (Fig. 20). Sometimes we double ligate and divide the veins separately before we can be absolutely certain of the position of the

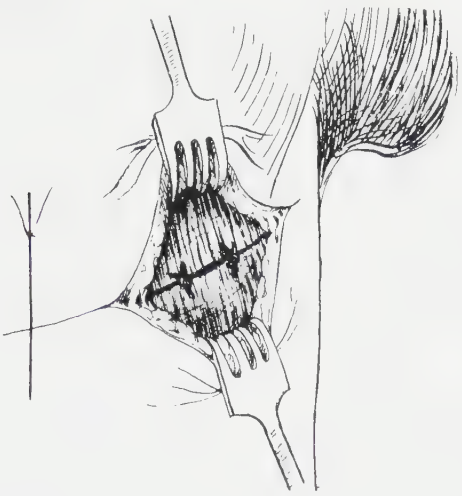

Fig. 22.—Two or three sutures are employed to reunite the lips of the platysma muscle wound.

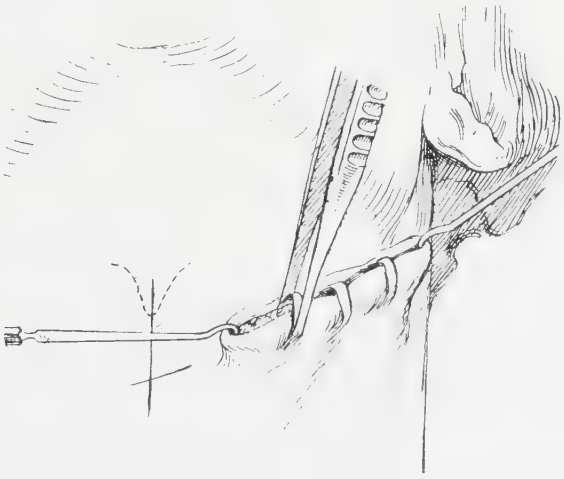

Fig. 23.—About three clips suffice to close the tiny skin wound completely.

artery, although this is not usually the case. Sometimes a needle cuts one of these vessels and creates what might be thought at first sight a serious situation. The simplest way of meeting this is to take a deeper bite with the needle, thus in-

cluding the injured vessel in a second loop of the original ligature.

These small ligature wounds are very simply closed by treating three planes separately. One deep suture (Fig. 21) draws the anterior edge of the sternomastoid muscle forward to close the defect in the ribbon muscles, then the edges of the platysma wound are approximated with two or three sutures (Fig. 22), after which about three metal skin clips are applied (Fig. 23).

The wound should be left open when thyroid tissue has been torn into with the consequent liberation of toxin; it is packed with rubber for twenty-four hours after which time it is closed by drawing tight a mattress skin suture introduced at the time of the operation.

It is very rarely advisable to ligate both superior vessels at one sitting. I have had an unpleasant result every time I have done it. (The same is true of taking these patients to the operating room; ligation should be done in bed.)

One scar will often be lower than the other. After healing of the ligation wounds, it will be observed that the height of the two scars varies with the location of the two poles to which they have been suited.

### After-Treatment

The same general features of the after-treatment required for patients having had resections will apply to those having had ligations. However, the following points are to be given particular consideration in ligation cases:

A moist glycerin pack should be applied immediately after ligation, as it influences the primary infiltration edema. It also lends an agreeable sensation of warmth, and it minimizes unrest.

The wound is left open twenty-four hours if perithyroiditis has complicated the operation; this insures drainage and adds to the comfort of the patient.

The patient's position in bed should be regulated absolutely by her wishes. Usually she is more comfortable in a half-sitting posture with her head inclined toward the affected side because in this way she takes tension off the wound.

Clips are removed at the expiration of twenty-four hours.

This not only is conducive to the patient's comfort, but it is the only way in which we can avoid the slight pressure necrosis which leads to notable scar formation.

It is a difficult matter to know just when to permit toxic thyroid patients to get out of bed, because there is so little to guide us, as they do extremely well as long as they are perfectly quiet in bed, especially so long as mild sedatives are employed. On the other hand, many of them experience aggravation of several phases of the disease as soon as they get up and move about. A practical index of their condition and the way it is affected by sitting up is the change in the pulse rate. Since there are no means of telling in advance just how such a patient is going to respond, one has only to experiment with the individual. The known pulse curve in bed is compared with that made when the patient sits up, and if the increase in rate does not exceed 10 per cent, the individual may gradually be permitted more freedom; but if it does increase more than 10 per cent, she is put back to bed and the whole procedure is repeated.

## Complications

In the special chapter on Complications (Chapter XVII) which sometimes follow thyroidectomy I have gone into the description of many of those which may follow ligation; there are one or two complications, however, which are especially prone to follow ligation operations only.

I have been unable to learn from any of the anatomists why it is that we often see pain in the teeth of the lower jaw when we infiltrate the upper pole of the thyroid or when we ligate the superior thyroid vessels. Dr. J. E. Thompson, well-known anatomist and surgeon of Galveston, states that he has been troubled by a similar manifestation in the side of the tongue of those upon whom he has ligated thyroid vessels. He was unable, however, to suggest an explanation either as far as the tongue or the teeth are concerned.

One of my cases, Mrs. G. (October, 1921), seems to prove that clean ligation of vessels alone is the safer method of ligation. On October 13, ligation of the large *upper pole,* including much thyroid tissue, resulted in the same postoperative toxicity that sometimes follows lobectomy. The second ligation (Octo-

ber 28) seems to prove the point that serious after-effects may be avoided by technical considerations. In the second ligation the gland was never touched, the vessel being carefully isolated and cleanly ligated. Then the wound was filled with glycerin (hygroscopic) and packed wide open with rubber. There was no postoperative disturbance compared with that which followed the crushing of much gland tissue by the first ligation.

A most unusual complication followed an attempt to ligate the superior thyroid vessels by an operator of my acquaintance who had had, I am sure, very little previous experience in this field of surgery. When I first saw his patient about three months after the operative attempt, she had a hemiplegia which, as I was told, began during the operation. The most natural explanation of this phenomenon would seem to be that either the common or the internal carotid was tied by mistake with the immediate almost complete unilateral cerebral anemia, which is known to result in hemiplegia in a very definite percentage of the patients so treated (about one-third).

### Benefit to Patient

There is no logical explanation of the benefit derived from ligation that will fit all cases, though this operation almost always improves the patient. Its benefit cannot be wholly explained by the fact that two superior thyroid arteries are divided, since the gland has perfectly adequate blood supply aside from these two and after their division certainly extensive anastomoses form.

One has but to read Mastin's[1] article to be assured that the benefits of ligation do not come from interruption of the superior thyroid arteries alone. It may be that the division of the secretory nerves, branches of the sympathetic system which enter the upper poles along with the arteries, has something to do with the matter by inhibiting secretion to some extent. It is supposed, too, that we at the same time block numerous lymphatics which follow the course of the superior thyroid veins and thereby relieve the system of a certain amount of toxic material which they were carrying into it as long as they remained intact. The reader is at liberty to choose to his

own satisfaction the theory that suits him best, to combine all of them, or to make his own combination of any two.

I am sure of only one thing in this connection—that most marked benefit practically always follows superior pole ligation if the case be really one of exophthalmic type. One thing more must in all fairness be stated; namely, that benefit has not failed to make itself apparent even when the operator has failed to find the vessels (but ligates the pole instead), a mishap which is sure to occur in a certain percentage of cases, as Mastin assures us in his exhaustive article just mentioned. How is this to be explained? To some extent, no doubt, by the psychic influences of the operative attempt. These patients appreciate every sort of maneuver that is intended to be of therapeutic value and benefit themselves by their endeavors to cooperate instead of becoming despondent at what they might interpret as neglect.

A histologic study of the effect of ligation in exophthalmic goiter made by Giordano and Caylor[2] "shows that distinct clinical improvement and lowering of the basal metabolic rate occurred more often in those cases in which definite involution changes in the ligated pole could be demonstrated histologically. On the other hand, a few definite exceptions demonstrated that a correlation between the clinical findings and the presence or absence of involution changes is not to be expected in *all* cases."

Why does ligation benefit two patients to such a different degree? Mrs. C. and Miss U. had ligation and thyroidectomy about the same time (January, 1922), the former having gained about thirty pounds, the latter nothing. They had been similar cases in every particular. Mrs. C. was ready for thyroidectomy in every way, while Miss U. had it done—in spite of every unsatisfactory condition—to prevent further loss. Is the explanation that the original cause (focal infection) in one instance happens to subside and favor ligation, while in another ligation, etc., does not offset a persistent infection?

Occasionally a patient seems to be improving too slowly after ligation and in consequence does not get into good condition for thyroidectomy within the commonly allotted two to four months. In such instances the greatest benefit is frequently seen to follow the boiling water injection of Miles Porter or the

exposure to therapeutic doses of x-ray. Miss E. had a double ligation in June, 1923, left the hospital very little better than when she entered, and two months later returned in very much the same condition, weighing 102 pounds. Immediately after the injection of both lobes and x-ray treatment of both, she commenced to improve so rapidly that at the end of two more months, she returned having gained markedly in weight, and equally improved in every other particular. A subtotal resection was made without any unfavorable incident and now, just two years later, she weighs 127 pounds, is busily engaged in office work, and is, as far as we can determine, restored to her average good health. I have in the chapter on Preparation (Chapter VII) taken up in considerable detail the matter of injection and x-ray treatment. I do not think they are by any means necessary adjuncts to the treatment of many ligated patients, but in those rare instances where ligation seems to work too slowly, they will be found invaluable adjuvants to it.

### Interval between Ligation and Thyroidectomy

There seems to be no very definite rule regarding the interval that must elapse for the accomplishment of sufficient benefit from ligation before which a patient may safely have thyroid tissue removed. Dr. Halsted used to tell me that he believed two weeks would be long enough to secure all possible benefit from ligation. On the other hand, the majority of patients will commence to retrograde in about six months after the ligation—followed by symptomatic cure—has been done. So this matter, like almost everything else in medicine, must to a large extent be an individual matter as far as each patient is concerned. I shall not attempt, then, to draw any general rule for the exact time that a patient shall remain at home before thyroidectomy. Many of them go through the ordeal safely at the end of two or three months, and I have one who has remained perfectly well for five years without returning, although this woman constitutes the exception, proving the rule that such symptomatic cures are in almost every instance of but a few months' duration. This seems to be rather a matter of condition than of time, hence I have abandoned the practice of giving the patient a date for return, but I tell her rather that she may expect to

be in condition to safely withstand thyroidectomy as soon as she has regained 50 per cent of her lost weight. I realize, of course, that this is not a matter of weight alone, but also of nervous control, metabolic rate, cardiac condition, etc., still the matter of weight is a fairly reliable index of these other allied conditions, and it is surely the one of which the patient can herself most readily take cognizance. Many of these individuals are not under the direct care of a physician who is thoroughly familiar with thyroid work; therefore, some such working rule seems of value in these instances. The average patient goes through somewhat the following course after ligation:

Mr. W. (Fall, 1921) responded to double ligation in a most interesting manner. In about three months, his heart was no longer dilated, he had gained weight, had lost all subjective symptoms, his eyes had receded, he was able to work and was pronounced by Dr. Andrews ready for thyroidectomy, although his rate had never changed from about +80 where it was at first. Later it came down to +45 before successful double resection was done at two sittings six days apart.

Successful ligation is by no means always followed by uneventful improvement to the point where thyroidectomy can be undertaken. Such patients do well in the hospital; then when they are thrown upon their own resources at home, the strain of unfortunate surroundings sometimes overcomes them to the extent that a relatively small number of them must return to the hospital for extended preoperative preparation. Mrs. H. became so completely decompensated about the time for her thyroidectomy that it required two weeks of digitalization before anything could be done. Miss W.'s double corneal ulcers required more attention by oculists than her strength permitted her to get in the usual way, so she had to reenter the hospital, where it was seen that chronic suppurative tonsillitis was holding back her recovery, and tonsillectomy was performed. Mrs. G. improved gradually at home for a few weeks, when uncontrollable vomiting started, for the treatment of which her reentrance was advised. It is well to follow up all ligated cases and have them reenter the hospital if they do not show steady progress toward recovery.

Miss E. (July, 1923) had a double superior pole ligation, but remained practically *in statu quo* until October following, when "thrill" and "bruit" were again marked in the right superior pole. She returned to the hospital and re-ligation was done. Two days later we commenced x-ray therapy on both sides, giving three treatments at forty-eight-hour intervals. In order to inhibit the activity of the gland as much as possible in this stubborn case, we then injected 10 c.c. of boiling ½ per cent novocaine into each lobe, allowing three days to intervene between the treatment of the two sides. A whiff of gas preceded the injection, and the novocaine took effect before the patient was fully awake. An ice collar was applied immediately and no discomfort was experienced at any time. Resection should never be done within a few months of hot novocaine injection or until time enough has elapsed for the consequent adhesive perithyroiditis to clear up.

Mr. L. (September, 1920) had rested a few weeks, had had double ligation, and had gone into the hospital for radical operation. The next morning he became maniacal. Immediate double thyroidectomy was done, whereupon all symptoms disappeared in less than forty-eight hours. Mr. L. while losing weight showed the most ravenous appetite I have ever observed, devouring everything offered him at short intervals.

Up to this point we have discussed only the clean-cut case in which ligation with a long interval of rest and then thyroidectomy are indicated by the severity of the disease, but between this class of patients and those who are fit for an immediate thyroidectomy when first seen come many patients about whom we are in doubt as to operative indications even after the most exhaustive examinations. In a number of them we do what is called a test ligation merely to try out the patient's power of cooperation and to be sure that she has a reserve well beyond demands of this minor operative procedure. If no postoperative storm at all follows this test ligation, we very often at the expiration of a week or ten days feel safe in doing a lobectomy or in some instances a bilateral resection. I do not remember to have been greatly deceived in the ability of such an in-

dividual to stand punishment after being tried out by a therapeutic test ligation even though all ordinary examinations had failed to clear up the surgical indications in the case.

## References

[1]Mastin, E. V.: Blood Supply of Thyroid and Its Surgical Significance, Surg., Gynec. and Obst., 1923, xxxvi, 69.

[2]Giordano, Alfred S., and Caylor, Harold D.: Histological Study of the Effect of Ligation of the Thyroid Vessels in Exophthalmic Goiter, Surg., Gynec. and Obst., January, 1923, xxxvi, 75.

## CHAPTER IX

## POSITION ON TABLE AND DRAPING OF PATIENT

The patient, wearing a sterile cap to confine her hair, and a sterile gown that may be drawn down over the shoulders, is placed on a well-padded table tilted to an angle (head high) of about 30 to 35 degrees. There are several reasons for having the head of the table elevated to a considerable degree. One usually given is that this has a determining influence on venous bleeding. I am inclined to think, however, that its importance has been overstressed. It is without doubt more convenient for the operator to work with the patient's neck rather high up where he can get at it without bending over; then, too, the field is certainly somewhat better lighted the nearer it approaches the source of illumination, presumably the ceiling.

A footrest adjusted according to the height of the patient not only keeps her from slipping off the end of the table, but adds materially to her comfort through the feeling of security. A pillow is placed at the head of the table. It will be understood, of course, that all of the linens, gauze, etc., mentioned throughout the description of the draping of the patient are to be sterile.

The patient's hands are loosely confined in leather cuffs at the sides of the table, the nurse performing this duty being careful to give the patient the impression that this is done merely to make her more comfortable and to insure her safety on the table rather than to restrain her freedom. A folded sheet is next placed over the whole body coming well up onto the chest as shown in Fig. 24. A strap fastened just above the knees keeps the legs from being bent and the patient from slipping down in any body movement during the operation. One should use an exceedingly broad strap across the thighs and be sure that it is well padded, since faulty technic in this particular has in my experience occasioned most of the complaint which I have heard from patients under local anesthesia.

A two pound sand pillow is placed between the shoulders at the base of the neck elevating the field of operation



Fig. 24.—Table inclined, elevating the head to a degree which suits the operator's convenience.

Fig. 25.—Sand pillow at base of neck between patient's shoulders—seen from above.

(Figs. 25 and 26), and the neck is prepared as described in the chapter on Technic. The head should be thrown well back, but not too far for the patient's comfort. In this way, the goiter is thrown prominently into view by the separation of the chin

Fig. 26.—Sand pillow seen from side and above.

Fig. 27.—Long twisted gauze strand crosses upper neck, ends being packed below field of operation. Covering sheets in position.

and clavicles, the two structures which tend most strongly to get in our way if during the operation the patient slips down on the table with consequent tendency to "crumple up." Next a folded sheet is drawn across behind the neck and brought down over the shoulders well at the side of the neck (Fig. 27).

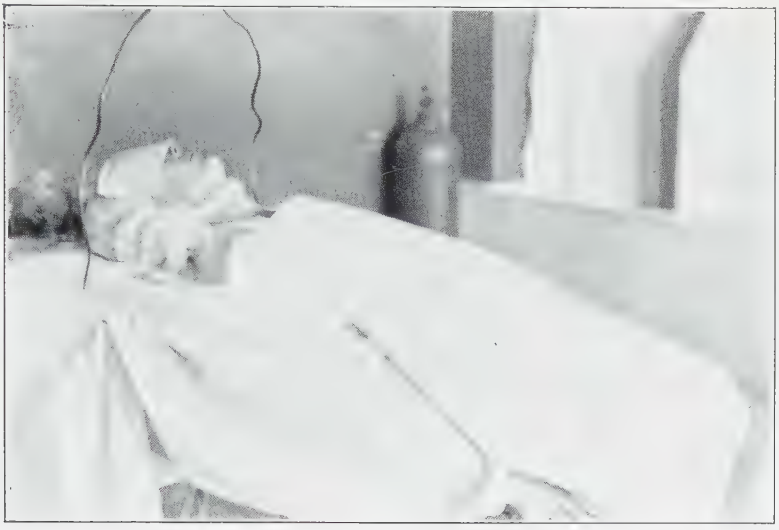

Fig. 28.—Wire arch over patient's face.

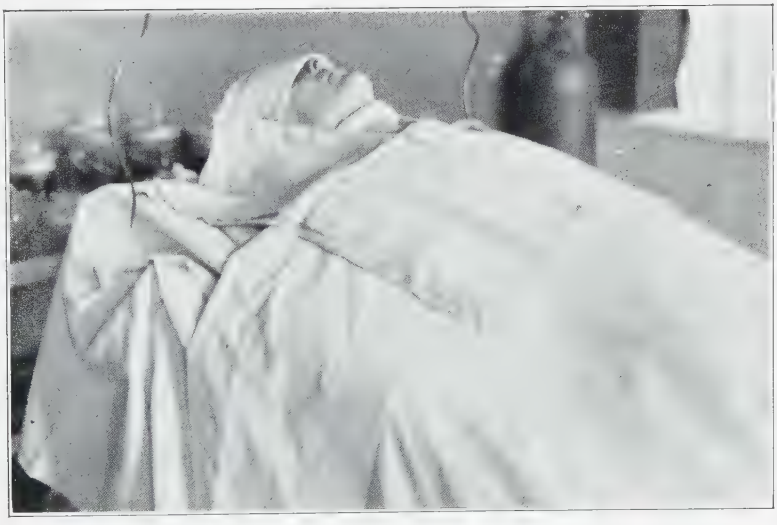

Fig. 29.—Final sterile towels in place.

Two crushed towels or gauze pads placed in the two sides of the neck tend to fill in the space between the shoulder and the cheek (Fig. 27).

A guard of pliable copper wire is adjusted over the top of the table as shown in Fig. 28, and a sheet is then placed over the entire body and brought up over the chest to within about

Fig. 30.—Split sheet in place so that nothing but the site of incision is exposed.

Fig. 31.—Patient's face as viewed by anesthetist behind the shield.

an inch of the mark where the incision is to be made. Two folded towels are next placed over the crushed towels and the sheet, the ends being allowed to extend to the top of the patient's head (Fig. 29).

A split sheet is placed in position, one-half being thrown over the wire guard to obscure the patient's vision of the opera-

tive field as well as to assure asepsis, the other half down over the chest, leaving a well-exposed field for operation (Fig. 30). The split sheet is held stationary by forceps attached to the hem of the slit and allowed to fall back at the sides of the patient's head, maintaining the sheet in position by their own weight (Fig. 31). The edge of the sheet over the guard may either be held out of the patient's face by forceps adjusted as shown in the illustration, or by the hand of the anesthetist.

Folded towels are placed over the split sheet at either side of the neck covering the skin of the neck so that upon exposure the edges of the mid-split ribbon muscles may be attached to the towels.

# CHAPTER X

## ANESTHESIA

The ideal anesthesia for goiter patients is produced by a combination of novocaine infiltration and nitrous oxide or light ethylene gas.

There has been much controversy in the past between the adherents of general and of local anesthesia for goiter work. My own experience convinces me that in most instances one can with profit employ the advantages of both at the same time. By so doing, the disadvantages of both can be largely eliminated and all their advantages retained. So far as general anesthesia is concerned, it does not have to be more profound than merely to mask the steps of an infiltration which are in every instance unpleasant, and to the toxic patient, a source of positive torment. For this purpose nitrous oxide or ethylene with a high dilution of oxygen are amply sufficient, while ether with its possibilities of deep narcosis is never needed and should, as I think, never be employed.

Our whole plan of operation, especially in toxic patients, is built up around the idea which Crile aptly termed "stealing the goiter," in other words, the patient is not to know the exact time, day, or hour of operation, to avoid a sleepless night preceding it. She is to be sufficiently under the influence of drugs when the time arrives that she will manifest little interest in removal from bed to the operating room or in any preparation of the room for operation in bed.

### Preliminary Sedatives

Preliminary drugs should never be used if a patient must be got up immediately to avoid interruption of ordinary life routine. It is essential that old people be urged to sit up at the earliest possible moment after any operation to avoid postoperative hypostatic pneumonia as well as to conserve their strength, as it is a known fact that the senile patient will weaken physically and lose his morale more quickly if confined to bed. This is even more true in the senile goiter patient. Mr. J.

(March 11, 1922) a man of seventy-seven, having an aortic lesion, bore well an operation under local and light gas anesthesia without preliminary drugs for the removal of an enormous obstructing adenoma. At noon of the same day he ate a hearty lunch and sat on the porch in a wheel chair in the afternoon. As a rule, however, preliminary sedative drugs are indispensable and their use is heartily recommended.

As has been said, some modification of Crile's technic of stealing the goiter is frequently employed in toxic individuals in our clinic. Choice in this matter depends somewhat upon the individual's wishes; the practice, therefore, is not universal. A few patients particularly wish to know just exactly when the operation is going to take place and they cooperate beautifully with the surgeon. It is better that they be told what is in store for them. On the other hand, a certain number ask upon admission that they not be informed in advance, which wish is, of course, always respected. This leaves a very large percentage of toxic individuals who never express a desire one way or the other, and who are, indeed, too sick to be wholly logical about any phase of their treatment and for whom it is really impossible to predict a date for operation until the individual's condition seems to warrant the attempt. An excellent rule is for operator and patient to concern themselves very little about the matter until the sufferer has reached the maximum of improvement, when the surgeon may telephone the family that operation will be relatively safe in twenty-four hours and at once begin rather rapidly the employment of sedative drugs which will so decrease the patient's interest in her surroundings that she will take very little notice next day of the surroundings which characterize an operating room.

We must guarantee patients self-control by preliminary drugs if need be. Spoiled Miss U. (January, 1922) "played possum" so that we would consider her quiet enough for operation; she got no preliminary drug, and then had to be held down, to the injury of a bad heart. One grain of morphine would have protected her heart to a great extent.

Sometimes one sees an unexpectedly profound effect from preliminary drugs where he has planned to use gas: now no two patients react in the same way to the preliminary drugs

we have employed; hence one cannot tell certainly until the operation is begun whether or not gas is to be employed. I always have it ready, but do not nearly always have to use it during the infiltration though it is more dependable and safer as a rule than any "preliminary" pushed to the point where it really obtunds the patient.

**Veronal** makes for many patients a most satisfactory preliminary drug where ethylene or nitrous oxide is to be employed. The patient comes to the table after a perfect night's sleep, in a calm frame of mind, but not especially drowsy, though seemingly rather unconcerned about what is to be done, this being the result of 20 grains of veronal taken in 5 grain doses at noon, at six in the evening, at midnight, and at six in the morning, preceding the operation. The individual so treated who will not succumb to the anesthestic without excitement or struggle, is not considered ready for any operative procedure and is, in our clinic at least, likely to be returned to bed for further study and preparatory treatment. It seems to us that in this way alone can a disheartening mortality be prevented. Veronal in 5 grain doses given over a period of twelve hours until 25 and 30 grains, respectively, had been taken by Mrs. J. and Mrs. K. kept them quiet and listless on the table although they were not asleep and they responded readily to all questions. They were quiet and drowsy for the next few hours. Both had been regarded as slightly toxic cases.

Veronal is no more *universally* ideal than is any other drug when used for "preanesthetic administration." Its more disagreeable effects which we have noted are:

1. It renders many individuals so dizzy that they fall out of bed when they raise themselves up and reach out over the side of the bed for some desired object. We never give it without applying "sideboards" at the same time.

2. It causes many patients to become positively irrational in a few hours after its sedative effect would naturally be expected. Experienced nurses tell me that they always dread to see it prescribed, having this particular effect in mind.

3. It produces retention of urine in a large percentage of those to whom more than a most moderate dose is administered.

In fact, one must catheterize far too many of those in whom a satisfactory preanesthetic effect is secured.

4. Nausea and even vomiting develop in a certain number of those who take enough of it to produce any definite result. Usually these manifestations have worn off before the operating room is reached, and there is no vomiting during the ethylene anesthesia as is nearly always the case when morphine is used with that gas.

5. The duration of its effect is sometimes disproportionately long when compared to the period of its usefulness. An occasional patient will manifest symptoms of intoxication for about one week after the last dose.

6. It seems to be more potent the older the patient, therefore we feel that its administration must be watched if it is to be used at all in elderly patients.

**Luminal.**—Since the foregoing was written and after extensive experimentation with chloral hydrate, paraldehyde, bromides, veronal and luminal, the conclusion was reached that luminal, while not an especially powerful hypnotic, presents fewest disadvantages. Its effect upon the patients differs widely. The higher the metabolic rate, the more rapidly it seems to be consumed, consequently the more is required. Thus one will see the necessity of establishing the patient's tolerance for the drug before the actual preliminary preparation.

When the patient enters the hospital several days before the date set for operation, she is given 1½ grains of luminal every eight hours during the first day, and its effect is noted. The next day the dose is slightly increased, and it is administered every six hours or every four hours depending upon the patient's reaction. The amount that is well tolerated and that will keep the individual in a drowsy state is thus determined and is administered in such dosage during the preliminary preparation which begins twenty-four hours in advance of the operation. Some tolerate it every eight, six, or four hours, and an occasional patient will tolerate it every three hours without too profound an effect if given only during the twenty-four hours preceding operation. The average dosage is 1½ grains every eight hours.

The drowsy state maintained during the tolerance test is

beneficial, as the excitement caused by change of environment, anxiety and fear over the impending ordeal is reduced to a minimum; less energy is expended in tossing about during sleepless nights; strength is conserved and the body toned up in general.

The various sedatives which we employ with so much benefit in toxic goiter patients may be said to resemble the fabled two-edged sword in rare instances. Many examples are mentioned elsewhere on these pages of extensive use of luminal, veronal, chloral and morphine. Unusually large doses have at times been employed without untoward consequences, but in this connection it is strongly urged that the effects of these drugs are always to be most carefully watched, since an occasional patient may have her life endangered by the employment of what is ordinarily considered a conservative dose of any one of them. Mrs. C. (August, 1924) was given nine grains of luminal in one and one-half grain doses during thirty-six hours which preceded the thyroidectomy. One-fourth of a grain of morphine was administered just after she left the operating table and for about twelve hours her respiration was exceedingly slow or else of the Cheyne-Stokes type, her pupils were of pin point size, her lower jaw had to be held forward and her chest wall frequently irritated in order to make her breathe at all. She was sixty-three years of age, with a metabolic rate of 37.8 plus, still there was no other interpretation possible except an idiosyncrasy to morphine. Nor was this all—the same thing would appear to have held good for the barbituric acid compounds alluded to above, for it was fully three days after the operation before we could completely arouse her or induce her to drink and respond in the ordinary way to the various stimuli which one encounters in a normal convalescence.

**Morphine** must be given as a preliminary to the dream state if the patient be a muscular individual or one who has lost will power and self-control to any marked extent. On the other hand, a naturally quiet patient with marked loss of muscle tone (Mrs. W., October 24, 1921) does better without than with it. This woman vomited for many hours after removal of one lobe with morphine preliminary, but not at all three days later when the second side was removed without it.

During the days previous to operation we try a small dose of morphine to determine the effect and repeat it at intervals to obtain a knowledge of the morphine tolerance, as well as the dosage required to produce the desired effect during operation. The dosage of morphine is regulated by the basal metabolism, it being a known fact that the higher the rate and greater the toxicity of the patient, the greater the tolerance for morphine.

An astonishing amount of morphine may be employed without satisfactory effect. One girl had a rate of +75 and was very hard to handle, but the morning of the operation she was given ½ grain hypodermically at eight, eight-thirty, nine, and nine-thirty, also one grain at ten; then three grains having been given, she was operated upon without gas at eleven o'clock after the respiration had come down to eight or ten to the minute. She was not at all cyanotic during the procedure, nor could the blood color be said to differ from the normal. She was awake all the time, never ceasing her complaints. I am by no means to be understood as championing such heroic doses, but I merely cite this example to prove that extreme tolerance to morphine may be expected with a high metabolic rate. It must be highly dangerous to give enough to really *quiet* such a patient; therefore the only alternative until recently has been *no surgery,* since a complete general anesthesia of whatever sort on a highly refractory patient is equally hazardous. At the suggestion of Dr. Frank R. Fry, a neurologist, to whom I appealed for an opinion regarding the applicability of hyoscine in these patients, I carried out a series of clinical experiments which have resulted in the adoption of the following routine in our clinic:

One dose of $\frac{1}{200}$ gr. of hyoscine and ¼ gr. of morphine is given an hour before operation to the patient who is not toxic or only mildly toxic. In the really toxic patient (exophthalmic or toxic adenoma case) two such doses are employed, one given an hour and a half previous to operation, the other half an hour previous to operation. In few instances has this preliminary medication failed to secure a perfectly quiet subject. Often the patient is awake when placed upon the table, and can in every instance be easily aroused, but I have never observed any apprehension or excitability. I have seen no ill effects from this some-

what heroic medication when the dose has been carefully chosen to fit the degree of toxicity.

If ethylene gas is the routine anesthetic in a goiter clinic, it is necessary to revise the preanesthetic preparation. Morphine can no longer be employed on account of the persistent nausea and vomiting which follows its combination with ethylene.

We use gr. $\frac{1}{150}$ of atropine given with the first dose of morphine and hyoscine. Atropine serves to keep the throat free of mucus during the operation, as well as to insure heart protection against vagus nerve damage.

An operation should not be considered so long as hypersecretion is left in a larynx or trachea after acute infection of them. Miss U. (January 31, 1922) had a moderate amount of mucus before lobectomy. The mere manipulation of these viscera under gas and infiltration caused an unbelievable increase in the amount of mucus at once. There was an outspoken bronchitis in a few hours which developed into bronchopneumonia twenty-four hours later with death in forty-eight hours. This was a toxic patient who had never made a satisfactory recovery from ligation, with whom less than the usual risk was permissible.

## General Anesthesia

There are many reasons why deep ether anesthesia is no longer employed as far as I know for thyroidectomy in the best known goiter clinics. It is scarcely necessary to more than enumerate the well-known objections to the use of this anesthetic in our field. One may mention the undesirable stimulation of a toxic patient by it, as well as the great likelihood of respiratory complications following its use here where they are not unknown under most favorable circumstances as far as anesthesia is concerned. I have seen complete collapse of the trachea twice with the patient deeply under ether, in one instance with fatal issue, which might, I suppose, have been averted by the prompt introduction of an intratracheal tube. The second patient recovered spontaneously from threatened suffocation just as she had done on one occasion preceding the

operation. One may safely say that the more surgeons use ether, the more they are sure to desire another method.

The very sick patient must be protected against psychic shock by gas at every stage. She must never know when the infiltration is done. The patient who receives gas and infiltration has little more than normal slumber, not an anesthesia. She can be awakened at any time and the eyelids move throughout the operation.

Our "dream state" which "masks" an infiltration is satisfactory as long as the dreams are agreeable, the result of fitting psychic, hygienic, and medicinal preparation, to say nothing of the efforts of a charming, sympathetic anesthetist. The dream is not to be disturbed by any technical break; something which is unavoidable unless a perfectly organized team has had experience together in this special field.

No highly *toxic patient* should ever be taken *wide awake* to the operating room to begin general anesthesia, provided one be contemplated.

Crile sometimes starts the anesthetic in the patient's room. In a general hospital where goiter patients cannot be on the floor with the operating room, it is difficult to carry out this procedure, owing to the inconvenience of transporting the gas apparatus, and the likelihood of the patient's awakening during removal from bed to operating room. In our clinic when such protection is absolutely necessary, we prefer the use of preliminary drugs to the extent of rendering our patient rather oblivious to the change of location.

There is a marked element of uncertainty about a general anesthesia in a toxic patient, even where gas is employed and in the hands of an expert. I have seen two sudden, wholly unexpected deaths on the table from gas used in ordinary (90 per cent) concentration as used by dentists, but the 50 per cent and 5 per cent mixture of Crile called by him analgesia is quite another matter. As an example, Mrs. K. (June, 1921) had a difficult, lengthy thyroidectomy after ligations and x-ray; she talked to us all through it, never complaining, never moving, and she was in perfect condition afterward. She had 1 per cent novocaine and ½ grain morphine, which combination is my choice by far.

One of the chief objections to general anesthesia is the frequent occurrence of cyanosis, which in turn causes hemorrhage. Struggling and cyanosis are very likely to cause bleeding at some time when any general anesthesia is used. The causes of cyanosis are given below, many of them it will be seen can be eliminated by the careful operator. They are (1) neck tumor pressing on blood vessels; (2) head thrown back, obstructing the trachea by distortion; (3) ether causing a profound sleep and inhibiting proper function of reflexes; (4) too much morphine; (5) toxemia; (6) the heart often imperfect in goiter patients; (7) obstruction of trachea by operator by manipulations or pressure of instruments; (8) obstruction of trachea by the patient's own excessive secretion; (9) rough retraction causing pressure on the vessels of the neck. Cyanosis throws a load upon the heart that sometimes proves serious. An operation attended with cyanosis which cannot be relieved must be terminated though it is incomplete, in order to avoid a circulatory or respiratory breakdown.

The gas must be kept just deep enough that the patient will not vomit during the operation from the effects of preliminary morphine as so frequently happens after the ordeal is over and the gas mask is taken away. Nothing is more trying to the surgeon than the muscular movement and cyanosis occasioned by vomiting during a thyroidectomy.

### Infiltration

It is never really necessary to employ infiltration in conjunction with ethylene, since a complete anesthesia of any desired depth (and more—a dangerous one) can be secured under it alone, but a bloody field absolutely characterizes its use, often to the extent of rendering accurate technical details impossible of execution. This is not only most embarrassing for an operator, but can readily predispose toward the collection of blood in tissue spaces that are tightly closed before the anesthesia is interrupted. A very small amount of any general anesthetic will suffice for the traction and extraction which produce the only form of serious discomfort not entirely controlled by a properly administered infiltration, and less bleeding will be

produced by the combination than by the gas if employed from start to finish.

**Infiltration under Partial Gas Anesthesia.**—It was long ago shown by Crile and others that nerve block protects the central nervous system against *shock impulses* which come through under full anesthesia, one of our reasons for using infiltration. Many goiter patients are too sensitive to be infiltrated and operated upon while wide awake; therefore these are so treated in the dream state which Crile calls "analgesia" and in this way protected against psychic shock, so-called. I am sure that most of them never suspect that a local anesthetic has been used. Still many of them have been so little under gas as to recollect sounds which they heard in the operating room.

I am quite well aware that the point of view of the goiter surgeon may not wholly coincide with that of a professional anesthetist who is an expert in producing his anesthesia by local means. His object is simply to render a field insensitive, whereas the one whose paramount object is to cure a toxic thyroid patient merely makes the infiltration a means to an end; therefore he is very little interested in how he is enabled to get the goiter out, provided only that this is done with the minimum of psychic and physical damage.

**Infiltration Technic.**—Our technic of infiltration, as will be remarked by studying the accompanying illustrations, is extremely simple. We have gradually simplified it until, as will be seen, all the injections made preliminary to the anesthesia are given through one single needle puncture opening. (Figs. 32, 33, and 34.) There seems to be a certain advantage in puncturing the skin but once. Certainly asepsis is favored in this way, as we have no means of sterilizing the deep skin layers through which the needle must pass on its way to the distant areas involved in an extensive infiltration. I agree with Crile in the feeling that a very light nitrous oxide, or as preferred by many others, a light ethylene anesthesia, shall have progressed to the point where the patient will not notice an ethyl spray on the skin before the initial puncture is made.

We do little more than anesthetize the skin, fat and muscle planes in front of the gland before making the incision, inject-



Fig. 32.—Ethylene spray on skin protected by nail head; this protected spot remains soft in the center of an anesthetized area.

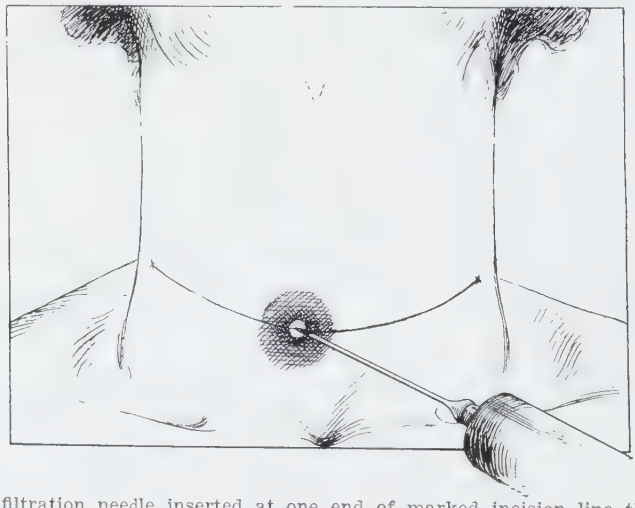

Fig. 33.—Infiltration needle inserted at one end of marked incision line through soft anesthetized area.

ing the gland liberally after the neck is open (Fig. 35). (See also Fig. 48.) Our object in making the infiltration of a structure after it is exposed is simply this: it is very much more

accurately and safely done under the guidance of the eye. I have seen very serious respiratory difficulties develop from massive infiltration of all the structures of the neck before the skin incision, something not at all likely when all but the point of the needle is always in view. I have on more than one occasion seen patients under such circumstances cough and spit up anesthetic solutions which had been injected directly into

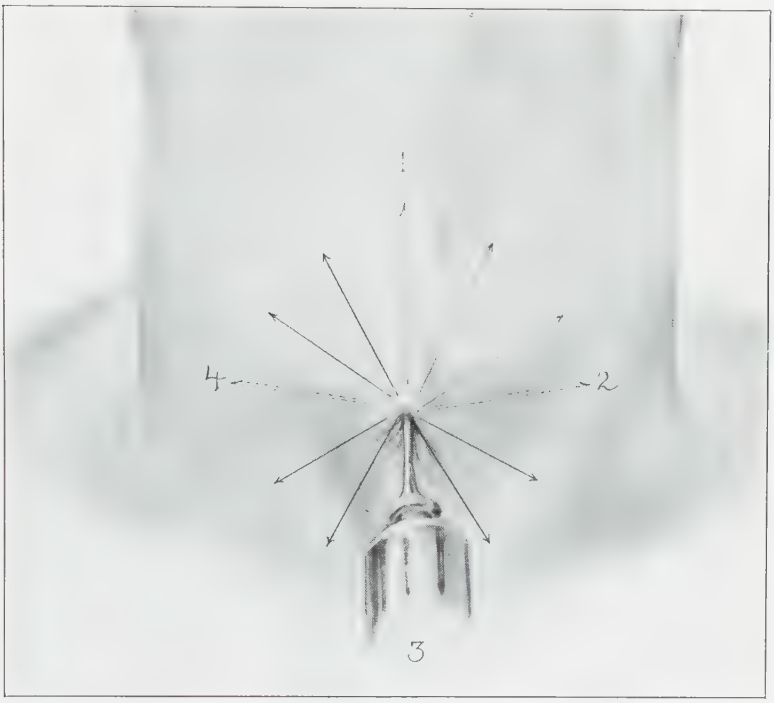


Fig. 34.—Ideal operation. Here is shown the infiltration needle inserted in the different directions required to produce sufficiently extensive anesthesia for skin incision and elevation of skin flaps.

the interior of the trachea, an accident which is surely not conducive to asepsis. I have observed sudden loss of voice on account of supposed blocking of both recurrent nerves, and it is well known that serious accidents have occurred following the accidental injection of solutions directly into the great veins of the neck. It surely requires no expert knowledge to enable one to infiltrate the planes as he comes to them with the superimposed tissues divided and retracted; this method, therefore,

seems to possess every advantage, no matter whether or not the infiltration is masked by light gas anesthesia.

The introduction by Goetsch of the adrenalin test for hyperthyroid patients has demonstrated very clearly that it is highly dangerous and no longer allowable to employ the time-honored four drops of adrenalin to the ounce of ½ per cent novocaine as a local anesthetic in such cases. Experimental work inspired by the above consideration has shown me that there is really very little difference between the effects of a four drop and a

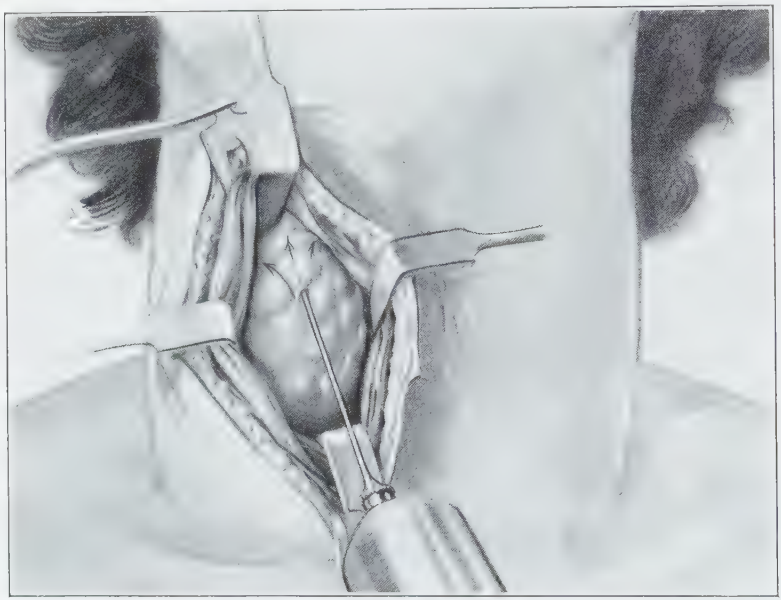

Fig. 35.—Region of the upper pole is tightly infiltrated as are other portions of the lobe not shown in drawing.

two drop to the ounce solution. To be sure I have seen the skin of the neck perfectly anesthetic two hours and twenty minutes after the use of four drops to the ounce as infiltration for a goiter operation; a needlessly long period in view of the fact that no patient should be kept on the table while awake (or asleep for that matter) for any such length of time. In one case, on the other hand, the skin of the same region which had seemed particularly sensitive before infiltration remained wholly without feeling for more than fifty minutes after the use of only *one* drop to the ounce. This experience cannot fail

to interest the surgeon who is convinced, as I am, that wound healing is often prejudiced by the ischemia consequent upon the unrestricted use of adrenalin, four drops to the ounce when the use of one or two drops would have been equally as satisfactory though not bolstered by the prestige of tradition. My own experience with novocaine solutions alone in hyperthyroid patients differs somewhat from the commonly accepted belief. The ½ per cent solutions of novocaine have been effective for only three to five minutes or thereabouts. Still we are here not particularly concerned with the duration of the effects of infiltration, since the cutting is all done in freshly infiltrated tissue and a little reinfiltration for closure is a simple matter; then, too, a bit more gas helps the patient over any particularly painful procedure.

The infiltration of a goiter region has been wonderfully facilitated in our hands by the use of the Dunn double acting syringe, considerable time being saved by the automatic refilling feature of the device. Of course, our novocaine is always dissolved in an isotonic salt solution, still it must be admitted that comparison of two necks after forty-eight hours, one operated upon under general anesthesia alone, the other with infiltration, will usually tend to convince the observer that edema, tenderness and secondary collection of serum are much more common where local anesthesia is employed.

**Infiltration Anesthesia Alone.**—Now and then we do a thyroidectomy under infiltration anesthesia alone. This is usually done to satisfy the whim of a patient who insists upon remaining awake because she fears any degree of general narcosis. In rare instances a high degree of tracheal obstruction, cardiac damage or early inflammatory involvement to the respiratory apparatus makes it seem desirable to forego the advantages of the dream state which protects the patient against the infiltration trauma.

The toxic patient who is for any special reason to be the subject of an infiltration anesthesia alone, must receive very exceptional consideration, else the procedure is sure to react unfavorably even though the infiltration as such may in reality render the tissues insensitive. In the first place, such individuals are never fit subjects for clinical demonstration. It is posi-

tively necessary that the patient have a perfect night's sleep preceding the operation. We are accustomed to give such a patient an ordinary breakfast as usual, feeling that this does much to steady her for the ordeal. Of course, she may become nauseated or even vomit during the operation, but she is less susceptible to morphine, novocaine, or psychic influence with the stomach full of food. The room in which the operation takes place must be absolutely quiet, or what is better, some soothing sound, such as music, may, I suppose, with benefit be allowed to come in from a distance. This has been suggested by numerous writers, although I have had no experience with its hypnotizing influence. It is essential that the greatest possible supply of oxygen be present at all times, since the increased metabolic rate indicates the need of this element. With this in mind, we do many of these operations on screened hospital porches when the weather permits.

For the occasional patient who prefers to remain awake, the greatest discomforts are those due to (1) the hands being improperly restrained; (2) the face being covered; (3) insufficient air to breathe (physiologic need). It must not be forgotten, too, that morphine nausea and vomiting cause some patients more suffering on the table than does anything else connected with the operation. These discomforts may be eliminated by allowing some latitude for the hands; by placing a curtain at the neck held away from the face; and by the use of an electric fan to insure fresh air circulation. One can also materially add to the patient's comfort by (a) giving ice or water frequently; (b) by allowing frequent slight change of position; (c) by seeing that no weight is allowed to rest upon the patient; (d) by using sharp knives and needles, thus avoiding any undue pressure; (e) by making gentle, steady retraction; and (f) by having at the head a nurse who knows the work.

It may be added that the judicious use of veronal, chloral, and morphine as preliminary drugs will greatly diminish the group which seem unable to tolerate infiltration without a harmful degree of psychic shock.

Many really toxic individuals exert every effort at self-control when appealed to in behalf of a dependent child or other loved one, though certain patients simply cannot or will

not try to cooperate in a local anesthesia. They are not always highly toxic, but are often simply spoiled and selfish. In such cases it should never be recommended or persisted in.

It is no use to attempt the infiltration if the patient has not enough automatic self-control or morphine composure to let one make the skin mark scratch. One had better stop here and attempt to have the nervous apparatus better protected on another occasion. It is far more important that no operation be attempted on a patient who shows bad effects of any kind from the infiltration, since this may be far more than an indication of an improperly protected nervous system. It may indicate that novocaine in a toxic dose or accidentally introduced into one of the many important structures of the neck is menacing the life of the patient. (It is assumed that no capable operator will employ adrenalin in a toxic patient.)

General anesthesia for delivering the gland and treating the stump is by no means necessary in every instance. Mrs. G. (February, 1921) had the right lobe removed through lateral incision after right side infiltration only, when a projection the size of the fist was found leading down and to the left across the trachea. It was dissected loose and pulled up with no more discomfort than had been occasioned by similar work on the right side after massive infiltration.

I have used gas for a very short interval during luxation of a difficult retroclavicular or retrosternal goiter (no doubt ether might be employed in the same way) as an aid to local anesthesia in patients who preferred to have local anesthesia only.

In general it may be said that one must not fail to inject the upper poles and stump just before dividing them no matter how good the preliminary infiltration anesthesia may have been. Since doing this we no longer have to use complete gas anesthesia while we pull up the lobe. It also keeps the field remarkably free of blood.

A patient whose neck is to be left open needs but a very short anesthesia while cutting and retracting is taking place. The ligating, if carefully done, occasions the minimum of discomfort, therefore one can readily dispense with adrenalin in a toxic patient. Where no gas is employed, I infiltrate with

1 per cent novocaine, since a simple 1 per cent solution causes an anesthesia which lasts for twenty minutes in my hands. It may be of interest in connection with nontoxic patients to know as stated above that the addition of one drop of adrenalin to the ounce of 1 per cent novocaine has been found by me to render the tissues insensitive for about one hour. For those who object to so concentrated a solution I shall state that a rather exceptional patient, Mrs. K., was infiltrated with 10 c.c. of ½ *per cent* novocaine and 1 drop of adrenalin to the ounce. We obtained a perfect skin and deep anesthesia for at least fifty minutes, although she had been exceedingly sensitive to skin marking by scratch. This was for removal of the second lobe.

I do not often recommend thyroidectomy under infiltration alone, still when all its contraindications have been urged, one is forced to admit that he can at least be certain of not losing an infiltration patient on the table, something which cannot be said with certainty for ethylene or gas.

## References

Luckhardt, A. B., and Carter, J. B.: The Physiologic Effect of Ethylene, a New Gas Anesthetic, Jour. Am. Med. Assn., 1923, lxxx, 765.

Idem: Ethylene as a Gas Anesthetic, Preliminary Communication, Jour. Am. Med. Assn., 1923, lxxx, 1440.

# CHAPTER XI

## DETAILS OF TECHNIC

### SKIN INCISION

There are three primary considerations in making the thyroidectomy skin incision. They are (1) ease of access to the tumor, (2) cosmetic effect, and (3) functional after-effect.

So far as the first is concerned, an incision across the greatest diameter of the growth enables one to reach it with the utmost facility, but for cosmetic reasons one inclines to go a bit lower than this as a rule and thereby sacrifices relatively little of accessibility.

Some thyroidectomies are done purely for cosmetic reasons. In such cases a maximum consideration must be given to the appearance of the resulting skin scar. It is obviously unfair to a patient coming under this classification to neglect any consideration calculated to minimize surgical damage which might in a measure offset the improvement in appearance hoped for through removal of the thyroid.

The third consideration of resultant function is subserved usually when the skin scar is perfectly free of the trachea and is certainly taken care of when the patient experiences no drawing or pulling sensation upon swallowing.

One who determines the position and direction of his incision upon the operating table after the patient's head is thrown back and the field adequately draped sometimes awakens to an unpleasant surprise upon seeing the wound uncovered a day or two later; for this reason I advocate marking the line of incision when the patient is in a relatively normal posture, thereby avoiding one of the five classes of faulty scars.

The first type is placed so high across the neck as to be unduly conspicuous or so low as to cross the bones of the upper chest wall. The second class shows a curve entirely too acute and has the extremities pointing more or less directly upward. The third is asymmetrical when the two lateral halves are compared. The fourth is a midline vertical scar which seems to

me the worst of them all since I had the experience of excising a midvertical skin scar that had spread following suppuration. The result was relatively unsatisfactory as it could not be hidden in any way. The fifth, or the lateral oblique scar, which, although being undesirable as far as its cosmetic aspect is concerned, must now and then be made use of in what we have termed "simplified technic for unilateral thyroidectomy," is fully discussed in another chapter.

In a woman who has no strongly marked skin fold, and young women practically never have, the matter of importance is to so place the incision that its resulting skin scar can be accurately covered with a chain of beads, the intended position of which will have been marked before operation. It is not always necessary or even advisable to do preliminary marking of a collar incision along a chain, especially in the case of a man. If the patient has strongly marked cross skin folds, which is by no means always the case in women at least, it is better in marking to follow one of them accurately, than to employ the plan of marking the neck above a chain of beads, because there is no better way to hide the resultant scar than by having it lie in the depths of a deep natural fold.

In my own hands at least, the most satisfactory way of marking a neck, provided, of course, that the patient has self-control enough to tolerate a superficial skin scratch is this: have her sit up a day before the operation, allow her arms to hang at her sides so that she does not unduly raise her shoulders and at the same time elevate the clavicle; place a chain around her neck at the height preferred by her while looking into a mirror, and then make a fine superficial scratch with a very sharp needle just above the chain (Fig. 36) but touching it all the way round. This scratch is not deep enough to draw any blood at all but merely disturbs the epithelium to so slight an extent that it can scarcely be seen until some little time has elapsed. The next day, however, when it is desired to operate, a very fine distinct red line is apparent and can be followed with the greatest ease. In fact, such a mark persists for several days as has been noted on more than one neck on which the incision was not made as long as had been originally intended.

If the marking is done a few hours previous to operation,

pen and ink will be found more agreeable than a needle point and usually the ink will leave a sufficiently conspicuous mark up to the time the skin is scrubbed in the operating room and sometimes even longer than this. My desire to obtain a dye which should be reliable at all times led me to communicate with one of our large pharmaceutical houses, from which I secured the following advice:

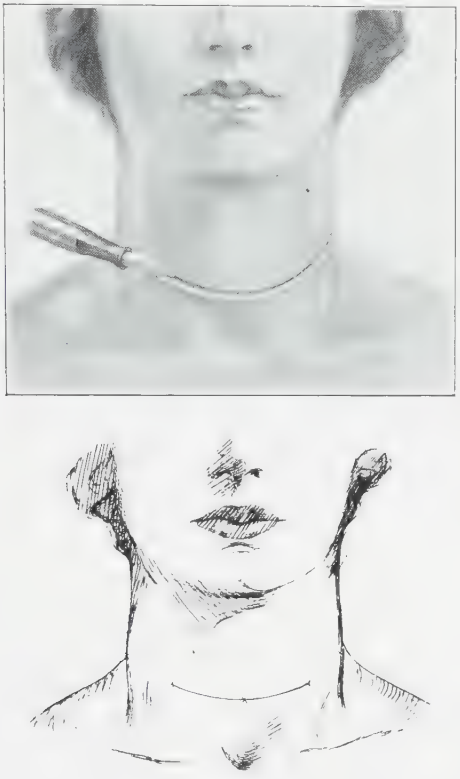

Fig. 36.—Ideal operation. Marking the intended collar incision site over a chain of beads.

"After making some experiments we believe that the best thing you can employ would be the dye ordinarily known as 'Malachite Green.' This should be applied in the form of a concentrated water solution and the ink should be allowed to dry. It should then be treated with a dilute solution of ordinary ammonia, which will precipitate the dye in the skin. We find that after this has been done, the skin can be scrubbed

with soap and washed with alcohol and similar agents without the removal of the color."

**Accuracy in Marking the Line of Incision.**—Accuracy in marking the path of the incision is a very important part of the technic, at least in so far as the esthetic appearance of the scar is concerned. Upon experimenting with a chain of beads and a needle or pen, one will find that if the mark is begun at the left extremity of the contemplated incision and carried on to the midline and continued on to the right extremity, the left, or beginning, point of the line will be higher than the right but the left half of the line will have a more shallow curve before reaching the midline, because of the lack of support offered by the chain when the marker is drawn toward the midline. The resultant scar of an incision carried through such a line would be the typical left cowhorn type of scar described elsewhere, which, of course, cannot be hidden. If the beads be held fairly tight, and the marker be drawn from the midline to the left extremity and from the midline to the right extremity, allowing it to be guided by the resistance offered by the chain, the resulting mark will be the correct line of incision, with both halves showing a similar curve.

It must be remembered in making the skin incision that the resulting scar will be much lower than an operator without experience would anticipate. The larger the goiter, the lower this displacement, for the same reason that a pendulum rises farther the more it swings out. It is unpleasant to have a skin scar cross bone at any point. Still a marked incision can always be covered by a chain, since no matter how low it slips, its parts maintain the original relation to each other.

The line marking the incision should always be made about one centimeter higher than is planned for the final scar which is to be covered by a necklace. The necessity of this is very obvious when we consider that the incision is made at the base of the tumor, with the result that the curved surface of the neck becomes a flat surface upon the removal of the tumor, allowing the scar to drop. We do not see the pendulous, cystic goiter here, often the result of long-continued neglect in some of the European highlands. For it this plan would be wholly inadequate. Mrs. C., who had been operated upon for large bi-

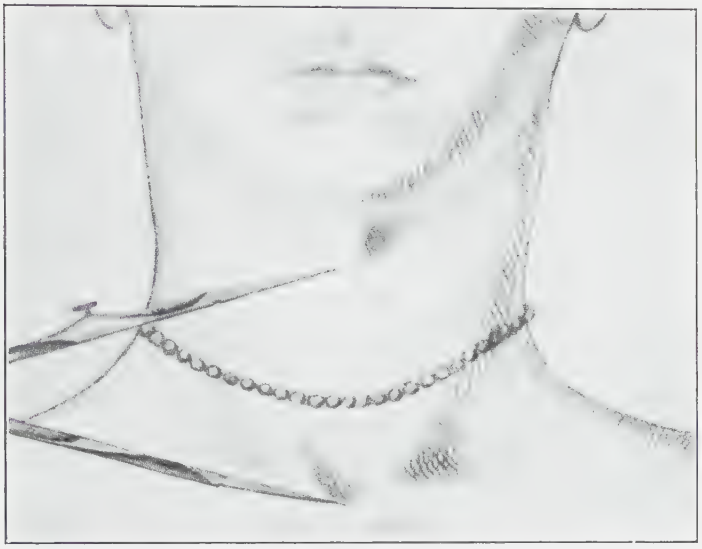

Fig. 37.—Ideal operation. A pair of calipers determine the length of the intended midribbon muscle split.

Fig. 38.—Ideal operation. The distance determined in Fig. 37 is laid off on the collar skin mark, thus determining its length.

lateral adenoma, three months later wrote that her neck was so badly wrinkled as to attract universal attention. It might be better in such an instance to remove a large crescent-shaped skin area, planning for the resultant skin edges to drop together without tension one or two centimeters above the clavicles.

The length of the collar incision is a matter of importance largely because one is inclined to go further than is necessary with it. One of adequate length should at first look relatively too short until the operator learns by experience that the skin of the neck is very elastic, and unless the patient be very stout,

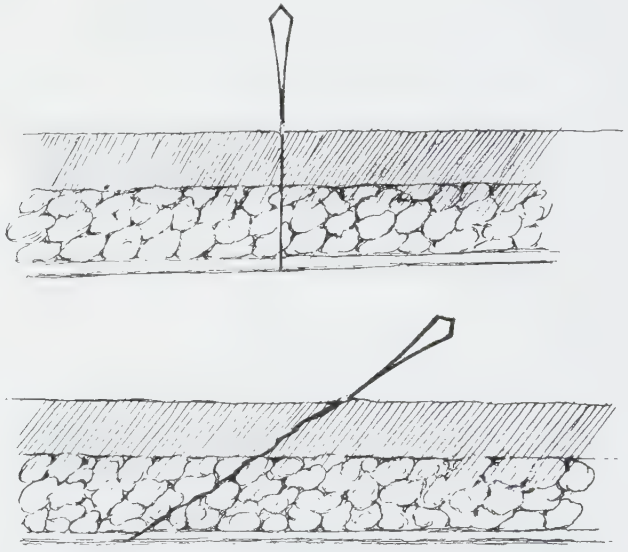

Fig. 39.—Ideal operation. The upper figure shows cross-section of knife held at a right angle to the skin plane, thus assuring an incision of the correct type.

The lower figure shows a knife blade meeting the skin plane at an acute angle; this results in an incision diagonal to the skin surface. A needlessly wide scar results from its healing.

the skin can be shifted to a surprising degree in any direction desired. The greater number of goiters are taken out through a midline ribbon muscle slit, the extent of which is limited by the distance between the hyoid bone and the sternum (Figs. 37 and 38); a skin incision which exceeds in length the line drawn between the two points just mentioned is unnecessarily long. If one contemplates division of the lateral ribbon muscles, the incision must, of course, be somewhat lengthened to allow more room at the base of the upper flap, but this feature is

being happily abandoned at the present time for all but the rather large goiters.

The use of an exceedingly sharp knife is essential to the making of an incision which shall follow accurately a predetermined line. A dull knife distorts the skin by pulling it out of position and the incision line in consequence is a crooked one. One should, furthermore, be very sure that incision is made

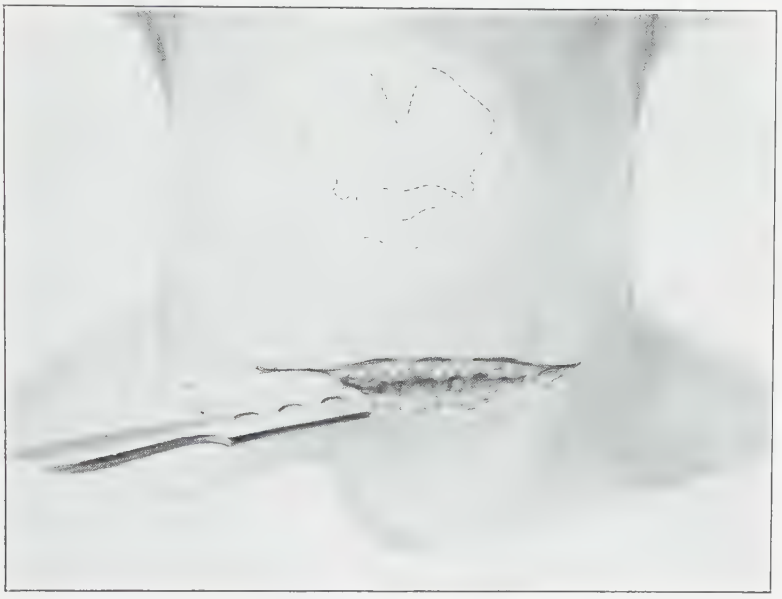

Fig. 40.—Ideal operation. The collar skin incision partly through the fat.

in a plane which meets the skin surface at an exact right angle (Figs. 39 and 40) in order to ultimately obtain the narrowest possible skin scar.

The postoperative phase of the improperly made skin incision is treated at length in the chapter on Complications. It seems to me that one who studies both phases of the subject at the same time will be impressed with the importance of this part of the operative technic.

## CHAPTER XII

## DETAILS OF TECHNIC—CONTINUED

### THE DIVISION OF THE PLATYSMA MUSCLES

The platysma muscles of the two sides are shown in the textbooks on anatomy as consisting of the two halves widely separated in their whole course below the chin. This structure in a muscular man is very easily identified as a fairly heavy layer continuous across the midline in practically every instance; whereas in a thin woman, it may in some instances approach its prototype of the anatomical textbook, especially low down in the midline of the neck.

This layer can with difficulty be lifted off the underlying veins, leaving them intact provided delicacy and accuracy characterize the dissection; however, vastly fewer vessels are encountered and time is saved by dissecting skin flaps alone instead of including the platysma with the original flap. In cutting skin-fat flaps, it is possible to follow with a sharp knife the desired plane (Fig. 41) immediately outside the platysma without control of the eye.

After making the short collar incision for a small goiter if quick work is desirable, slip a long knife blade under the skin of the midline, upward and downward, when you will be astonished to note the amount of exposure given by automatic retractors (Fig. 42) as the skin slips over the deeper layers. (See also Fig. 85.) This gives plenty of room for a mid-platysma-ribbon split and avoids almost all veins (superficial). It leaves the fat rough and the flaps of uneven thickness, but the inequalities fall into the surfaces they left, so that this is inconsequential. It shortens the operation by (a) few clamps; (b) few ligatures; (c) no platysma sutures; and may give a narrower skin scar because closure is in one plane.

It was very early impressed upon me that unless care be taken the operator is prone in elevating the upper collar flap to cut back through the platysma into subcutaneous fat at many points; therefore in the course of time I came in emergency

cases to pay no attention at all to the platysma in making the original flaps (collar), so the present system gradually evolved itself.

Careful inspection of the neck of a very thin woman will convince an observer that the cosmetic result is prejudiced by any cross division of the platysma muscles, since the upper flap never looks like the lower after complete healing. Its nerve supply is divided and in consequence it atrophies and smooths



Fig. 41.—Ideal operation. Undermining the skin flaps.

out. So fat, after all, is the determining factor in appearance; by accurate suture of the skin we get it together well enough for practical purposes.

So far as any specific function of the platysma is concerned, I think that we may disregard a consideration of this kind since no appreciable improvement follows the complete removal of this thin sheet as is practiced in the radical complete dissection done for cancer of the lower lip. One is forced to conclude, if he agrees with what has gone before, that the platysma muscle

may be practically disregarded as a separate layer when attempting to expose the thyroid gland.

It is excellent practice to divide the platysma along with the ribbon muscles in the midline in an operation of the ordinary variety or in those rare instances where the ribbon muscles are divided in some other direction, there seems to be no good reason that the platysma should not be treated in the same manner and cross-cut in the same plane with them. The positive advantages of the procedure have been stated in detail.

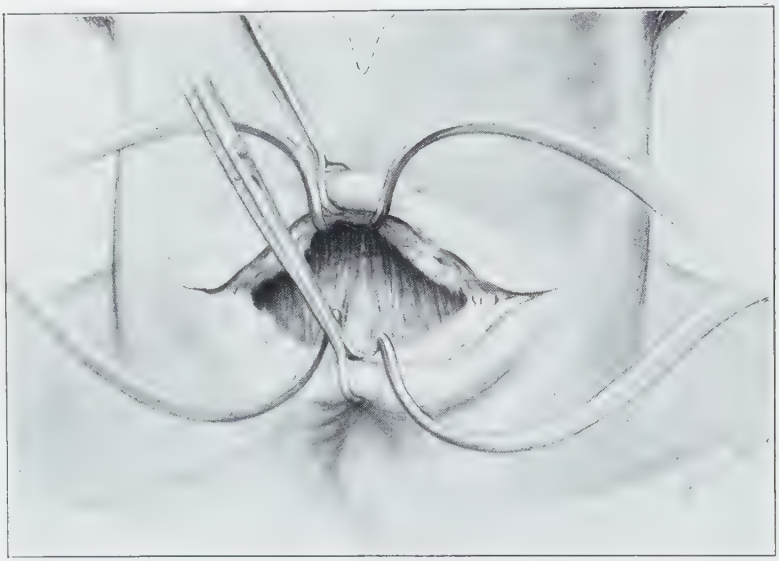

Fig. 42.—Ideal operation. Elevating the skin flaps with fat attached from the platysma muscles, using automatic spreaders or the single automatic spreader shown in Fig. 85. Intended midmuscle split shown by dotted line.

## THE RIBBON MUSCLES

The diamond-shaped space described in anatomy textbooks between the ribbon muscles in the midline of the neck anteriorly has never been noted by me. On the contrary, all goiters of medium size or smaller have been found covered with a definitely thick muscle layer which can be traced up and down the midline even in nonmuscular women; in other words, the sternohyoids seem normally to be separated only by a very thin layer of connective tissue. This cleavage plane is extremely difficult to locate in most instances, the best guide to it being, of course,

the hyoid bone and the jugulum. Where the growth is unilateral, however, the muscle midline is practically always pushed to one side but never widened.

Dr. R. J. Terry, Professor of Anatomy at Washington University, refers to this diastasis between the sternohyoids which is encountered in the literature only "as the product of dried out anatomical material as well as of tradition."

It is rarely necessary in doing thyroidectomy to make any incision in the ribbon muscles other than a split in the midline, longitudinal with the direction of their fibers. Such an exposure

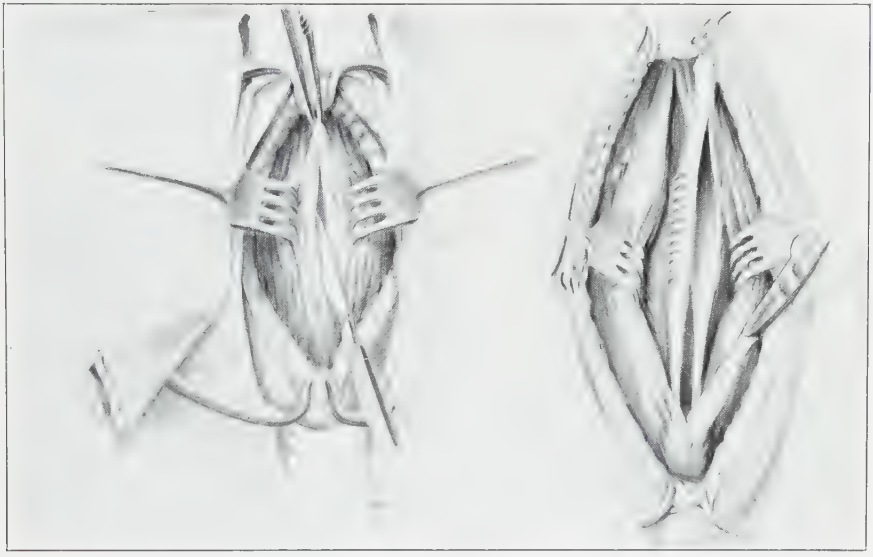

Fig. 43.—Ideal operation. Making the midribbon muscle split to expose the thyroid.

permits the delivery of all but very large goiters provided, of course, that the patient be anesthetized and that there be no adhesions. It is my custom to begin this midline split about the halfway point (Fig. 43) and then work in both directions, securing the advantage in this way of easy and accurate hemostasis at both the upper and the lower end of the incision, while its edges are rather widely separated from one another.

After the ribbon muscles have been separated from the anterior face of the goiter, it is an excellent idea to fix them in this position with a gently acting automatic spreader. By so doing, the second assistant is free to hold his retractors just

where they are needed at the moment and to change about as the operator proceeds.

If there is any special difficulty in getting at the upper pole, the surgeon may find an advantage in departing from a midline muscle split and employing the Halsted incision between the sternohyoid and the upper belly of the omohyoid. There is, however, the quite obvious disadvantage attending the use of such an incision; namely, that it has to be made double, and of course, entails an extra suture line on the second side. The Halsted incision is of undoubted value and should always be preferred in the removal of a second lobe at a period remote from that of the first resection. In this way one avoids the old scars which so attach the remaining lobe to a midline muscle union that it is often utterly impossible to begin a dissection at this point.

In making a lateral ribbon muscle incision or indeed in approaching the field of a remote superior thyroid ligation through any incision, for that matter, one must be most careful not to injure some of the adherent superior thyroid veins. This is a particularly disagreeable accident if the exposure is imperfect, but can usually be avoided by care and adequate retractors.

Cross-cutting the ribbon muscles is ordinarily not indicated. Union is probably never complete, and the final result is usually a flattening of the front of the neck. However, Mrs. P. (December 7, 1924) is an example of those short thick-necked patients in whom cross-cutting of the ribbon muscles is definitely indicated because of the relationship of the size of the goiter to the contemplated incision for its removal. The largest circumference of this patient's neck is 48 cm. as contrasted with a normal circumference of 35 cm. The distance from the manubrium to the cricothyroid notch is 5 cm., as opposed to an average normal of about 7 cm. in ordinary posture. The lateral circumferential dimension of the goiter is 22 cm. The difficulty of removing a goiter representing a cross measurement of about 22 cm. through a vertical slit only 5 cm. long is obvious.

When the subject is a man, one may be pardoned less care in cutting the ribbon muscles transversely than in the case of the opposite sex, since an ordinary shirt collar will cover adequately any deformity. It is better to cut the ribbon muscles

when the goiter is a very large one, this being especially true where there is marked respiratory difficulty or where a portion of the lobe lies retrosternal as it did in one of our cases (Mrs. B., July, 1921). In the case of a very large goiter all of the muscle structures in front of the thyroid are so thinned out and lacking in function that the direction of the incision through them is really a matter of no consequence, hence distinctly inferior to the consideration of easy and adequate access to the goiter.

In no instance do we apply transverse crushing clamps when we cross-cut the muscles, thereby destroying a considerable margin and thus shortening them for reconstruction. On the contrary, we catch each bleeding point singly as we go across them and then if time permits, we attempt to make the closure as nearly anatomically perfect as possible.

The transverse cut is supposed to be made above the point of entrance of the nerve supply to these small muscles, therefore atrophy of the portion above the suture line is inevitable, producing a marked flattening of the neck. Sometimes this goes so far as to constitute a real deformity.

The operator who leans toward nicety of detail will, I think, be inclined with increasing experience to take out more and more goiters through a midline ribbon muscle split, excepting in the somewhat unusual instances which have been mentioned above.

## THE UPPER POLE

Adequate preliminary division of the upper pole is the key to success in displaying the gland and doing thyroidectomy, since the tumor cannot be properly exposed and mobilized until its attachment is severed. Especially is this true of intrathoracic goiter, as will be noted later. In any but intrathoracic goiters in most instances, the rest of the resection is comparatively simple, once the pole and vessels entering it have been completely divided.

Crile greatly facilitates the luxation of the upper pole by completely dividing every accessible connection with the trachea as a first step. This may be commenced in the midline above the isthmus over the trachea first, then carried upward in both directions.

In small goiters, no retraction is needed about the upper pole other than that secured by catching all muscle coverings with small sharp retractors on the cut edges and lifting the edges; the superior thyroids can then be divided with slight traction discomfort, and the lobe lifted out.

In large goiters the pole tends to grow up into the neck to a very much higher level than the insertion of the superior thyroid arteries, therefore this overlying tissue is best brought out forcibly before the vessels can be exposed and divided.

After a preliminary ligation it is often difficult to loosen the upper pole from its bed. This is particularly true if the thyroidectomy is attempted within a few weeks after ligation and before massive adhesions become scars which have accommodated themselves to the movements of the gland in swallowing. As a matter of course, wide exposure of the upper pole, injection or wound packing, all augment the amount of scar tissue to be encountered.

There are many instances in which the upper pole cannot be sufficiently delivered to permit of dividing the superior thyroid vessels (Fig. 48) merely by grasping it with some type of forceps or by lifting it and inserting a finger or instrument under its outer border. Forceps of whatever type are very likely to tear thyroid tissue, and such a pole may run so high up into the neck that it cannot be adequately controlled by any form of elevation attacking the outer side. We have in such instances been uniformly successful in the employment of a hook-like, curved, blunt dissector (Fig. 44) which is cautiously and gently inserted between the larynx or trachea and the upper pole so deeply as to more or less completely embrace the pole which is then lifted directly toward the ceiling, while at the same time retraction of the ribbon muscles is momentarily increased to the maximum in an upward and outward direction by a straight elevator (Fig. 45) thrust under the outer edge of the pole. In other words the pole is, so to speak, "pinched out" of its bed between two instruments which meet behind it and while they lift it forward, displace its coverings so that not only its attachments are stretched and handled with the greatest ease, but at the same time the entire pole is brought well up into the clear instead of being torn into. Most opera-

tors will agree that this accident of tearing into the upper pole is the most common cause of too much thyroid tissue being left behind and of a recurrence thereby rendered likely.

From a technical standpoint the really serious part about tearing off a large section of the upper pole is that once separated, such a fragment retracts deeply into the upper neck and is most difficult to remove without undue division of its muscle coverings. This comes about because such a fragment cannot be readily grasped and drawn downward, since all types of forceps will cut and tear through it once the continuity of its capsule has been destroyed. The intact upper pole presents in its continuity greater tissue strength than do the normal

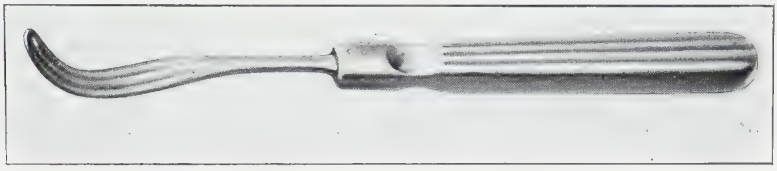

Fig. 44.—The curved elevator.

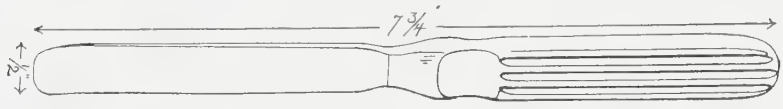


Fig. 45.—Straight elevator which is used in pinching out the upper pole when opposed to the curved elevator shown in Fig. 44.

attachments about its extremity, or at least these latter are so elastic that the whole structure can be readily exposed so long as it is one piece, while a detached fragment may be completely overlooked in the profuse bleeding which follows rupture of the gland. An elevator must be thrust between larynx and upper pole with extreme gentleness if no damage to the superior and inferior thyroid nerves is to occur.

After the superior pole is well divided, it can be tipped up into the vertical direction, drawn through a "buttonhole" in the ribbon muscles, then the stump controlled with great ease.

Reference has been made to intrathoracic goiter. The importance of dividing the upper pole before attempting the removal of such a growth is perhaps best illustrated by Pemberton[1] as follows:

"The first step in removing the intrathoracic goiter is freeing the *superior pole* by dividing the superior thyroid vessels between double clamps. These vessels are tied immediately, in order to rid the operative field of the presence of the forceps, which, if left, might be pulled off during the course of the operation, resulting in troublesome bleeding." The danger of tearing the inferior thyroid artery by attempting to "pry up the intrathoracic portion before dividing the inferior thyroid artery" is ever present. Pemberton feels that it is well to resect a large cervical tumor if present on the side opposite the intrathoracic projection in order to facilitate the removal of the substernal tumor.

The reverse of this procedure is sometimes in order since an upper pole can often not be displayed because it not only runs very high, but tends to envelop the larynx and esophagus posteriorly. Elevation of the lower pole first enables such an upper pole often to be slipped down and out as it follows the rest of the lobe while it is rotated on its tracheal attachment. This had to be done on the second side in one of my cases.

## DISPLAY OF THE GOITER

If the overlying divided ribbon muscles are retracted, and the goiter capsule distended with the anesthetic solution, the operator will be astounded at the manner in which the gland will tend to deliver itself out of the depths of the neck. This infiltration may prevent a sudden discharge of much secretion in handling, just as a cyanotic kidney is unable to produce a normal amount of urine.

The most refined and least bloody way of displaying the tumor is by dividing the superior vessels first between two forceps, then gently elevating the proximal pair and working under the upper pole until the mass is so free that the pedicle can be isolated by continuing around the side and downward.

The best instrument that I know of for pulling out the goiter is the many-toothed tenaculum forceps (Figs. 46 and 47). It must be applied to the intact capsule only, as no instrument will hold an exposed thyroid parenchyma under tension. Usually the soft, compressible, easily moulded gland may be

grasped with tenacula; others never should be; every instrument cuts through them and embarrassing bleeding results; therefore the qualities of hardness, friability, brittleness, etc., contraindicate this method of handling goiters. Experience

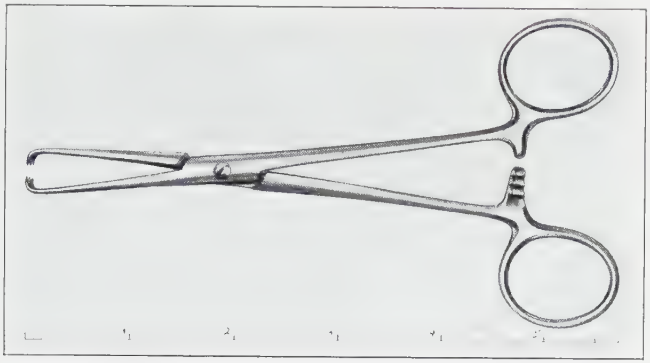

Fig. 46.—The fine-toothed tenaculum forceps which is employed for grasping and lifting the goiter.

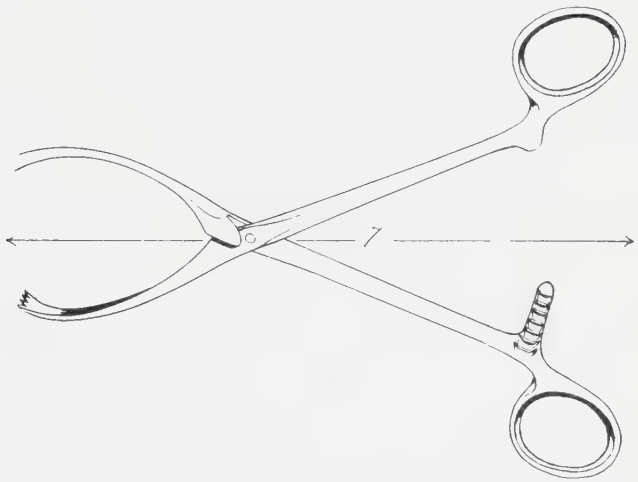

Fig. 47.—A strong, fairly heavy type of toothed forceps which will not cut through friable goiter tissue when tightly grasped because the blades are so greatly bent.

alone tells the operator how much pull may be exerted upon a tenaculum before it will tear through the tissue of a given goiter. Reflexes must be so cultivated that one's inhibitions guard him against doing unnecessary damage.

Drawing out a tumor mass with a tenaculum is not likely to produce any of the respiratory disturbances and cyanosis so

often seen when it is pushed forward with a thick finger which has been inserted behind it into a space too small to be invaded without the risk of damaging the important structures therein.

There are other reasons that one or more fingers of the operator's hand should not be used for roughly tearing out the goiter. Pushing or luxating with the finger often produces bleeding which is difficult to control because the source is obscured. Of course the use of the finger is necessary in some cases of substernal and subclavicular goiter. Again, luxation with the finger hooked in behind the goiter may cause injurious traction or "recurrens" or may cause hemorrhage which will destroy the parathyroids.

Formerly it was the custom of Crile and Lower[2] after exposure of the gland, to slip the forefinger behind or below or above the gland and bring the deeply lying gland into view. They feel, however, that in cases in which considerable force is necessary to dislodge the gland, the "traction, pressure and stretching" of the laryngeal nerves may block the passage of nerve impulses, thus causing bilateral paralysis of the vocal cords, rendering tracheotomy necessary because of inhibition of air intake. Should only partial paralysis occur, postoperative respiratory distress may necessitate reopening of the wound or tracheotomy.

After the upper pole has been lifted out of the wound (Fig. 48), one may proceed downward, dividing the lobe from the trachea until the lower pole is reached; however, I think most operators find it better after freeing the upper pole and lifting it towards the ceiling, to proceed along the outer edge of the gland, freeing it from muscle strands and dividing the communicating veins, then lifting the lower pole out with the tenaculum until the trachea can be seen and felt. Usually connective tissue strands surrounding the communicating veins of Kocher require division and ligation. Sometimes if inconspicuous they are ignored and the subsequent steps of the operation carried out as if they did not exist. In this way the plane in which amputation is to be made is very easily established under the guidance of the eye. The further procedure used

in our clinic is described in great detail in Chapter XIII, The Actual Resection.

Several elevators used in much the same way that a laborer employs his crowbar, if applied at one time, will lift out of the depths (Figs. 49 and 50), with no rupture of it or hemorrhage, a lobe which would be torn to pieces by any form of traction

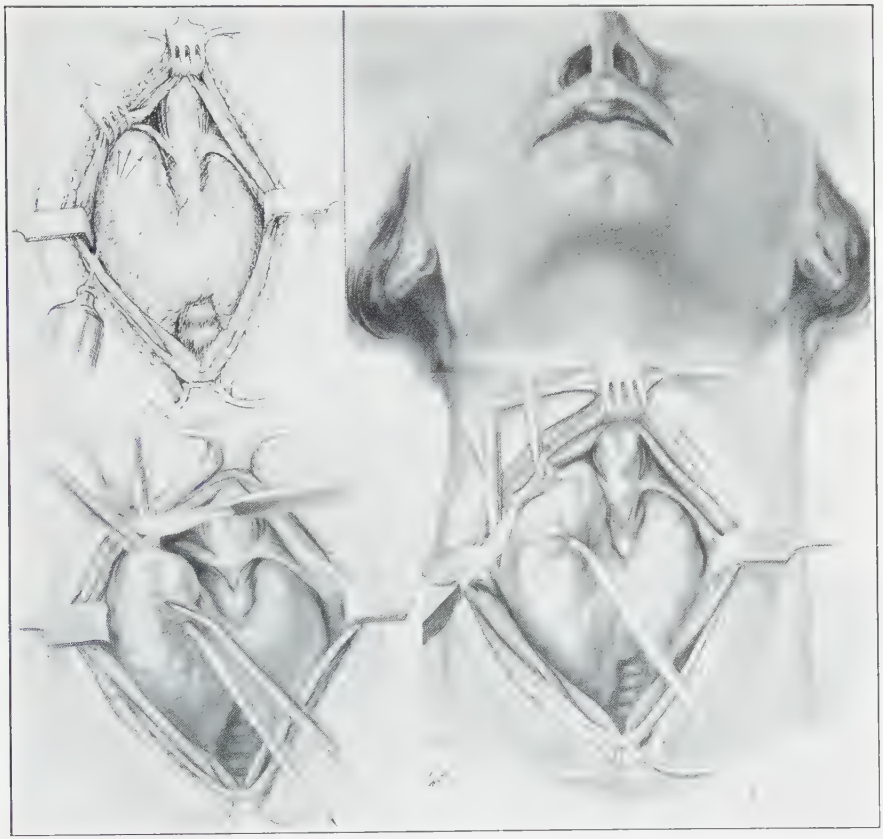

Fig. 48.—Ideal operation. Upper left-hand figure shows infiltration of thyroid tissue around upper pole. Lower left figure shows division of it, and right large figure shows goiter displayed and the actual resection commenced.

forceps. Each so-called crowbar utilizes a retractor as its fulcrum and depresses surrounding tissues at the same time that it aids in prying the goiter out, thus facilitating the display in two ways at once. These miniature levers are held in place until the gland tissue is caught with forceps and divided in the plane desired. The whole procedure is something much more definite

and workman-like than the wading in quicksand which is another name for the frantic and futile *morcellement* of an already torn, bleeding hyperplastic lobe such as is so often found solidly fixed in position especially after ligations and x-ray treatment have been indulged in.

The exposure is usually rendered somewhat more difficult by preliminary ligation. The same thing holds true to some extent for preliminary radiation of the gland in exophthalmic goiter, but neither of these causes are comparable in importance to boiling water injections in the production of acute perithyroiditis. If, however, one waits long enough, about three

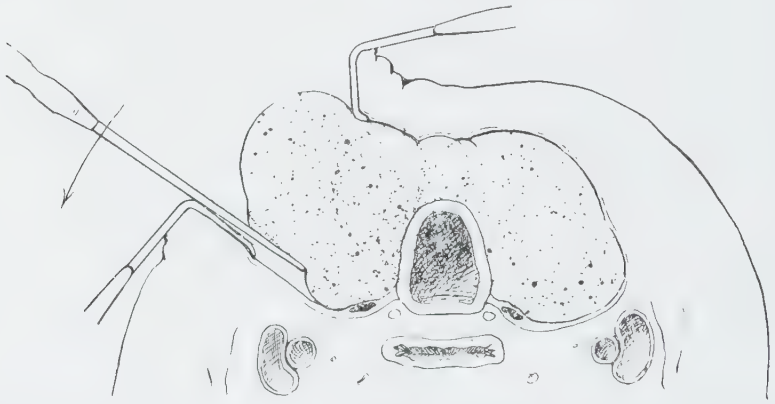

Fig. 49.—Shows in diagrammatic cross-section of the neck how a straight elevator is thrust from the side underneath a thyroid lobe and employed in the manner of a crowbar, one of the retractors forming a fulcrum meanwhile.

months, after injection before he attempts to deliver the gland, the matter of delivery solves itself to some extent.

One intrathoracic goiter of enormous size could not be elevated with the finger because of its size, and no forceps would hold on it, so we had to slip a curved retractor like a hook beyond it and elevate it in this way. Some such maneuver can always be carried out although one would prefer to have the safety afforded by the tactile sense instead of trusting a metallic instrument in so delicate a situation.

In accomplishing the display of the goiter, C. H. Mayo advises one never to attempt the identification of the parathyroids or recurrent nerves. To this I should add that I long

ago gave up searching for or ligating the inferior thyroid artery as part of the thyroidectomy technic. On the other hand, I must emphasize enthusiasm for locating, palpating, and if possible, visualizing the trachea at just as many points as this can be done without undue exposure of, or meddling with, that important viscus. I must confess to being one of the large number who have accidentally injured it in doing thyroidectomy, and I am sure that all who have had this experience are much

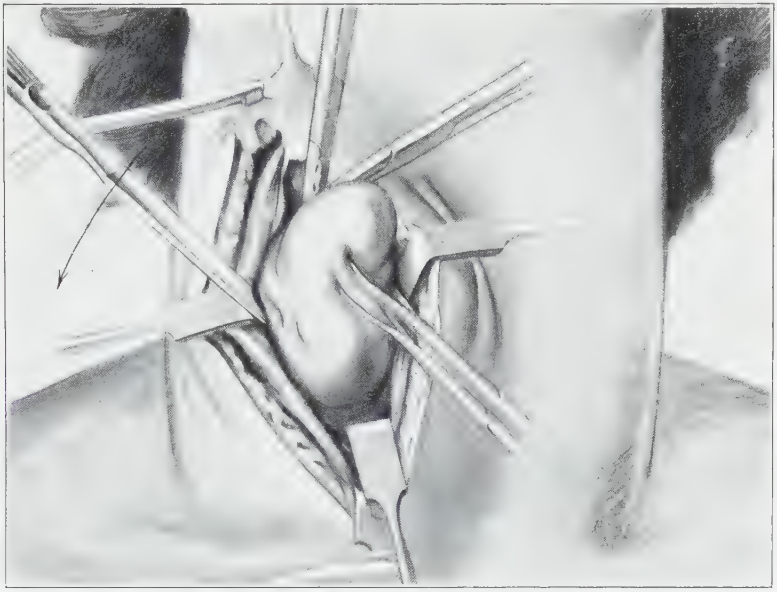

Fig. 50.—A straight crowbar is in actual use as shown diagrammatically in Fig. 49.

happier when they know just where it lies at every stage of the operation.

One must also consider the difficulty of displaying the remaining lobe when connective tissue adhesions have formed subsequent to the removal of the first half of the gland. One of our cases (Mrs. O., October, 1920) demonstrated the great difficulty of delivering a second lobe six years after a primary unilateral lobectomy, which had been followed by adhesions between muscles and the remaining lobe. The muscles could not be stripped at all, and sharp division of muscle or thyroid had to be made.

Finally, the whole procedure reduces itself to the not always simple matter of getting into the right cleavage plane and remaining there if only the operator is so fortunate as to be able to do so.

## References

[1]Pemberton, J. deJ.: Surgery of Substernal and Intrathoracic Goiters, Arch. Surg., January, 1921, ii, 1.

[2]Crile, Geo. W., and Lower, William E.: Special Points in the Technic of Operations on the Thyroid Gland, Ann. Surg., January, 1922, lxxv, 47.

## CHAPTER XIII

## DETAILS OF TECHNIC—CONTINUED

### THE ACTUAL RESECTION

In thyroidectomy, as in every other field, it is to be supposed that the resourceful operator will vary his plan of attack to suit the occasion, since conditions differ so greatly as to make no one resection scheme easiest in every instance. It may be stated in passing that I practically never do any of the four classical arterial ligations immediately before attacking the gland itself, but always work just within the gland capsule and take care of the vessels as I come to them.

Most resections are conducted methodically and bloodlessly up to the time when the operator, having divided the upper pole and delivered the lobe, begins to break through the capsule and to amputate it. As usually conducted by cutting and catching a bit at a time, this phase of the operation is more or less bloody, according to the vascularity and friability of the gland, to say nothing of the teamwork displayed by those in charge. Often the seemingly innumerable bleeders in the stump are difficult to catch, and the back-bleeding is almost equally perplexing.

#### With Tourniquet

An age-old consideration in surgery suggests the temporary constriction of the stump in somewhat the same manner that extremities were once amputated and hysterectomies done. Strange as it may seem, when confronted by this highly vascular field, but few operators, like Downes with his compression forceps and Freeman with his compression needles, seem to have made routine use of this rather obvious aid to absolute hemostasis.

I employ gentle temporary constriction of the stump with an elastic band in suitable instances, and thereby amputate in a perfectly dry field; nor is this the sole advantage of the plan, for I go further and replace this temporary control de-

vice with gentle uniform purse-string compression of the residual thyroid tissue, wholly eliminating the time-consuming and often difficult individual ligation of its many bleeding points. The vessels entering the upper pole are treated by suture ligatures in quite the usual way.

Leonard Freeman[1] in 1920 reported a "tourniquet operation" which he had employed successfully in one hundred eighty-two cases, and which he feels is applicable to all kinds of goiters, with the exception of the calcified type. In this series of cases there occurred no injury to the recurrent laryngeal nerve or to the parathyroids, and Freeman feels that such danger is not great even in the hands of the inexperienced operator.

Temporary use of a *rubber* ligature involves no risk of sloughing, sepsis, and secondary hemorrhage, all of which characterized the earlier operations in which some form of "mass ligature" was so common, previous to the development of hemostasis as we know it today.

Judd, New, and Mann[2] concluded, as a result of an experimental study of the regeneration of the recurrent laryngeal nerve together with restoration of function following operative injury, that "stretching the recurrent laryngeal nerves acutely in a manner similar but of longer duration and intensity than occurs in operation does not impair the function of the vocal cord."

In order to ascertain exactly the amount of traumatism produced by the band, I have made use of it in numerous instances where the operation was conducted wholly under local anesthesia, and I have been surprised to find that in properly selected thyroids the constriction can be applied if it is put on gently and not too tightly without the patient's knowing when this is done. Of course, this is not always true, and I am very willing to admit, as stated elsewhere in other words, that it had *better not be employed* at all where it is not tolerated without symptoms, no matter whether the patient be awake or asleep.

The operator works with a very comfortable feeling of safety because the field is absolutely dry and he knows just where he is cutting at every stage of the procedure. It seems to me, in view of the importance of near-by structures that this is perhaps one of the greatest advantages of this method, for

surely one can protect the trachea, parathyroids and recurrent nerve only when the field is so free from blood that he can see exactly what he is doing all the time. Furthermore, one knows exactly how much he takes and how much he leaves because there is no time when he cannot see and control every portion of the perfectly dry field.

The man who controls the thyroid capsule completely by constricting it during the resection holds the whip hand absolutely during the scene of this operation, as was remarked once by Captain Nichols of Fort Des Moines who seemed surprised at the complete hemostasis which characterizes one of these operations.

For very toxic patients a technic simplified to the very highest degree is certainly most desirable, and I believe that the use of the rubber constriction is a step in this direction. By its use one is assisted in attaining at least three or four most desirable objectives. These are (1) to remove the maximum amount of thyroid tissue consistent with the safety of the structures lying just behind the gland; (2) to insure hemostasis in the highest degree; (3) to shorten the time of operation as much as possible, especially if working under an infiltration anesthesia; (4) to cause a minimum amount of operative trauma and postoperative discomfort.

No matter how large a thyroid lobe may become, its tracheal attachment, so far as my experience goes at least, remains a practically constant factor in the case; it therefore happens that a rubber ligature encompasses a pedicle of somewhat the same size in every instance, no matter what growth the tumor may have attained. In fact, the larger the tumor, the easier the application of the ligature, because it will, as a matter of course, slip more readily down to the base of the tumor where it is most efficacious. The same is true after the lobe has been amputated; we have to deal in practically every instance with a stump of a given size; therefore, the final treatment of the constricted stump is more or less similar in all instances, no matter what the size of the tumor.

This technic is particularly applicable to any lobe which naturally forms a pedunculated tumor after division of the upper pole. It is to be recommended for a hyperplastic thyroid

if it is at all friable and vascular, hence hard to handle, as all are prone to be, even after symptoms have disappeared consequent upon ligation, x-ray, etc., months previously.

The isthmus is so rarely diseased that one can in most instances remove the two lobes separately (rubber band) without in any way interfering with the tracheal coverings. In this way one avoids much annoyance to the patient who would otherwise frequently suffer from postoperative tracheitis as a result of the circulatory interference which Crile considers inherent to an extensive exposure of the anterior aspect of the tube.

Fig. 51.—Cross-section of the neck showing approximately where the so-called holding clamps are placed on the stump and their relationship to the intended resection line.

Of course circumstances alter cases and there are times when one must individualize here as in any other surgical procedure, but as a rule I divide the resection of the thyroid lobe rather definitely into the following steps:

1. The superior thyroid vessels are divided and the upper pole is separated from the trachea sufficiently to isolate what I am going to term the *stump*.

2. Clamps which shall be termed "markers" are then applied at four to six points (Fig. 51) on the circumference of the stump about equidistant from one another.

3. Just behind these markers a fine rubber tube is made to encircle the stump (Fig. 52) and is drawn up rather gently and

caught with clamps (Figs. 53, 54 and 55) or tied, as the fancy of the operator may dictate. The degree of constriction will vary somewhat with the needs of the case, as well as with the delicacy of touch possessed by the one applying it. The tendency is, I think, to make it needlessly tight and thereby bring about symptoms which give evidence of interference with respiration.

4. The lobe is now resected at a safe distance above the constriction (Fig. 56), a wedge-shaped defect ensuing which

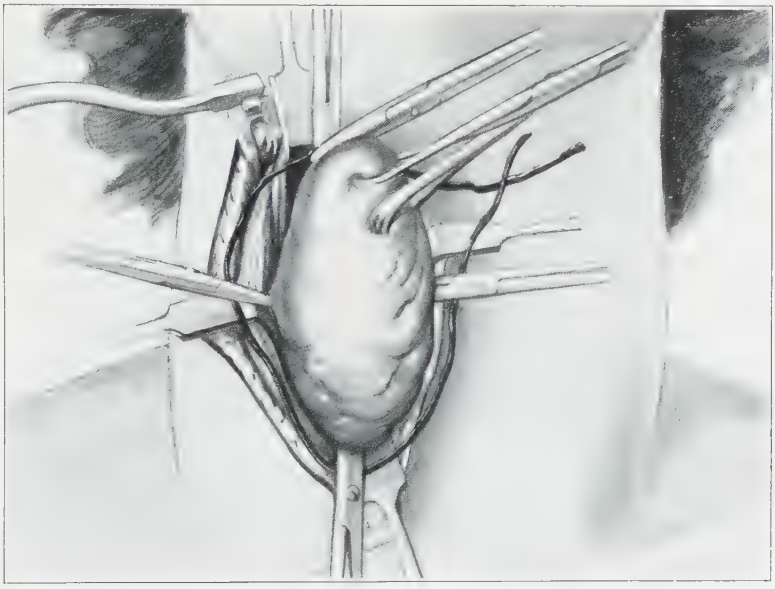

Fig. 52.—The rubber ligature lies loosely around the pedicle behind the four holding clamps which are intended to prevent it from slipping forward.

guarantees that too much thyroid has not been left behind (Fig. 57), as would be likely if the division were made in a perfect plane. I am accustomed to grasp the thyroid capsule at a few points as the resection takes place. Occasionally it is necessary to catch one or two bleeding points deep in thyroid tissue, but this is not the rule if the constrictor functions properly, and as a rule the cut surface is perfectly dry.

5. The superior thyroid vessels are ligated with catgut on a needle after which the remainder of the divided upper pole

is whipped down as far as the rubber constrictor encircling the stump.

6. The purse-string of fine catgut is inserted into the capsule (Figs. 58, 59, and 60) following its cut edge all the way round, and this when tied, rather closely approximates the points that have been cut by it.

7. The handles of the forceps called markers are brought together with the instruments in a vertical direction, and a second purse-string suture is applied in such a way that the

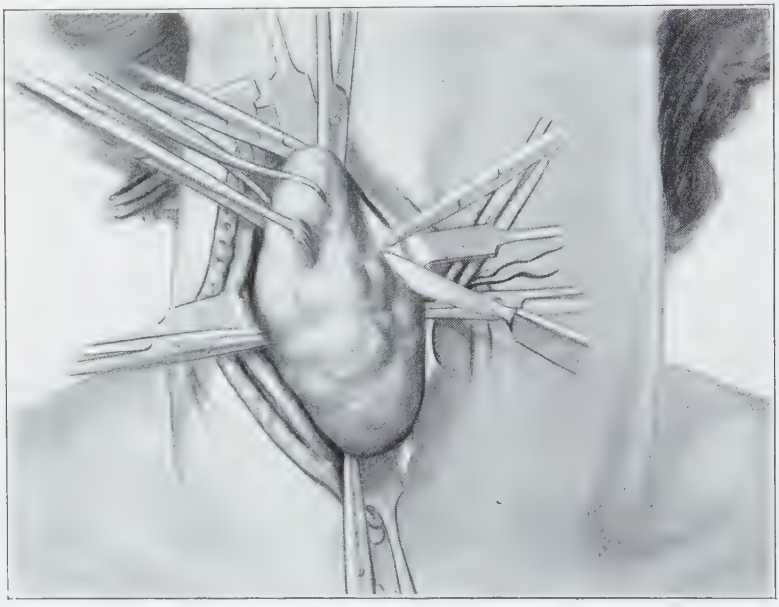

Fig. 53.—The rubber ligature has been tightened, caught with two clamps and the resection in front of it has been started.

needle penetrates thyroid tissue just behind the point where each forceps has grasped it; then as this purse-string is gently drawn tight, the markers and the rubber constriction are removed, usually without the loss of any blood at all.

Occasionally an extra suture ligature or two must be used to control some bleeding point which has been overlooked or has slipped back, a matter of course when one considers the very simple means which have been employed to control the blood supply of a structure richly endowed as is the thyroid.

The following random explanatory remarks may make it

easier for the reader to visualize the above listed seven phases into which the technic is divided.

After disposing of the superior vessels, it is my custom to begin the resection at the lower pole. The control here, as well

Fig. 54.—Details of the holding clamps, the rubber ligature and the pedicle in relation to each other.

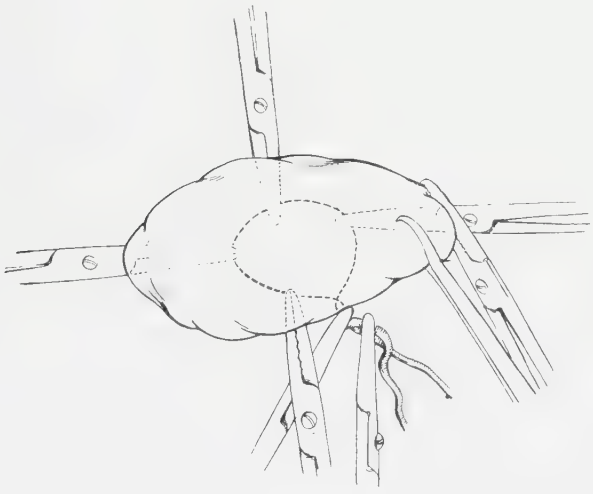

Fig. 55.—Same as Fig. 54, if one conceives of the field being viewed from directly in front through a transparent lobe.

as along the lateral aspects of the stump, is much more simple than at its upper extremity where the capsule has been divided; therefore this uppermost area is handled last, when it can be isolated and clamped most readily.

After a shallow furrow is made well above the constriction,

the lobe is elevated while the capsule is shelled back and a conical specimen is developed. Any desired amount of tissue is thus removed.

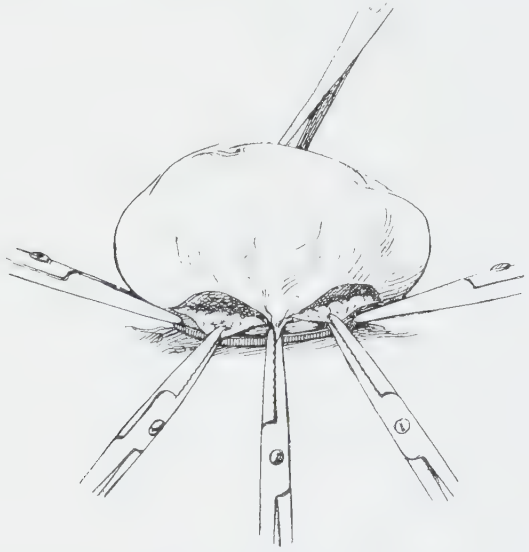

Fig. 56.—Shows line of resection in its relation to the rubber ligature and the holding clamps. It will be noted that two additional clamps have been placed on proximal thyroid tissue since the actual resection commenced.

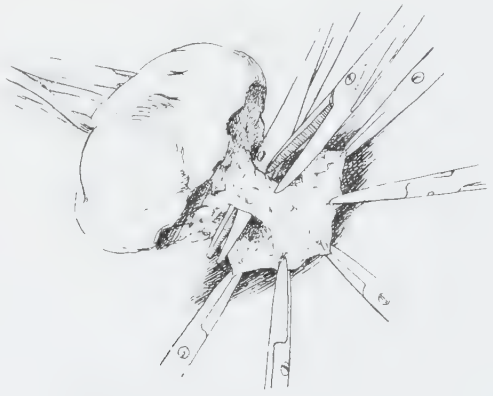

Fig. 57.—One or two vessels are often caught separately in the parenchyma of the stump.

The rubber constriction need not be really tight enough to prevent any bleeding from the surface as it is cut across. In fact frequently an isolated artery is caught, and this is done with utmost precision because the surrounding field is so com-

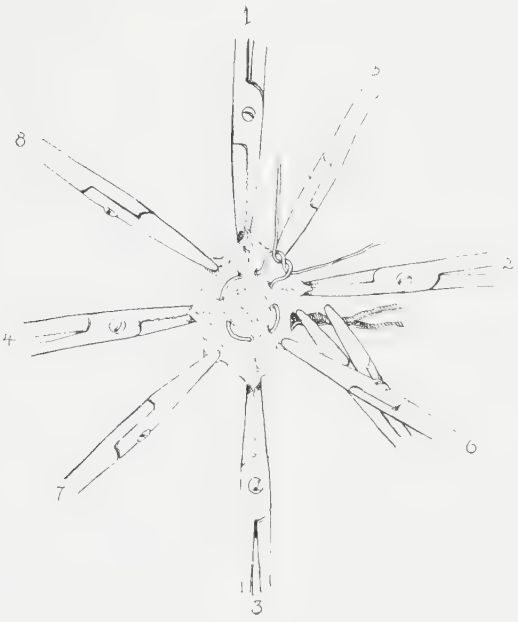


Fig. 58.—One deeply placed purse-string ligation suture approximates an inner zone of divided thyroid tissue.

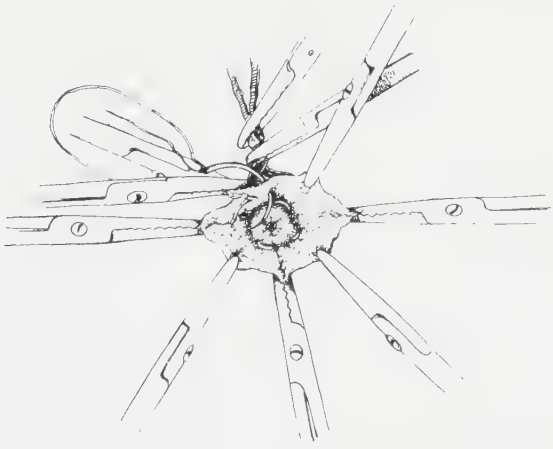

Fig. 59.—A second ligation suture in the form of a purse-string inserted at the edge of the stump when tied institutes compression sufficient for complete hemostasis.

pletely dry. Perhaps the chief value of the rubber band consists of its ability to prevent the stump from retracting and spreading after it is cut. Many a goiter is so vascular that every portion of a cut surface must be controlled by pressure of some

sort, else enough bleeding from vessels too minute for individual control occurs, to result in a field so obscured as to render technical precision most difficult. Under just such circumstances injury to the important structures behind and about the gland is likely to occur.

As soon as the lobe is resected, the rather moderately tight rubber constriction allows an occasional artery to bleed. More frequently treatment of the stump is completed by application of two purse-string sutures, one applied to the extreme cut

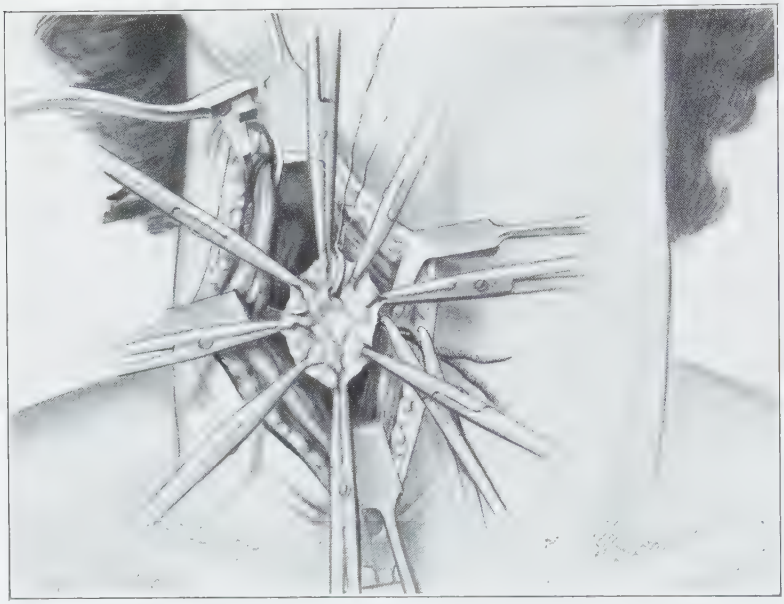

Fig. 60.—Shows the stump in relation to surrounding structures while the rubber constrictor is in place and the compression sutures are being inserted.

edges of the gland tissue and tied before the constriction is removed; the other applied behind the rubber band after the handles of all the holding forceps have been lifted up and brought together in one bundle. The second purse-string is gradually tightened while clamps and constricting band are being removed. When tied, these sutures usually completely control all bleeding by the moderate general pressure exerted on all cut surfaces. Occasionally some one bleeding point still has to be caught and controlled with a suture or ligature.

The elasticity of the band is usually sufficient to compensate

automatically for changes in tension due to a cone-like mass having been excised out of the stump, so to speak. It is, however, very easy to change the tension on the band at any time during the operation provided any bleeding takes place, or on the other hand, respiratory symptoms indicate that it is too tight.

Of course, vastly fewer clamps are used than would be the case if no constriction were employed. This is a matter of special import where local anesthesia is used since the aggregate of their weight is very frequently a prolific source of discomfort to a patient who is awake.

Where two lobes are removed separately in this manner, it will be seen that the isthmus has hardly been touched at all. In a great majority of instances it is perfectly normal, in my experience at least, and requires no operative treatment. By leaving it intact, one adopts the best possible safeguard against acute pseudoinflammatory neuroses which result from interference with its blood supply, as well as the best preventive of the late adhesion neuroses which are so common after the muscular and facial structures of the anterior neck have grown fast to an exposed trachea and limit the mobility which should normally accompany swallowing.

Crile and Lower[3] show the dire consequences that may result from dissection carried directly on the trachea or larynx. In such cases the peritracheal fascia is most frequently picked up and tied in the vessel ligature, including the sensory nerves entering the trachea wall. This is interpreted by the brain as a foreign body and there is manifest irritation, coughing and mucus from which a local tracheitis may develop and go on to bronchitis, rendering the patient susceptible to bronchopneumonia which in many cases terminates fatally. "Contact with the trachea and the larynx may be wholly avoided by a sharp, bloodless dissection above the line of cleavage, and hence at a sufficient distance from the trachea and larynx to tie the vessels, without including the sensory nerves of the trachea, leaving on the trachea an undisturbed biologic coat."

Rubber band constriction of a goiter stump *may* be employed around the attachment of both lobes at the same time provided, of course, that the tumor is large enough to spread

out in every direction so that the band will gravitate of its own accord deeply down into the trachea. This should *never* be done, however, I believe, since in one instance where I employed it everything went along smoothly for some time after the amputation of both lobes had been made in one block, then suddenly a partial obstruction became apparent, no doubt as a result of lateral compression of the trachea caused by the band pressure. All symptoms were instantly relieved when the constriction was released, but a bloody field resulted because the ligating had not been entirely finished on the second side at the time the band had to be taken off.

There are, as a matter of course, thyroids wholly unsuited to treatment with a rubber ligature. It is not always possible to say in advance just where it should not be used. In fact one cannot identify until he tries it the patient on whom it is better to catch and cut bit by bit instead of employing the constriction. What is meant is illustrated in the operation on several patients in our clinic. Of these cases Miss S. (November, 1924) will serve as an example. As soon as the constriction was tightened, there was obvious embarrassment to respiration, with a suggestion of suffocation, local and general cyanosis, as well as the respiratory stridor which characterizes interference with vagus or recurrent nerves. Where these symptoms, as is very rarely the case, are unquestionably connected with use of the rubber band, I immediately discard it because I long ago learned that just these patients are likely to be the subjects of postoperative respiratory phenomena which sometimes follow a goiter operation. Reference is made to tracheitis, bronchitis, and even a mild bronchopneumonia, complications occasionally seen after any type of thyroid resection, but particularly to be expected when there has been needlessly rough handling of the larynx and trachea.

The rubber band technic is never considered applicable to thyroids which do not very considerably exceed the normal size. The chance for error is too great on the side of leaving an excess of thyroid tissue behind. This becomes apparent when one considers that there is a very small amount of residual tissue after a proportional large amount of diseased small gland has been removed.

No constriction technic of any kind is to be considered in those cases, not so rare, characterized by a thyroid which is shaped like a horseshoe by reason of having an isthmus of breadth and thickness similar to the lobes, hence illy defined from them. The operator who attempts to constrict off the two lobes of such a gland separately is sure to leave behind too much thyroid tissue. He must separate such a horseshoe-like goiter bit by bit from the trachea, removing it "en bloc" if the patient's condition permits, but never by the constriction method under any circumstances. Neither are rubber ligatures suitable in any other type of lobe which tends to encircle the trachea or the esophagus.

### Without Tourniquet

It may now be worth while to mention a number of the technical points which we have found helpful when amputating a single lobe or resecting a lobe and the isthmus or removing both lobes in one "bloc." I regularly employ the latter procedure when the isthmus contains adenomata or is a heavy, thick structure which goes over almost undefined into the two lobes.

Halsted's plan of dividing the isthmus just after dividing the upper pole seems to me less easy than a procedure just the reverse, it being easier to get at the isthmus after the lobe is freed from the trachea.

Sometimes a lobe can most conveniently be attacked by beginning at the lower pole and cutting it off from below upward, either with or without dividing the isthmus as one proceeds. This method is especially valuable in those cases where a superior thyroid ligation has been followed by dense adhesions or where the upper pole projects very high upward.

The operator who plans the method of procedure should logically place the proximal clamps which outline the field; since the efforts of only one pair of hands can be definitely coordinated, traction on the tumor is the logical work of the operator's second hand. Much time may be saved by having an assistant cut part of the time with each proximal clamp as a guide, allowing the operator to keep both hands steadily busy

with constructive efforts instead of repeatedly dropping one instrument which must be recovered after disposing of a second.

The superior thyroid vessels must be caught double before being cut, and, as a matter of course, the large vascular thyroid lobe presents possibilities of sufficient back-bleeding to keep the

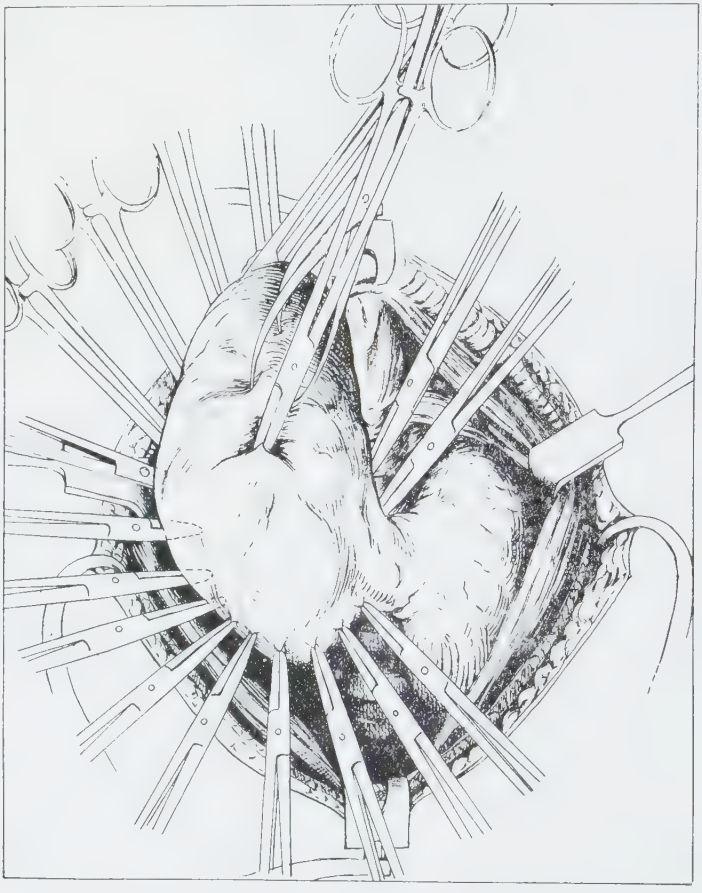

Fig. 61.—Illustrates a method of marking the proposed resection plane after the upper pole has been divided and the lobe completely delivered.

field obscured no matter how accurately the bleeding points in the stump are caught. After the upper pole has been completely freed, it is of greatest importance to lift the lobe out of its bed to determine the plane in which the resection is to be made. It is then *marked* by a number of clamps placed very close together, as illustrated in Fig. 61. Some of the clamps

should be placed upon superficial blood vessels, but a further object in using them is to insure the operator's following the predetermined plane of resection: they are of additional value

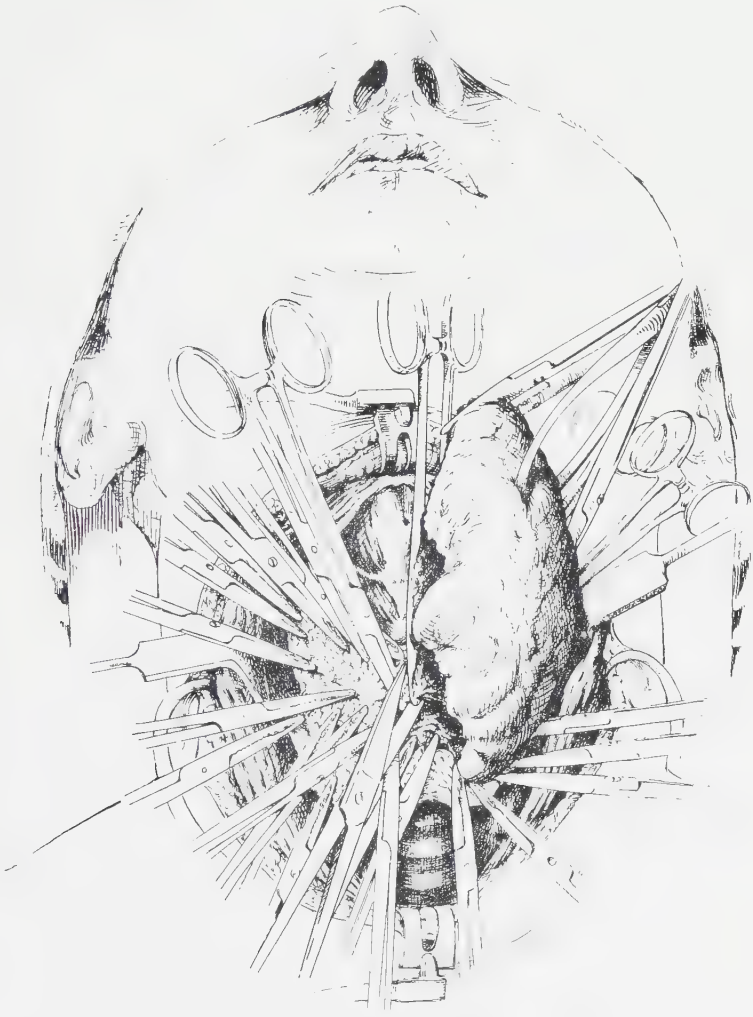

Fig. 62.—Shows the appearance of the operative field after one lobe has been resected and a few parenchymatous vessels caught. Also shows clamps which were used to mark plane of resection.

in preventing the retraction of the stump which would otherwise render the ligation (Fig. 62) and suture of its substance difficult.

It will be necessary, perhaps, to catch a few points on the

tumor side as one resects, but the number of clamps so used can be greatly decreased by intelligent traction on the tumor; by merely rotating the hand holding these clamps, the tissue can be so compressed that often no back-bleeding will take place although no effort at all is made to catch more than very few of the distally divided vessels.

In many instances the patient will manifest signs of partial suffocation as soon as one lobe has been removed and the many clamps attached to its stump are allowed to drop down and exert traction indirectly on the trachea. As a rule these symptoms are immediately relieved if all of the forceps are gently lifted in a group and held up in such a way that there is neither any pulling nor pressure exerted by their weight upon this viscus. This is a matter of great importance, else the patient accumulates an excess of carbon dioxide in the blood and in consequence bleeds enough to soil the field and render the ligations difficult.

In a bilateral "bloc" resection, it is well to ligate vessels of the stump on the first side after throwing one lobe across the midline (Fig. 63). The patient, if awake, is more comfortable than if the whole gland is removed at once; breathing is also much freer than if the clamps are all applied at once and compress the trachea on both sides. It is useful to expose the second lobe by traction exerted through the isthmus after the first side is ligated.

After a lobe has been resected by catching bit by bit and cutting, the tissue in each individual forceps is carefully ligated separately only when the gland has been small and a scant amount of thyroid tissue covers the trachea. This is a rather laborious and time-consuming procedure, especially in a highly vascular gland, and so in most instances, tissue is merely transfixed under one forceps after the other with a small needle threaded on very fine catgut, and in this way not only gentle constriction is exerted with a continuous suture ligature, but at the same time all portions of the residual thyroid tissue are drawn together, and a tiny lobule is reconstructed just where the resected lobe was attached to the trachea. The control of very many bleeding points can be accomplished in this way with surprising speed and facility. One who does it for the first time

will be gratified to note that very gentle constriction suffices to control most thyroid vessels.

Choice of suture material employed is of great importance where very many ligations have to be made as about the stump of the thyroid lobe. The size of the suture, the time it resists absorption, the presence of chemicals in it, and the amount used, all have a very definite influence on postoperative collection of

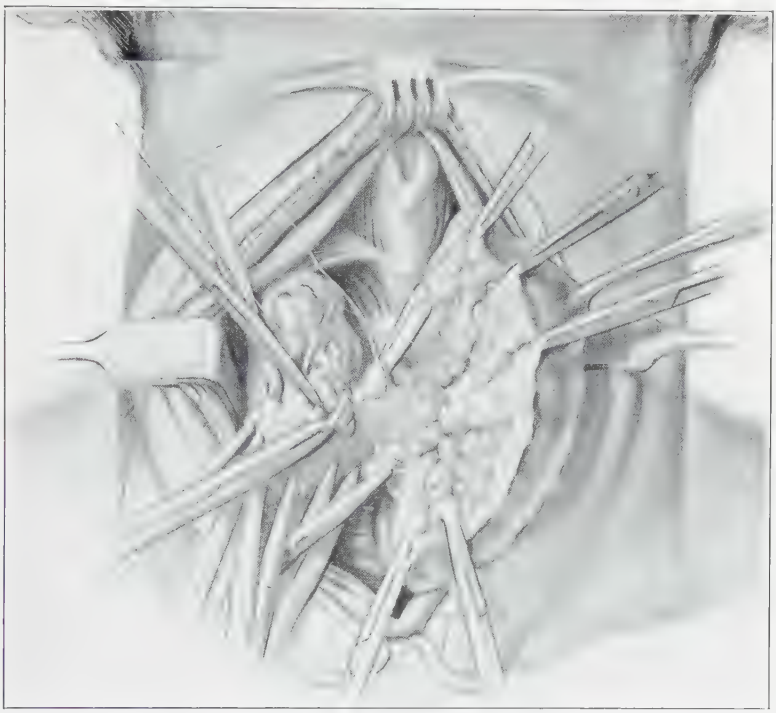

Fig. 63.—Ideal operation. The right lobe has been resected by cutting across its base and catching blood vessels as encountered. The resected lobe has been thrown across toward the left of the midline and a continuous suture ligature is being applied under each clamped vessel.

serum within the wound. I use exceedingly fine strands of catgut, employ them singly in most instances, and try to get along with a minimum amount.

Do not fail to have a patient cough and strain after suturing and ligating both thyroid stumps in order to detect any potential bleeding points before they are hidden in the depths of the closed-up neck and before the patient raises her blood pressure when she strains in the effort to cough, vomit, move about in

bed, or evacuate bladder and rectum. Just here is shown one of the great advantages of local anesthesia or of a gas anesthesia so light that a patient can easily be roused to strain when it is desired.

### Clamps Left in Place

The resistance of patients who are poor surgical risks is likely to be pretty well used up by the time the division of the stump is completed, and the additional time consumed in ligating every bleeding point may endanger the life of the patient; therefore the clamps are occasionally allowed to remain in the wound, and the patient is put to bed in as comfortable a position as possible, under the care of a special nurse who is instructed to resist the patient's movements, while sedatives are used to the limit of safety. It is understood, of course, that such a procedure is to be considered *only* in desperate cases where it greatly reduces the operative risk. When the lobe is out, if the clamps are left on, the operation is over. In one patient I left as many as thirty-four clamps hanging in the wound. She was a very poor subject, and the field was extremely vascular. Naturally the weight of them was considerable, but she survived after this choice between postoperative discomfort and operative risk entailed by continuation of the procedure until every bleeding point was ligated.

Theoretically it is far from ideal to leave a lot of clamps in place because the patient is rendered very uncomfortable, is exposed to infection, and the cosmetic results following this procedure are never so satisfactory as when the wound is not stretched by the bulk and weight of the clamps. Certain definite symptoms are usually produced by clamps left hanging in the wound—respiration is interfered with, there is difficulty in swallowing, and a sensation of pressure or traction is experienced, depending upon the patient's posture. Movements are prohibited, and as a consequence the patient gradually overstrains every muscle and nerve in the body in an endeavor to lie perfectly quiet, with resultant muscle cramps and nervous and mental fatigue. Some patients do not complain much, but there is reason to believe that all so treated are far more uncomfortable than one would willingly have them; therefore, as stated, the administration of sedatives is recommended. All of these

disadvantages are offset, however, by the shortening of the operation, perfect drainage, and no accidental loss of blood such as occurs in some attempts at ligation.

All clamps may be removed from the stump at the end of twenty-four hours except those upon superior and inferior thyroid arteries, and so far no postoperative bleeding has been seen to follow the procedure. This, however, I believe, is the result of careful technic practiced in their removal. They are at first merely unlatched and allowed to spring open of their own elasticity, then they may be lifted out of the wound two or three hours later. If the clamps are allowed to spring open of their own accord, they gradually loosen and leave the walls of the vessel in contact, effecting as complete closure of the vessel as would a ligature; however, if the clamps are forcibly opened, the vessel walls adherent to the clamp blades are pulled along with the clamp and the vessel is opened, with consequent hemorrhage.

Any gauze packing between or around the clamps may be left twenty-four hours longer if the patient's condition warrants it; however, I usually take everything out of the wound and apply skin clips at the end of the first twenty-four-hour period, provided the largest arteries have been ligated primarily, otherwise a few clamps remain thirty-six hours.

No anesthesia is required for the removal of the clamps; however, in perhaps half of my cases, I employ very light gas anesthesia for the removal of the gauze, and in an equal number of instances I use an anesthetic during the application of the skin clips, which can be accomplished in a patient having an average amount of self-control, by novocaine infiltration of the skin edges.

One of the greatest advantages of leaving clamps in place is felt by the operator who has been taught by experience that hyperplastic thyroid tissue is most difficult to handle. It is most friable; clamps even tend to cut through it like scissors, while sutures and ligatures tear it unless most gently manipulated, to the end that hemostasis is uncertain and faulty. In consequence of this any quantity of blood may be lost to a patient who can ill afford it, and an operation which has progressed with all celerity up to this time, may be delayed beyond the margin of

safety of any general anesthesia, or until a local anesthesia patient has become exhausted and therefore uncontrollable. Nor is this all: many if not most of the serious injuries to recurrent nerves, trachea and other important structures have occurred while an excited operator has vainly striven to catch a vessel retracted into the depths of a wound from which blood is flowing copiously.

By the use of a few holding forceps and the elastic ligature, previously described, we are able to interrupt a thyroid resection as soon as the lobe is out without making any ligations, with much less tax on a patient's resources than was the case when we formerly caught every vessel singly and then left thirty or forty clamps in position. Figs. 52 to 57 show how we apply a few forceps to prevent the rubber ligature from slipping forward. These are merely lifted up to a vertical position after a pad of gauze has been packed between their points and then the rubber which encircles them compresses the cone-like stump so firmly that nothing bleeds. A little gauze is often packed around them to fill out the defect left by the removal of thyroid tissue. The superior thyroid vessels are ligated and the entire procedure is completed so quickly as to surprise one who has never been obliged to use an emergency treatment for the stump.

I have found one patient in whom I could not leave clamps. She showed all the symptoms of suffocation from tracheal obstruction when gas anesthesia was relaxed. All symptoms subsided as soon as ligatures replaced the clamps.

I must state in closing this chapter that I believe a mistake is frequently made by leaving too much rather than too little thyroid tissue. I have never in all my experience seen deficiency symptoms to what might properly be termed a pathologic degree, and I believe I leave in an adult no more thyroid than will guarantee against the slipping of ligatures off the superior and thyroid vessels or more than will insure the integrity of the structures behind the posterior capsule. An individual who has reached complete development requires very little thyroid tissue and, on the other hand, the only sure way to cure hyperthyroidism is to remove a maximum amount of secreting tissue.

In addition, the best safeguard against recurrence seems to be the removal of an adequate amount of pathologic thyroid substance, especially if it be nodular and the patient be young.

Crile and Lower[4] have concluded as a result of their surgical experience that the amount of gland tissue to be left differs with the type of goiter. The amount to be left should be the equivalent in functional value of the normal gland. A section of hyperplastic gland (exophthalmic) half an inch square and one inch long they believe to have as much functional value as ten times that amount of colloid gland because the hyperplastic gland is made up almost entirely of large columnar cells, while the colloid goiter is mostly colloid material with a single layer of cuboidal cells, therefore only a small portion of the exophthalmic gland should be left, while an amount larger than that of the normal thyroid is required in the case of colloid goiter because the colloid goiter is not so active as the normal gland.

## References

[1]Freeman, Leonard: A "Tourniquet Operation" in Toxic and Other Goiters, Ann. Surg., August, 1920, p. 161.

[2]Judd, New, and Mann: The Effect of Trauma upon the Laryngeal Nerves, Ann. Surg., 1918, lxvii, 257-262.

[3]Crile, Geo. W., and Lower, William E.: Special Points in the Technic of Operations on the Thyroid Gland, Ann. Surg., January, 1922, lxxv, 47.

[4]Crile, Geo. W., and Lower, William E.: Special Points in the Technic of Operations on the Thyroid Gland, Ann. Surg., January, 1922, lxxv, 47.

## CHAPTER XIV

## DETAILS OF TECHNIC—CONTINUED

### PACKING AND DRAINING

It is an excellent rule never to drain the cavity left after the removal of a rather small goiter unless there be definite reasons for so doing. I agree with Halsted and others who do not drain at all in an ideal thyroidectomy. Perfect hemostasis is not consistent with drainage; on the other hand, drainage, if needed, is often not satisfactory unless a wound be left wide open; this we do in toxic patients or in those whose enormous defects we cannot obliterate, or when circumstances preclude a perfect hemostasis.

When one leaves a drain in a goiter wound, he can always justify the procedure by the escape of bloody fluid which might not have appeared had not a foreign body been left behind not only to irritate the tissues in general, but to produce coughing and make swallowing difficult. Conversely, the man who does not drain the wound will be correspondingly happy when he finds that drainage was really not needed, probably because his hemostasis was perfect in view of none being intended. As a rule there is no need ever to use a drain in one of those few characteristic patients whose tissues are and remain typically dry unless easily recognized vessels have been neglected.

Drainage in my own experience has not prevented large secondary collections of blood and serum. In fact, the largest collection I ever saw occurred in a Mrs. M. (March, 1919) some days after the removal of a fairly large rubber tube. I have never had to open secondarily an undrained neck for urgent symptoms such as those resulting from the pressure of fluid upon the important structures of the neck.

Routine drainage of goiter wounds indicates an operator lacking in either the ability or the inclination to effect accurate hemostasis. I believe this statement is consistent with one which embodies an estimate that secondary spontaneous drainage of small amounts of bloody serum has occurred in 10 to

20 per cent of my undrained patients during the ten days following operation. In no instance which I remember, however, have these small collections produced more than merely noticeable symptoms so far as the patient's subjective attitude is concerned. I must say, on the other hand, that I had a tube or some other form of drainage in every neck which ever gave trouble from secondary hemorrhage, but the blood *clotted* before running out.

It will be seen from this that a tube, no matter how placed in the wound, does not protect the patient against tracheal obstruction resulting from the accumulation products by an active hemorrhage during the period of reaction when coughing, vomiting, and straining take place. In fact one midline drained neck bled enough into the retroribbon-muscle space to cause almost fatal pressure suffocation without much external escape. This patient was hastily returned to the operating room, the wound was torn open, the active superior thyroid artery secured, and her life apparently saved thereby.

The above preliminary considerations lead logically to the thought that the man who does not indulge in routine drainage must recognize seven quite definite indications for it. As they appear to me they are:

1. Injury to the trachea.

2. Injury to the esophagus.

3. Urgent need for hasty closure of neck on account of patient's general condition.

4. Use of excessive amount of fluid in a local infiltration anesthesia.

5. Bleeding of a general nature which cannot be accurately controlled by individual ligatures.

6. To allow the escape of toxic fluids.

7. When the goiter has been so large that immediate and complete collapse of resultant cavity walls is hardly to be expected, noticeably true of an intrathoracic goiter. The walls of such a cavity throw off fluid in the early stages of the healing process, but after this ceases, there seems to be no reason that the defect should communicate with the outer world.

In the treatment of toxic goiter cases one may be justified in ruling drainage out of consideration entirely, leaving the

wound wide open. I am confident that many a death has occurred from partial or even complete closure which dammed back the type of fluid with which the patient was unable to cope. For a long time we went so far in our clinic as to state that the need for drainage meant a wide open wound, and perhaps this is still a safe rule for the beginner to follow. At the present time we take a compromise position on this question which is elucidated completely in the section on Wound Closure.

Enormous defects such as those left after removing intrathoracic goiters continue to drain for a long time after partial wound closure which employs any of the ordinary forms of drainage. In several such cases we have been obliged to reopen wounds extensively at a remote date. In one case (Miss F., November, 1921) we left the entire wound open forty-eight hours (the patient placed on her face) with three rubber packs, one in each defect, then closed the wound with most satisfactory results.

One definite rule must be adhered to in drainage, that is, keep all drainage material of whatever sort away from midline suture planes at all times. In fact, one must avoid any possibility of producing adhesions which can bind skin scar and trachea together. As a result of all of the layers being frozen together, the skin moving with swallowing and the upper wound lip greatly thickened, one frequently sees a patient the subject of a positive neurosis. Such an individual is often more unhappy than she was before the goiter was removed. Suggestions will be noted throughout the remaining portion of this section for avoiding this complication by a method of placing drainage material which has proved eminently satisfactory.

Four considerations are advised which have a bearing upon the choice of the material used in caring for a cavity which results after the removal of a thyroid lobe:

1. The cavity requires a pack or a drain.

2. Rubber tube, rubber dam and gauze are available.

3. Definite symptoms are produced by the presence of one of these.

4. Difficulty of removal is a consideration.

Obviously a **drain** takes care of a small amount of blood or serum which runs out of the fairly dry wound during the first

twenty-four hours, but some sort of **pack** which controls bleeding points by pressure is obviously better when there is actual hemorrhage which cannot be controlled by sutures or ligatures. The same thing is true in every department of surgery, I think. Further than this, the walls of a highly toxic goiter cavity should be in free communication with the surface of the body, something which is not accomplished if the wound be sewed up over a tube. Indeed a pack alone can hold such a wound **open** in the sense of no wound surface coapting with any other.

As to the materials which are available for the care of the cavity, it seems to be pretty generally admitted that (1) tubes, preferably of rubber on account of its texture, and (2) rubber dam for packing with a view to rapid drainage, and (3) gauze for packing when hemostasis is the special point in view, seem to meet every want. So far as the tubes are concerned, Kocher always used those made of glass, while others have employed metallic and hard rubber tubes, but all of these, and even soft rubber tubes to a less extent, are productive of decubitus at times; therefore it would seem to me that the softer the tube the better, to say nothing of the advantage which rubber affords of being cut or shaped to suit the occasion.

It is our practice to cut out a longitudinal ribbon comprising in its width about one-fifth to one-fourth of the circumference of a tube. In this way we make a partly open, gutter-like object into which fluids can find their way at any point of origin.

### Method of Introducing Rubber Tube

In the rare instances where we have cross-cut the ribbon muscles, one long guttered rubber tube of a diameter deemed adequate to meet the conditions is placed across the depths of the cavity, each end of it emerging laterally through the extremities of the muscle and skin wound, complete layer closure being made of the tissues which intervene between these two points. In more recent times we do not often cross-divide the ribbon muscles, however, but remove most goiters through a midribbon muscle split, still we protect the patient as noted later against a median drainage scar becoming glued to the trachea.

Tube drainage where deemed necessary after midribbon muscle split is best instituted in just one particular way: Two

guttered rubber tubes are inserted one into each cavity from which a lobe has been removed, crossed in the midline, and allowed to emerge one at each angle of the skin incision. To overcome the tendency toward slipping out of place while the midribbon split and the skin wound are being partly closed, a catgut suture is passed through the tubes where they cross, the ends being held together with a forceps instead of a knot. The forceps is removed just before the skin closure is terminated, but the tubes will not become loosened until gentle force is applied to each one when the time to remove them has arrived.

The skin is completely closed across the middle of the collar wound and up to the points where the tubes emerge at the angles. In this way, as will be seen, we succeed in draining both halves of the deep cavity from which the thyroid itself was removed, and at the same time draining in its entirety the superficial cavity between the skin and anterior neck muscles. A surprising freedom from postoperative retention has rewarded our efforts in this direction.

The rubber tubes are to be removed as soon as the fluid slackens, in from twenty-four to forty-eight hours. A few hours after their removal, the openings collapse and one cannot tell which of two cases has been drained.

### Gauze

A gauze pack is, of course, the ideal hemostatic pressure agent, although here, as elsewhere in the body, it tends to dam fluids back and to cause discomfort and other pressure symptoms when tightly packed in. Gauze is decidedly the best material for packing into a goiter wound in which hemostasis must be secured by its presence. In many instances it may with great advantage be tied or sutured in place with catgut.

An instance where no other material could have taken its place was that of an enormous mediastinal goiter removed in February, 1920, in which a thin shell of cyst wall was left adherent in the depths of the cavity. It bled slowly but persistently and could not be reached. Hemostasis was accomplished by a large gauze pack.

One advantage of gauze over perfectly smooth substances for packing is that it brings out of the wound with it every

shred of the fibrin which forms around a foreign body and by so doing creates the conditions most favorable to secondary coaptation of the exposed surfaces.

The **disadvantages** of the gauze pack are likely to be (1) that the gauze adheres to the cavity walls; (2) causes retention; (3) causes an offensive odor; (4) removal is painful; (5) bleeding frequently follows removal.

As an instance of how carefully the patient must be watched if retention symptoms are to be avoided, I cite one case in which a gauze pack (dry) was left and covered by one clip on the skin; drainage was not accomplished and very toxic symptoms ensued. It is well to soak such packs in glycerin as soon as symptoms arise and follow this treatment by the removal of the pack at the very earliest moment consistent with safety, a point to which attention will be called later. (See also the chapter on After-Treatment.)

The experience of our clinic dictates that a gauze pack cannot be removed in less than forty-eight hours without the incidental risk of secondary general oozing, so troublesome at times as to necessitate repacking. Gauze packs have been difficult to remove on the second and third days, while on the second day alarming bleeding has occurred frequently. On the fifth day a pack literally falls out, being pushed up by the serum beneath it.

Some of our gauze packed cases were weeks in completely healing. This is not true after rubber packs, especially if secondary skin closure is used. With this in mind we sought about, but in vain, for a more or less fluid packing material which might be harmlessly or safely encysted or absorbed. The following two futile instances are recorded:

A small defect was filled with vaseline which became encysted; however with foreign-body symptoms in consequence. Five weeks later it had to be removed and was found unaltered. In another case a very large deep defect was dried with alcohol, then filled with rather stiff vaseline, the midribbon slit sutured and a drain laid across the neck. Twelve hours later the patient had a most uncomfortable neck. None of the fluid or vaseline escaped, the neck became infected, and some ten days later an enormous amount of vaseline emulsion had to be

evacuated. Vaseline and similar pack material *must be used in wide open* neck wounds only, and removed a day or two later.

As a matter of course, we pack the worst type of risk with gauze. We no longer leave many wounds completely wide open, but gain partial closure in two ways, either by placing a clip or two in the middle of the skin wound or by inserting a catgut stitch about the center of the midribbon muscle slit. The hemostatic pack is very much more effective if it is held under tension by some portion of the wound covering at least. In the second place the secondary wound closure is greatly simplified or even at times rendered unnecessary by two or three clips uniting the middle of the skin incision because after packs are withdrawn the remainder of the skin wound tends naturally to spontaneous fairly accurate coaptation of its edges.

### Pack of Rubber Dam

We gradually developed the use of rubber dam as material for packing thyroid wounds, thereby arriving at a sort of compromise between the open and closed wounds or between the



Fig. 64.—Section of a discarded rubber glove about two-thirds normal size, a material which we ordinarily employ for a rubber pack.

shortcomings of the gauze pack and those of the rubber tube. A pack of rubber dam seems to combine the advantages of both of these other materials. Rubber dam (Fig. 64) will drain as effectively as rubber tubing and has in addition the value that it can be used as a pack for holding in communication all the recesses of a cavity, thus assuring against secondary collections

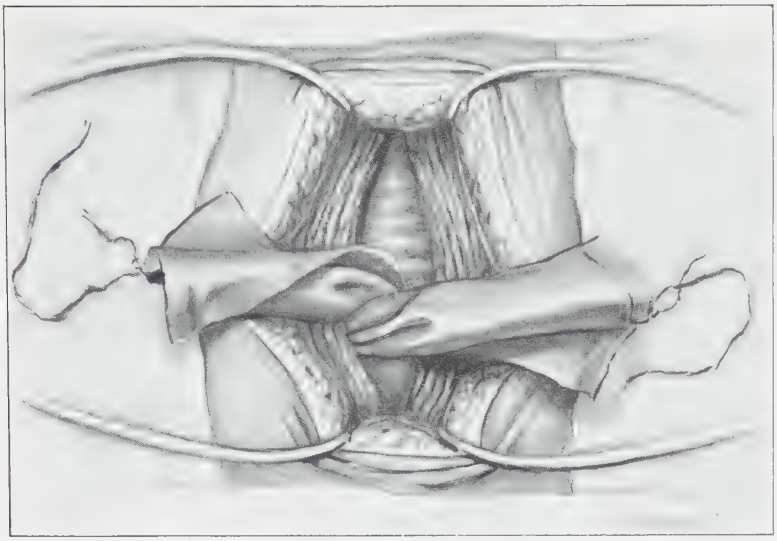

Fig. 65.—Each defect resulting from the removal of a lobe has been stuffed full of rubber and the packs crossed in the midline and each brought out at an angle of the skin incision.

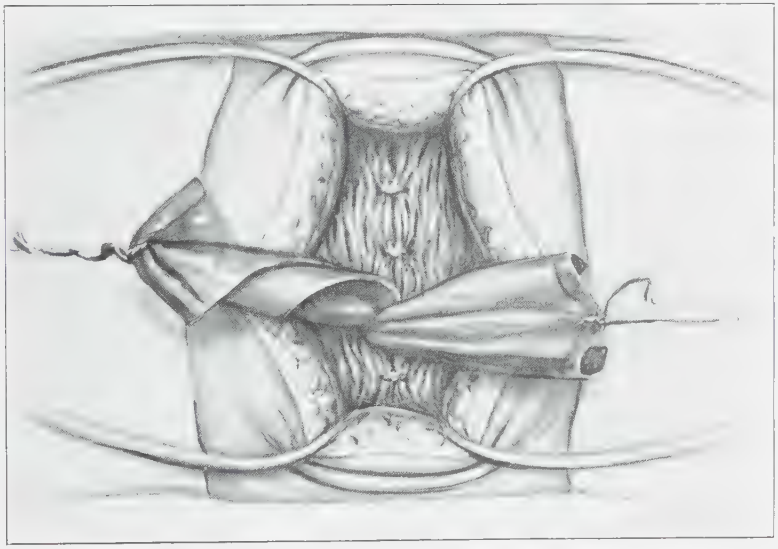

Fig. 66.—The midribbon muscle split has been sutured up to the point where the packs emerge. The resulting temporary muscle defect should be at a higher level than the skin scar so that there will be no adhesions connecting the skin with the trachea.

remote from a more slender or compact drainage material. It has extremely little value as far as hemostasis is concerned, however, being distinctly inferior to gauze in this respect.



Fig. 67.—The skin has been closed except for the small openings at either end to accommodate the drains. The inner halves of the two drains take care of the deep defect, while the two halves outside the muscle layer completely drain the large space beneath the skin flaps.

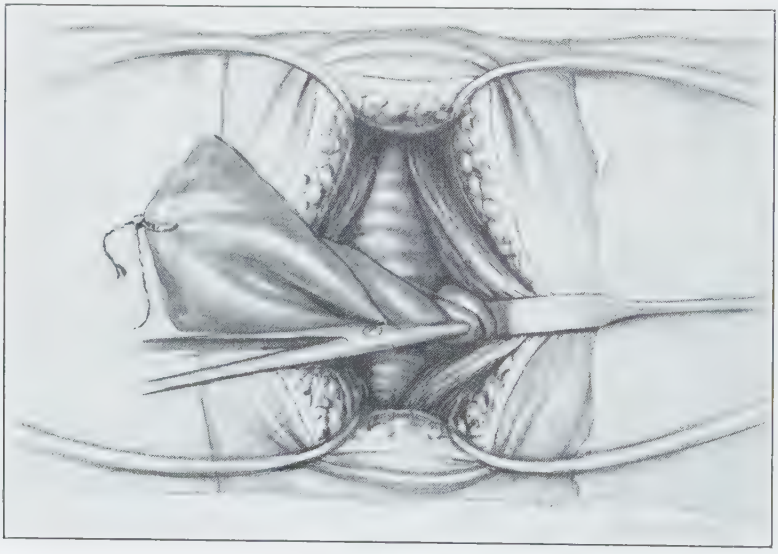

Fig. 68.—In this instance, one lobe only has been removed, therefore but one rubber pack is inserted, after which the midribbon muscle split is closed as in Fig. 66.

We hold the walls of the cavity wide apart after completing hemostasis, then fill the cavity with 95 per cent alcohol before inserting a rubber pack (Fig. 65). This is intended to cause the sealing of tissue surfaces and prevent absorption of thyrotoxic substances that may leak from cut surfaces. This seems

Fig. 69.—The single strip of rubber is carried across from the midline muscle defect to one angle of the wound, from which it emerges.

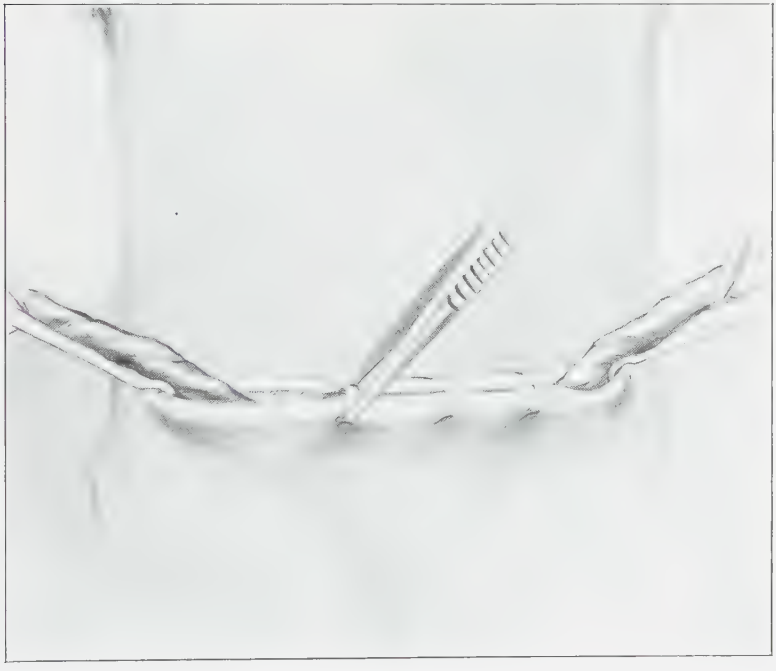

Fig. 70.—The skin wound is closed with metal clips. They save time where there is urgent need for completing an operation. It will be noted that the skin is always completely closed in the midline of the neck. We never allow drainage material to come out at any point except at the angle of a skin incision. In this way the trachea is protected from becoming adherent to the skin with the result that the act of swallowing causes objectionable tugging of the skin scar.

to exert little if any influence on healing processes, since such wounds after removal of rubber pack in twenty-four hours with closure in forty-eight hours heal very much the same as those that have been closed primarily.

After packing a strip of rubber dam in width calculated to meet the requirements of such a case in each lateral cavity, we place one suture in the ribbon muscles exactly beneath the point where the lips of the skin wound will meet, one rubber strip emerging above and the other below this muscle stitch. These rolled-up rubber strips are then crossed in the midline (Fig. 66) and each brought out at the angle of the skin incision opposite the defect it drains (Fig. 67). The middle third or more of the skin wound is closed and the arrangement becomes identical with that in which tubes are used. In this way we succeed in widely separating the skin scar from the trachea. We find ourselves inclining more and more to the rubber pack when the wound must be kept open. The quality of a surgeon's hemostasis should improve with increasing experience and with decreasing need of a pack having hemostatic properties; we naturally employ to an ever increasing extent the form of material which possesses every one of the other desired qualities in marked degree.

## CLOSURE AND DRESSING

Closure of the wound is of three sorts in our clinic at least:

Primary complete.
Partial (primary).
Secondary.

Since these are so entirely different, one would hardly expect to see necks years after thyroidectomy at which the keenest observer must take a second glance even at close range before the faint "collar" scar can be detected, any of the above methods of closure having been employed.

### Primary Closure

Primary closure (Fig. 71) is always done where there are no contraindications just as stated in the chapter on Drainage. The more nearly a wound is closed, the more uncomfortable it

will be for a few days because of (a) serum and blood collections, (b) swelling after novocaine infiltration, (c) edema from traumatism, (d) tight sutures, (e) pressure of dressings, (f) pain upon movement, (g) pain and difficulty in swallowing.

To close the rarely cross-cut "ribbons," raise the patient's head to take the tension off the muscles, and approximate the holding clamps.

In cases in which each lateral lobe is exposed through a separate ribbon slit, sew each separately. All veins cut in rib-

Fig. 71.—The completed primary suture of the skin wound as contemplated in the technic of ideal thyroidectomy.

bon muscle divisions are easily controlled by suture. Smooth edge-to-edge approximation of muscles with bunchings means much from a cosmetic standpoint, while if this is not given careful consideration, depressions mark ununited areas.

No matter how muscles have been divided, it is a surgical axiom that muscle sutures barely tight enough to approximate will cut; in addition edema makes them tighter after a few days. Catgut should absorb early, else it will produce serum. Especially is this true unless the suture material be of the very finest.

Typical closure is marvelously facilitated and simplified as well as shortened as a result of making skin flaps and a midribbon split. Nothing is required but about three sutures closing the midslit in the platysma-ribbon layer after which a few metal clips close the skin and at the same time produce hemostasis in vessels needing otherwise to be ligated. These clips by everting skin edges produce the broadest possible approximation, hence, if they are removed in twenty-four hours, before they produce slight pressure atrophy or necrosis, the resultant scar is most sightly.

If the well-known Mischel wound clips are not available or desired, I recommend that one use a noncutting No. 12 needle (on skin) swedged on 0000 chinese silk; such needles make tiny skin holes and the sutures if drawn loosely cause no cross marks. The skin edges must meet as they did before division, that is, the tiny marks made across the line of incision with this point in mind when marking the incision line must be brought together point to point.

Special care must be taken to see that the skin edges abut rather than lap over, since any turning in of the edges results in one lip remaining thicker than the other, which accident usually affects particularly the upper edge of the wound.

Mrs. B. (January, 1921) had an unusual amount of turning in of the skin edges for a long time after interrupted skin stitches were tied. The needle holes, however, are the worst features of her scar.

This and similar cases influenced us long ago to save the patients one of the objectionable features of the scar by removing stitches as well as clips at the end of twenty-four hours and thus avoiding decubitus.

As stated under "drainage," I have never had to open a completely closed neck for any surgical reason, still I must admit that only an occasional wound that has been completely closed heals, in my experience, without ever a drop of serum being thrown out. Surely nothing is lost, however, by striving for the ideal, since late escape of serum is not wholly prevented by drainage no matter how it is carried out.

Fig. 72.—Introducing a subcutaneous silkworm suture which is left loose so that all wound edges remain apart, displaying the rubber pack when dressings are applied. The same form of partial closure is equally applicable to the complete collar incision.

Fig. 73.—The skin edges being satisfactorily coapted when the subcutaneous suture is approximated at the end of twenty-four hours. (The rubber pack has just been removed.)

## Partial Primary Closure

Partial primary closure may be accomplished in two ways, either by definitely closing the median portion of each wound layer, but leaving them open to the greater part of their extent, or else running sutures may be inserted over packs and drawn up to full tension after removal of gauze or rubber.

Secondary muscle sutures of catgut should be placed at the time of the operation and thus save the patient all the pain of secondary insertion or secondary anesthesia. There is no pain

Fig. 74.—The one skin clip has approximated the middle of the two wound lips. The ends of a pack are seen coming out through each open end of the wound. These are usually closed secondarily, although this is not always necessary.

accompanying the removal of a rubber pack and the tying of sutures if the flaps have not adhered.

It is an excellent plan to insert at operation a running silkworm-gut suture in the cross-divided cervical fascia and platysma covering the ribbon muscles. Closure of this layer must be made at some time, since it is never automatic as is the case where muscle fibers are split longitudinally. Secondary suture of the ordinary variety can hardly be accomplished without gas which could not be thought of in one of our cases (February, 1922) on account of pneumonia. One need not concern himself

about the skin wound in these cases, since it automatically tends to approximate its edges in a fairly satisfactory manner.

A form of skin closure which has many advantages of both the open and the closed method of wound treatment consists in introducing subcutaneous silkworm sutures primarily (Figs. 72 and 73), but leaving the wound edges gaping for twenty-four hours, provided the patient is very toxic or the hemostasis is unsatisfactory. The running suture in the subcutaneous layer,

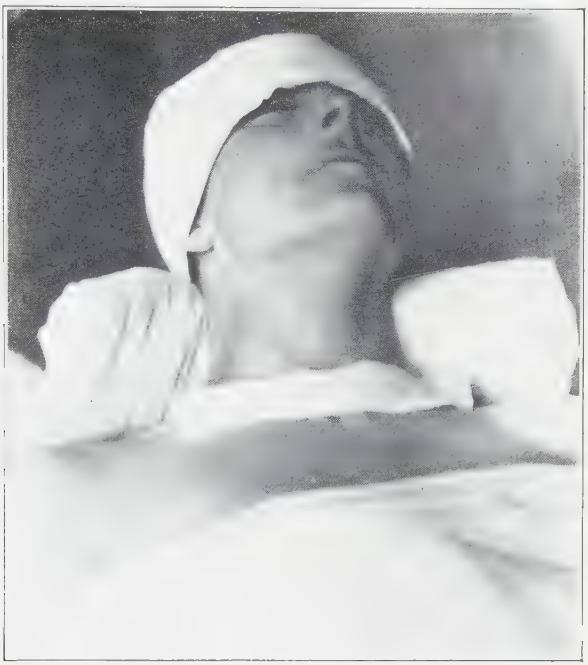

Fig. 75.—A strip of gauze covers the suture wound, while a large sterile cotton gauze-covered pad is seen behind the patient's neck.

left loose to be tightened later, surely is easily and quickly inserted on the table (collar incision). It holds the pack in place and allows free escape of fluids. Twenty-four hours later the skin has almost come together over the pack, profuse drainage having taken place. After the pack is withdrawn with perfect ease, the running suture is drawn up without discomfort to the patient and the skin edges lie in almost as perfect apposition as if sutured, with no tendency to inversion.

The skin edges unite surprisingly well after the silkworm

strand is drawn taut, to be left in place for a few days. The further advantage is thus secured of being able to reseparate the wound lips, if need be, for drainage purposes and then to draw them together again at will. The average patient is not greatly disturbed by such treatment, though there are times when a whiff of gas may be deemed advisable.

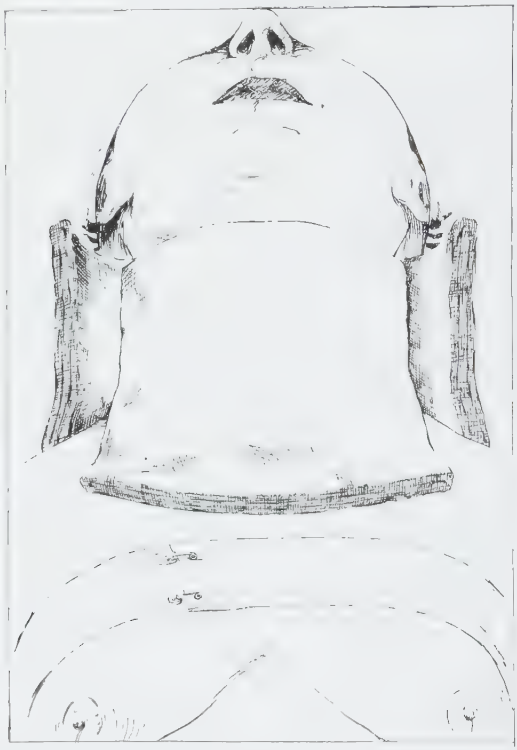

Fig. 76.—A gauze-wrapped cotton pad behind the neck, a second in front, and a strip of bandage around the upper chest.

As was stated in introducing this phase of the subject, clips or sutures are often used to approximate primarily a small portion of a toxic patient's wound as in the following instance: Miss S. (January, 1925) had the second half of a highly toxic exophthalmic goiter removed through a collar incision which was considerably longer than half of the one we customarily employ because the lobe reached well over the midline, being approximately the size of the largest lemon; then the deep defect, as well as that beneath the skin flaps, was loosely packed

with gauze. One skin clip approximated the very middle of the two flaps (Fig. 74). The packs were removed in twenty-four hours, but the girl remained so toxic for several days that there was never a time when we thought it safe to apply more clips. When she had cooled off sufficiently to warrant such a procedure, the skin edges had so accurately approximated themselves that no further closure was deemed necessary.

Fig. 77.—Actual photograph of the dressing material in position as outlined in Fig. 76.

## Secondary Wound Closure

Our success with the open neck in the "emergency" cases may with good reason lead us to treat many other patients so. The operation is short, there is no retention, the neck is comfortable, and the scar is often ultimately about as good as any other.

Secondary closure is, of course, extremely easy where nothing is required but drawing up sutures which have been loosely inserted at the time of operation, but it is quite another matter to apply fresh stitches or clips to midribbon muscles

and skin after the packs have been removed. I have done this in many instances under local anesthesia, although I must admit that to my own thinking the closure itself would entail very little more suffering than has the infiltration in sensitive subjects. Gas should always be given to these patients.

As to the *time* that should elapse before secondary closure should be made, this depends wholly upon the patient's needs

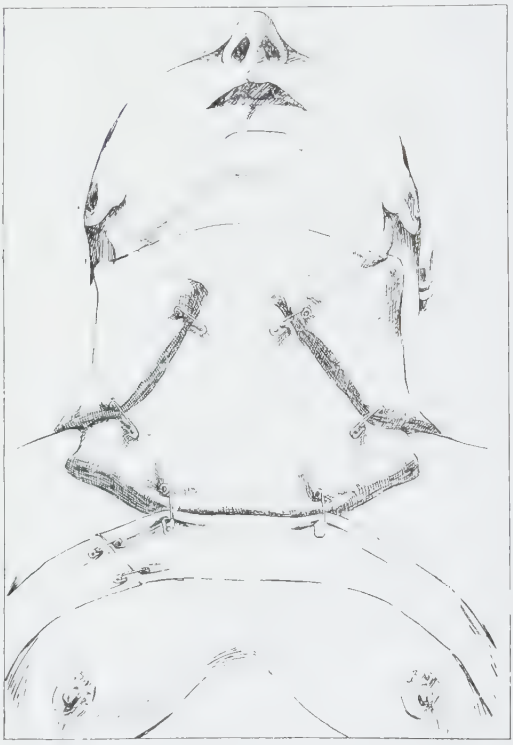

Fig. 78.—Diagram of packs from Figs. 75 and 76.

so far as open wound drainage is concerned. Other things being equal, a better cosmetic result is obtained the earlier the wound is closed. It is our custom when we make secondary closure twenty-four hours after packing an especially large cavity with rubber to leave a guttered rubber tube until drainage ceases. Drainage will persist especially long from an intrathoracic cavity since part of the walls of such an one are rigid and cannot readily collapse as do the soft tissues surrounding a cavity situated wholly above the clavicles.

One is surprised at the length of the period a neck may remain open in some patients and still be treated later almost as though it were a primary wound. Secondary suture of a collar incision left open five days after gauze pack has occasionally given so ideal a cosmetic result that no one could suspect that primary suture had not been used.

Mrs. K. (December, 1924) had a bilateral resection for toxic adenoma followed by a convalescence so stormy that it never seemed safe at any time to close the lips of a collar incision

Fig. 79.—Photograph of the patient on whom the packs have been pinned together and the lower edge of the one in front pinned to a binder which encircles the patient's upper chest.

which had been packed wide open. She was intensely toxic and so delirious that she could hardly be controlled at all. It was ten days after the operation before she improved to the extent that it seemed safe to make even a partial closure. At this time one silkworm suture of the mattress type was introduced in the midline and left in place for seven days. When it was removed the wound edges were found to be approximated to a fairly satisfactory degree, although nothing at all had been done with them excepting at this one point. This patient was seen in September of 1925, and while the upper wound lip is

thick, she is so well satisfied that she refuses further interference.

## Dressing

The dressing of a goiter wound is very simple and is well shown in the accompanying illustrations. A narrow strip

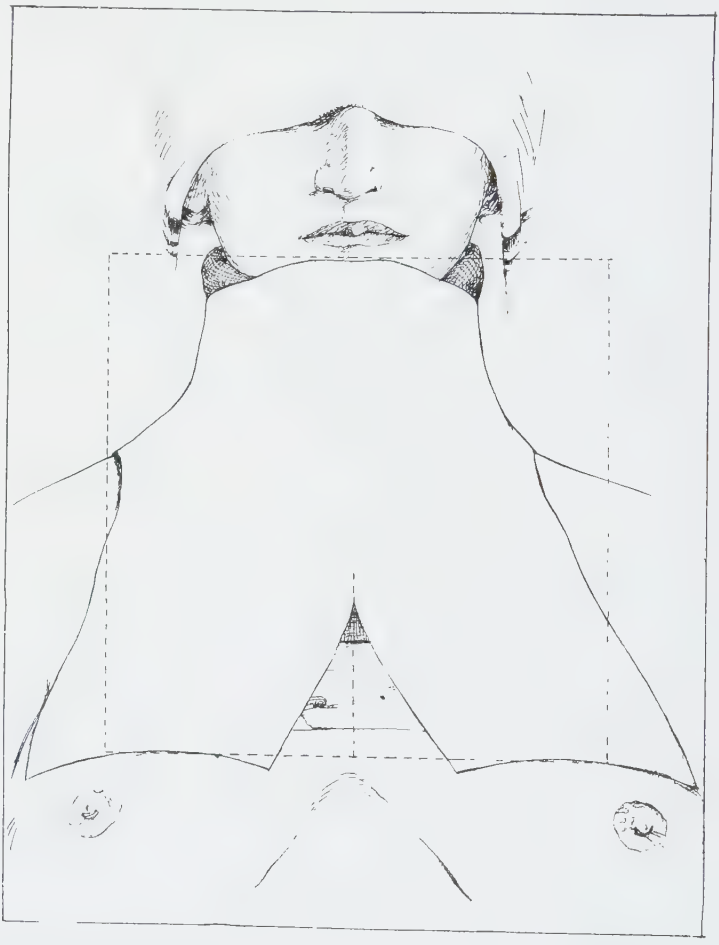

Fig. 80.—A large square of adhesive plaster is split at its lower edge, then applied from the chin to the chest wall in such a manner as to protect the dressing from being soiled by vomitus, etc. Dotted line shows original size of adhesive.

of gauze is placed over the skin incision and a large gauze-covered cotton pad is placed at the back of the neck (Fig. 75). Another pad, similar to that used on the back of the neck, but a little shorter, is placed over the wound (Figs. 76 and 77), and

the ends of the back pad are brought over those of the front pad and pinned securely to it as shown in Figs. 78 and 79. A muslin band is placed around the patient's body just beneath the arms and well up on the chest. To this the lower edge of the front pad is pinned to keep the whole dressing from slipping (Fig. 79). This adds materially to the patient's comfort.

After the dressing is in place, a twelve-inch square of adhesive is attached at its upper middle third to the chin just below the lip (Fig. 80), and allowed to extend down over the dressing, apron fashion. A short slit at the lower end of the square may be made to relieve any strain and to permit the strip to fit comfortably. This prevents soiling of the dressing by vomitus or other fluids from the mouth.

This form of dressing acts at the same time as a most excellent splint for the sensitive neck. Limitation of the patient's movements by this means is highly conducive to her comfort. The use of a voluminous dressing behind the neck was prompted by our experience with soiling of pillow and bedding as a consequence of all wound fluids tending to gravitate toward the back of the neck. No dressing applied to the front of the neck alone is adequate.

## CHAPTER XV

## THE FOUR TYPES OF THYROIDECTOMY—INDICATIONS FOR EACH

At this point we shall consider the four types of operation which are employed in our clinic for the removal of thyroid tissue.

There are three collar incision types:

1. Ideal bilateral resection (closed).
2. Cross-cutting bilateral resection (drained).
3. Unilateral resection (open).

The fourth type of operation is the *simplified* unilateral resection (open).

Our experience teaches that we should match the operative undertaking to the type of patient as far as possible rather than make all patients with their varying needs conform to one standardized technic. It may be safely said that some one of four types of thyroidectomy will meet the requirements of any patient who is ready to have thyroid tissue removed, although we are unable with less than four to cover the great variety of cases.

One must become sensitized to the particular needs of the various types of goiter patient before it is possible to separate them into our four operative classes. The types shade into each other so imperceptibly and the condition of the individual changes so rapidly that accurate segregation is difficult.

Though we take these four operative procedures as an outline, still circumstances will force the operator who is at all elastic to vary them to the extent that an almost infinite variety of procedures will result. I shall state very briefly that we accept no one symptom, physical sign, or laboratory finding as of paramount importance in this connection. What we do is to weigh the whole clinical picture in the light of our experience and neglect to make none of the time-tried laboratory tests, but are, I must say, inclined to be influenced by them only when they are confirmatory. I am so frequently asked what value metabolic rate or some other single feature of a goiter

problem influences us most, that I reiterate with emphasis that no *one feature* of such a case can ever prevail over all the others. In an exophthalmic goiter case a study of metabolic rate means more than it does in the toxic adenoma patient, while in the latter the myocardium is decidedly the matter of chief interest.

I believe that I can say with safety that those connected with our clinic value five features of a goiter case in this order:

1. Myocardium.
2. Kidney function.
3. Nutritional balance.
4. Patient's self-control.
5. Metabolic rate.

One will by reading the chapter on The Ideal Clinic, page 356, gain the impression quite correctly that the establishment of a diagnosis as well as of surgical indications should be by no means a one-man matter; on the contrary it is in our clinic at least a thing of staff cooperation. It would seem that no less than five men should concern themselves at frequent conferences with these elusive problems; namely, (1) an internist especially interested in metabolism; (2) an internist especially interested in the diseases of the vascular system; (3) a laryngologist who makes a special study of this field; (4) a surgeon who has daily experience in thyroid work; and (5) a pathologist with a large amount of goiter material.

We often go so far as to say that the internist rather than the surgeon should set the date for a thyroid operation. The former is sure to see only the patient's interest, whereas the operator cannot wholly divorce himself from considerations of convenience and opportunity. It is taken for granted that he will have the patient's interest at heart, but there are subconscious tendencies which make it perhaps safer for the choice of an operative moment to be in the hands of another.

### Analysis of Various Types of Procedure

The fourth type previously mentioned, the simplified unilateral resection, will be left for wholly separate consideration, and at this point the three types of operation which are done through a collar incision will be taken up.

### 1. Ideal Bilateral Resection (Closed)

The ideal bilateral resection is a method of removing a moderate-sized goiter where the patient is an excellent risk, either of a nontoxic type or one so nearly so that no postoperative complications are to be anticipated from a rather complete operation done without drainage. It is always a one-stage procedure. It is done invariably through a midribbon muscle split, and in order to justify the word "ideal" in the title, the wound must be completely closed by the restitution of all divided planes.

This type of operation is considered a routine in our clinic and is done as a matter of course, unless there are definite contraindications which are taken up in detail with our other types of resection.

It will not be necessary to go greatly into detail here regarding the ideal operation, because every step of it has been thoroughly considered in the sections on the Skin Incision, the Platysma, the Ribbon Muscles, the Upper Pole, Display of the Goiter, The Actual Resection, and Drainage and Closure.

By studying the material which has been considered under these seven section headings, any one can reconstruct for himself the steps which go together to comprise what seems to me at least worthy of the somewhat ambitious title "Ideal." It is a technical procedure which will have an appeal for the ambitious surgeon because it requires something approaching technical perfection at every step, emphasizing especially accurate hemostasis.

### 2. Cross-Cutting Bilateral Resection (Drained)

The cross-cutting bilateral resection is sometimes a multiple-stage operation, a matter which is self-evident when one states that it is primarily intended for patients who are not always perfect risks, which will be seen when we go more into detail.

It is my custom always to drain and even sometimes to pack cavities the result of the removal of the enormous glands for the treatment of which this operation was primarily devised. It is particularly applicable to intrathoracic goiters, greatly facilitating the removal of the enormous adenomata of this type which are occasionally encountered.

Another type of goiter which is difficult to remove without cross-cutting the ribbon muscles is one tightly fixed in its position by virtue of adhesions to surrounding structures or one of

Fig. 81.—The site of the intended skin incision is indicated by the heavy line, while the dotted line indicates the site of the intended transverse platysma and ribbon muscle incision, 3 or 4 cm. higher. The knife is seen scratching the skin in such a way that the edges of the flaps may be approximated exactly as they originally lay.

such a consistency that it cannot be readily moulded in an effort to deliver it through a more conservative muscle opening. Attention is especially called here to the malignant thyroid and to the rarely seen goiter which is affected by woody thyroiditis.

This is a type of operation sometimes intended to meet the special needs of two types of patients: (a) Those who are mildly toxic, who seem well enough to have both lateral lobes removed at one sitting, but who might "flare up" and are hence

Fig. 82.—The knife is seen elevating the skin flap just long enough to permit of the transverse muscle incision. It will be noted that nothing at all is done in the way of undermining the lower skin edge.

considerably better if the wound is left wide open instead of being tightly closed. Mrs. G. (January, 1922) was such a patient who had gained thirty pounds after a ligation. (b) Another class in which this technic is indicated is composed of those who have enormous simple (nontoxic colloid or cystadenomata) goiter so large and vascular that it is practically impos-

sible to control all the bleeding points and at the same time to obliterate all the cavities, especially substernal ones, left by removal of the tumors. No more oozing will occur after forty-

Fig. 83.—The platysma is being cross-divided while the upper skin flap is retracted.

eight hours, when all clots may be removed and such wounds completely closed under gas.

Another type of patient to whom this method is applicable is the short, thick-necked individual in whom it is very difficult

to get sufficient access by any other than the cross-cut ribbon muscle plan. For detailed description, consult the section on Ribbon Muscles (page 178).

Fig. 84.—The platysma wound is seen wide open and the ribbon muscles are being cross-divided over a clamp which has been thrust beneath them. This prevents accidental injury to the goiter.

As the goiter grows it cannot expand backward because of the cervical spine, or laterally because of the strength of the sternomastoid muscles; however the ribbon muscles with their thin elastic coverings offer less resistance and permit the

goiter to grow straight forward. Later by virtue of its own weight it will drop down. Thus in the course of time these small muscles are so stretched and thinned out as to be hardly recognizable.

The skin incision (Fig. 81) employed in this type of operation is the regular marked collar incision. Very short skin flaps (Fig. 82) are made, the lower one merely long enough to allow of suturing the upper to it. Following the skin incision a short cross-cut is made through the platysma (Fig. 83) and ribbon muscles (Fig. 84) down to the thyroid, just large enough

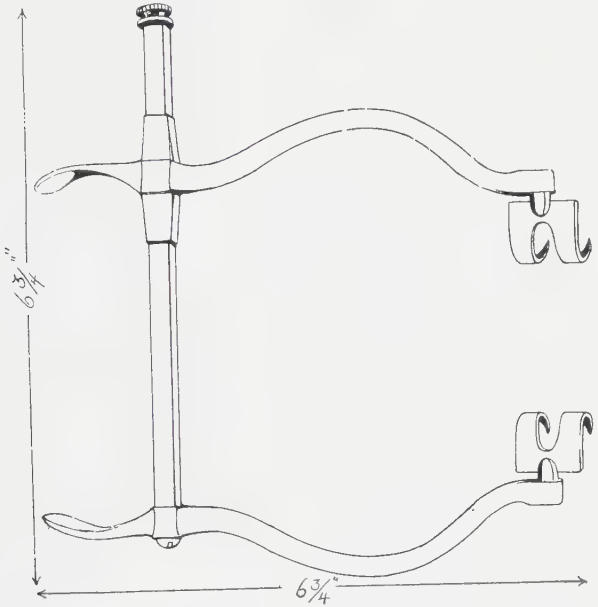


Fig. 85.—Author's automatic spreader for retracting lips of goiter wound.

to enable the surgeon to elevate these two layers in order to completely cross-cut both of them at one time. The ribbon muscles are cross-cut because it allows of much shorter skin flaps, makes the goiter most accessible, thus shortens the procedure, and leaves the neck most wide open (Figs. 85 and 86).

No cross compression clamps are used to crush muscle tissue, but we allow veins to be seen and caught as we encounter those which might begin to bleed only after dressings had been applied. An extended description of the actual resection of the goiter may be found in Chapter 191, and is therefore not re-

peated here. We usually ligate everything on the stump, but clamps can advantageously be left in place. The defect is packed with rubber and the neck sewed up two days later.

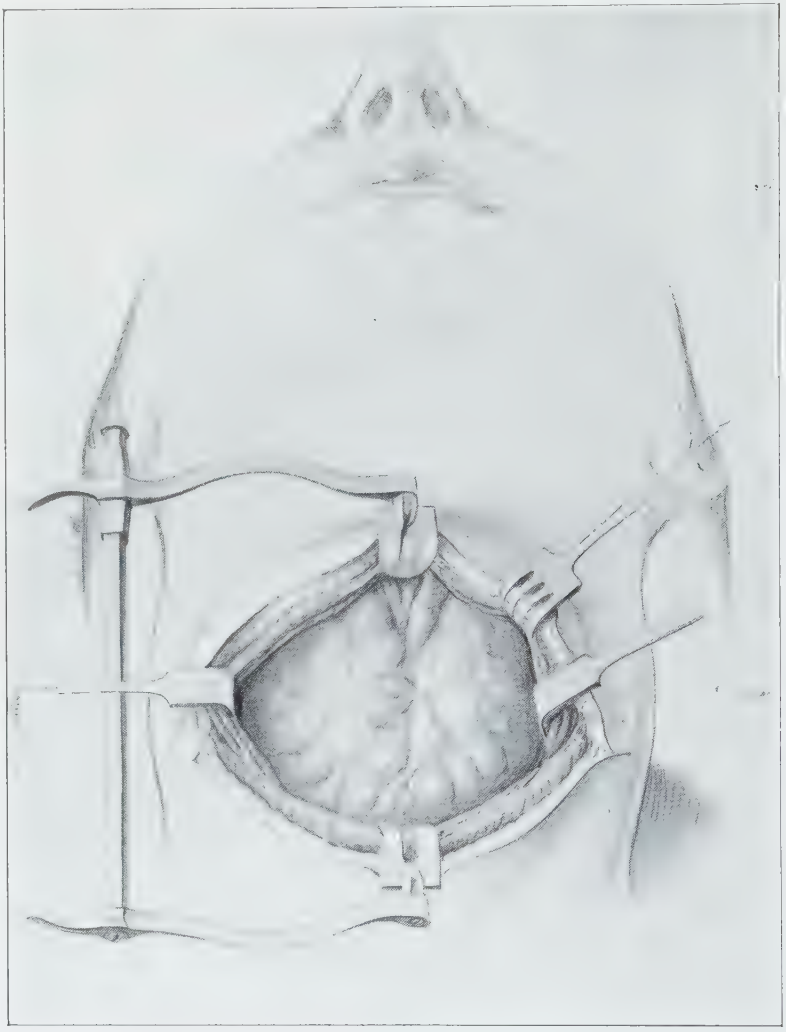

Fig. 86.—The automatic spreader holds the upper and lower skin fat muscle flaps wide apart; then lateral retraction of the sternomastoid when needed for the moment, permits display of the goiter.

The closure (Figs. 87, 88, and 89) of such a neck is a matter of greatest importance where platysma and ribbon muscles have been cross-cut, since the widely retracted unsutured muscle ends leave an unsightly defect (depression) where it cannot

escape attention, and at the same time prevent the skin edges from automatically coming together. These considerations are of no importance as a rule where secondary suture can be em-

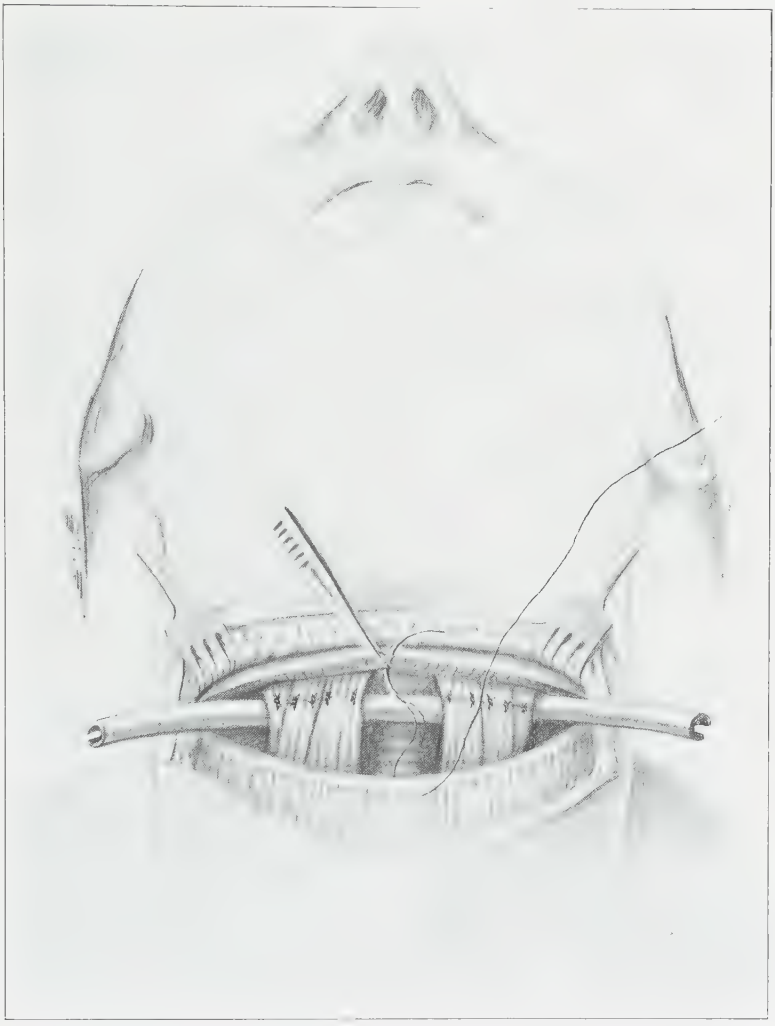

Fig. 87.—The goiter now being out, the ribbon muscles have been closed over a guttered cross rubber drain tube, and the first suture is being inserted in the platysma fascial layer.

ployed after twenty-four to forty-eight hours, but in the case of Mrs. V., (February, 1922), pneumonia which complicated the recovery prevented closure of the wound for four days. This is to be considered in view of the fact that there is a definite

Fig. 88.—The left figure demonstrates the head far back and the wound gaping widely in consequence; the right figure shows the wound edges well approximated and closure facilitated by the simple elevation of the head into a more or less customary position.

Fig. 89.—Skin closure is begun by approximating the two halves of the transverse median scratch described in Fig. 81. The ends of the drain tube are seen emerging from the extremities of the skin wound and closure will be continued up to them.



Fig. 90.—Large multiple adenocystoma of thyroid illustrating well the type which is thought to indicate the technic illustrated in Figs. 81-89.



Fig. 91.—Lateral view of same patient shown in Fig. 90.



Fig. 92.—Front view of patient two months after operation.

Fig. 93.—Lateral view of same patient.

limit to the period within the span of which it is possible to approximate cross-divided muscles unless previously stretched to an unusual degree by a very large goiter beneath them. Failure to close such a wound might conceivably result in respiratory symptoms since the exposed trachea would otherwise be covered by skin alone.

Detailed description of the individual steps of the operation have been omitted here since the illustrations and their appended legends seem more adequately to fulfil this need than could any mere statements here. In epitomizing the aim and rationale of this operation, let it merely be said that the primary purpose of it is to gain the greatest possible exposure in the most direct manner which will enable one to overcome unusual difficulties incident to size, location, consistence or pathologic attachment of a goiter (Figs. 90, 91, 92, and 93) which cannot best be removed by the ideal technic.

### 3. Unilateral Resection (Open)

The unilateral resection operation is essentially a life-saving procedure. It is part of a multiple-stage operation for the patient who constitutes an unknown risk. It may be considered from the standpoint of toxicity or from the standpoint of heart damage, but suffice it to say that it is the operation of choice if there be any urgent reason for removing a thyroid when the safety of an operation cannot by any means be assured. Our simplified (with diagonal skin incision) lateral operation is to remain the choice for men or for women of no personal pride, but in young women we prefer to use the collar incision about to be described. This technic gradually evolved itself out of numerous interesting experiences.

**Development.**—Being unable to determine Mrs. L's (October 27, 1921) resistance to operation four months after ligation (rate +60) I did not dare *handle thyroid tissue* without some preliminary tryout, so I made ordinary large collar flaps, retracted both sternomastoid muscles, split ribbon muscles on both sides, packed gauze down on both lobes and placed flat rubber under the flaps after ligating every vessel encountered. This procedure seemed to have the great advantage of blocking extensive tissue spaces before thyroid juices were spilled; by use of

alcohol preliminary and glycerin later in the deep defect, this feature of the operative danger was further influenced. This plan of exposing the thyroid, then waiting two days, seemed to have no disadvantage at all. Mrs. L. (October 29, 1921) surely was not hurt by the preliminary step, while the removal of one lobe though intrinsically difficult, was simple and brief two days later.

Another case which directed my attention toward the final development of the unilateral technic was that of Mrs. J. (January 12 and 15, 1922) who had large lobes removed at separate periods. To avoid leaving the ordinary collar incision open several days with attendant infection, delayed healing, and unsightly scar, I put on clips twenty-four hours after *first* lobectomy, reopened second half of wound three days after first lobectomy to remove second lobe, then made a second closure of it after twenty-four hours more. Ultimate wound healing was all that could have been desired. Union was certainly much superior to that where closure has been postponed four days as would have been the case under the older plan. There was never marked separation of edges; there was exudation of serum only in moderate quantity. The healing process was of relatively short duration. It must be kept in mind that one never sees healing "per primam" unless closure has been made at once after thyroidectomy.

It had not occurred to me up to the time of the last-mentioned case to elevate only half of the skin flaps covering the lobe to be removed, since the second operation was relatively simple if the entire skin flaps had been elevated at the time of the original collar incision. Very little skin has to be elevated to expose the corresponding anterior border of the sternomastoid muscle if but one lobe is to be removed; therefore why make more than one-half the usual collar incision? *Infiltration* of the edematous two or three day old flap is painful and unsatisfactory; gas must be used for the second side, at least for the earlier stages, while the field is always untidy.

At the time of which I am writing I was still taking out the second lobe through a midribbon slit which had been opened from one to several days previously. This was done rarely, however, except when the necessity arose of quickly terminating

during its course, a procedure which had been planned as a bilateral resection originally. The second sitting by this method was greatly facilitated by dissecting free the anterior surfaces of both lobes at the same time, then inserting a heavy traction suture in the one to be left, and wrapping the exposed area in thin rubber for identification a day or two later. The disadvantages of the method were (1) a general anesthesia was needed for handling the tissues covering the thyroid after they had been exposed a day or more, (2) identification of all such structures and of the lobe itself was difficult on account of fibrin deposit everywhere, (3) the muscles were edematous, infiltrated, and shortened and hard to handle, (4) since one worked through a potentially infected field, the danger of spreading infection was very great.

From a recital of the foregoing cases and arguments it will be seen that I was groping about at this time for some type of unilateral resection which would approximate in efficiency the simplified unilateral resection with its oblique lateral skin incision, but one of such cosmetic value that it might be used on the neck of a young woman. It suddenly occurred to me on April 27, 1921, while operating upon a Mrs. S. that one-half of a collar incision can be very readily so shifted by retraction as to constitute the same sort of exposure afforded by a skin incision paralleling the sternomastoid muscle.

In this manner I was able to split the sternomastoid muscle longitudinally and carry out with complete satisfaction the direct lateral approach to the thyroid lobe which had seemed so quick and easy on the male subject, but productive of a scar unsuited to the feminine sex.

This was all very well so far as the safety of the patient was concerned because it at least guaranteed a multiple-stage procedure, although technically as compared with later developments, it left very much to be desired. I feel that the multiple-stage operation has a distinct field of usefulness in very bad risk patients in spite of very evident discomfort and disappointment as far as the sufferer is concerned. Particularly applicable at all events is our unilateral operation where the isthmus and second lobe remain temporarily undisturbed. This technic guarantees the short operation and accurate hemostasis

so much desired in patients who are bad enough risks to demand unilateral operation. As an example of the number of steps that have been necessary in some such patients, I cite the following: Miss B. had (1) first ligation done April 4, 1921; (2) second ligation April 8, 1921; (3) the right lobe removed on June 17; (4) the left lobe removed on June 21; and (5) secondary closure was made on June 23. The neck was open six days. When she was seen five days after closure, there was rather wide skin separation where the drains had come out with the skin edges about a quarter of an inch apart; the middle four-fifths of the wound was solid. On July 3 most of the scar was hard to distinguish from one sutured primarily.

With the same thought in mind, I am sure, Lahey[1] and his associates at the New England Deaconess Hospital in Boston adopted a plan of multiple-stage surgical measures in cases of severe hyperthyroidism in order to bring down the mortality rate; however, they are not too optimistic as to the postoperative reaction and its prognosis. Thyroid patients may go through any surgical procedure and die several hours after leaving the table apparently in good condition; however, because of the inability to foresee the reaction, and because they "feel that the increased operative tolerance and prognostic data can be obtained in no other way," they use and advocate the multiple-stage procedure as we do here in exceptional cases.

**Technic.**—Regarding the technic of this unilateral resection, I wish to state emphatically that it was never intended to take the place of the "ideal" operation. If it be at all practical, it is well to get both lobes out at the same operation; the benefit is immeasurably greater.

Our first two types of collar operation are, of course, always done in the operating room, especially equipped for the purpose, where the light is excellent and all ordinary conveniences are at hand, but I agree with Crile that it is often a serious matter to make two lengthy, arduous transfers of a bad risk patient and expose her to the psychic shock of entering an ordinary surgical amphitheatre. For this reason, the unilateral resection is in many instances better done in the patient's bed or, as I often prefer in summer, on a well-screened open porch where




Fig. 94.—Diagram of skin bridge intended to separate the halves of a collar incision through which two resections are to be done at separate sittings.



Fig. 95.—Photograph of patient illustrating plan shown in Fig. 94.

the freely circulating air supplies oxygen aplenty to satisfy the requirements of any elevated metabolic rate.

I now make the half of the collar incision just short of the midline, leaving a very tiny skin bridge (Figs. 94, 95, and 96) undivided when the second half of the collar incision is to be made a day or two later. It is possible in this way to favor repair more than in any other way.

Owing to the fact that the skin can be "slipped," nothing can exceed the speed and facility with which the sternomastoid

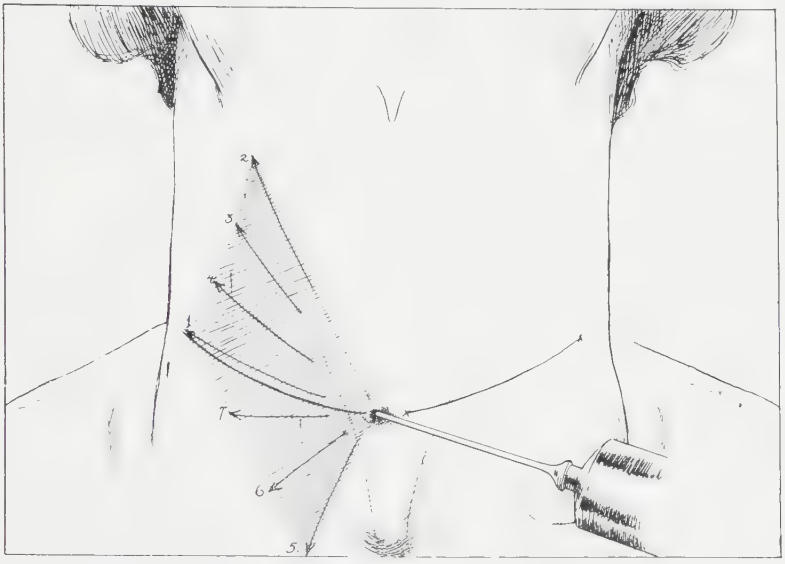


Fig. 96.—Diagram illustrating direction of infiltration needle as well as size and location of skin and subcutaneous area to be anesthetized.

is reached, freed, and retracted after making a short half-collar incision (Fig. 97) and then simply under-cutting the skin covering the anterior border of this muscle (Figs. 98, 99, and 100). This procedure is about as simple as our straight "simplified" incision and leads to no more bleeding.

The sternomastoid muscle has to be retracted backward (Fig. 101) only at the lower end to bare the longitudinally split ribbon muscle (Figs. 102 and 103) near its low attachment far back. The restored (resuming their natural position automatically when the packs are removed) ribbon and sternomastoid muscles will obviate any noticeable muscle defect.



Fig. 97.—The skin incision.



Fig. 98.—Method of dissecting the skin flaps.

If the operator prefers, he may diagonally cross-cut the ribbon muscles instead of retracting the sternomastoids and splitting the ribbon muscles. The former may be slightly easier

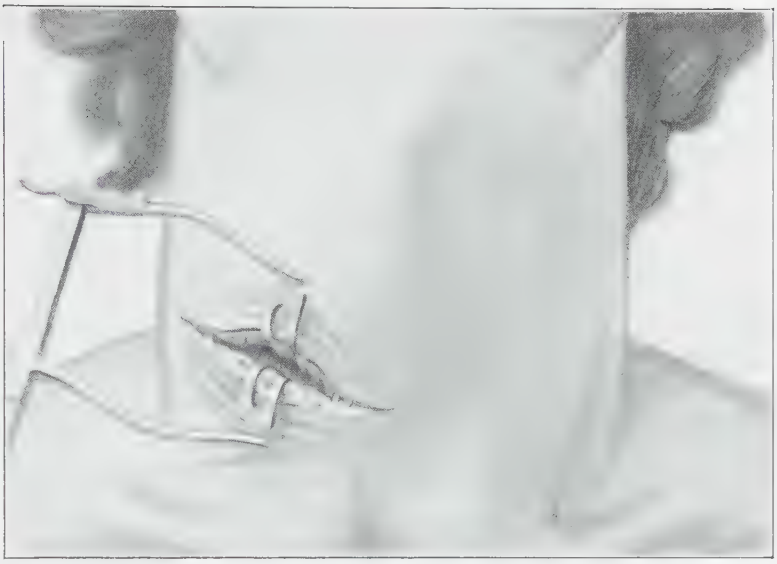

Fig. 99.—The author's automatic retractor, so employed as to transform the direction of the half-collar skin opening into one which follows the direction of the sternomastoid muscle.

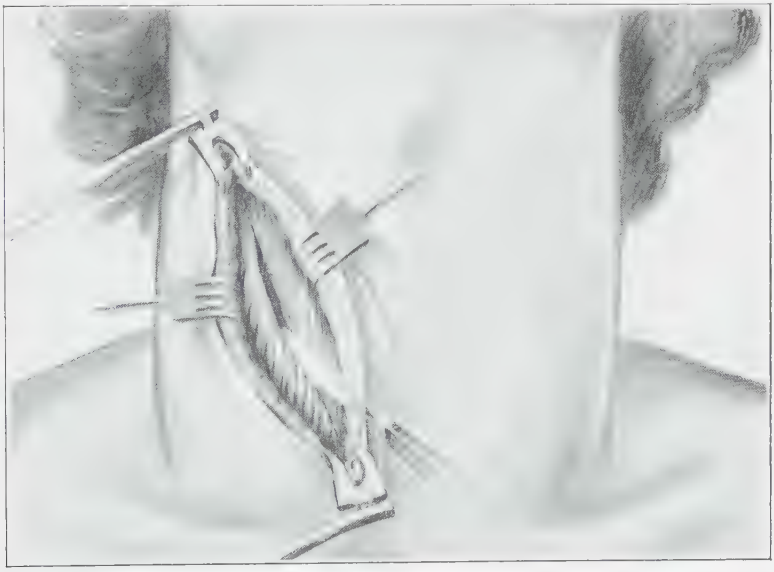

Fig. 100.—Skin flaps are shown mobilized and stretched to the extent that the original half-collar opening is displaced along the course of the sternomastoid muscle. The platysma fibers are being split in the direction of the skin opening.



Fig. 101.—The sternomastoid muscle is being peeled off the deeper layers and retracted backward.

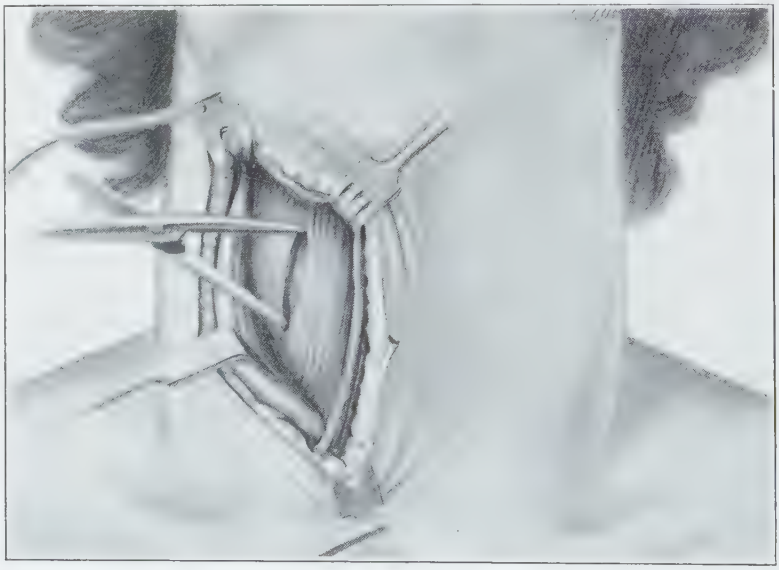

Fig. 102.—Superficial layer of ribbon muscles is being split longitudinally while the lower sternomastoid is retracted backward and the opposite upper platysma is retracted inward.

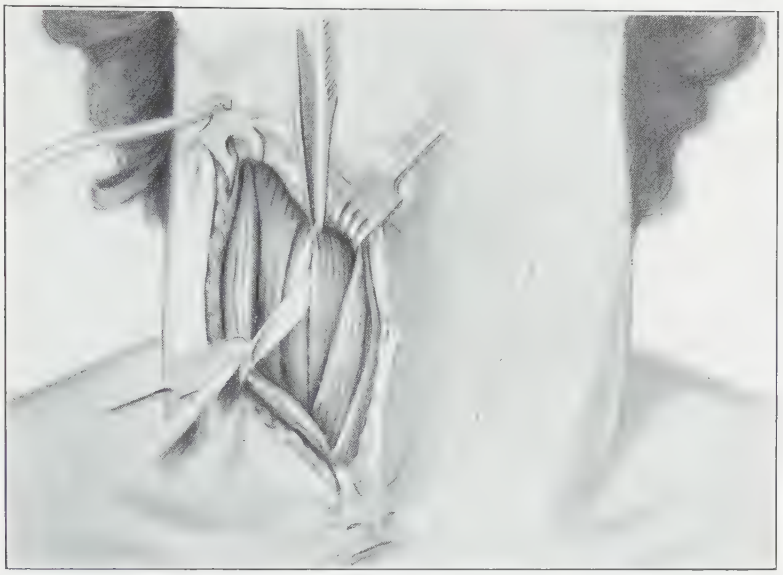

Fig. 103.—Deep layer of ribbon muscle is split longitudinally, while retraction is maintained as in Fig. 102.

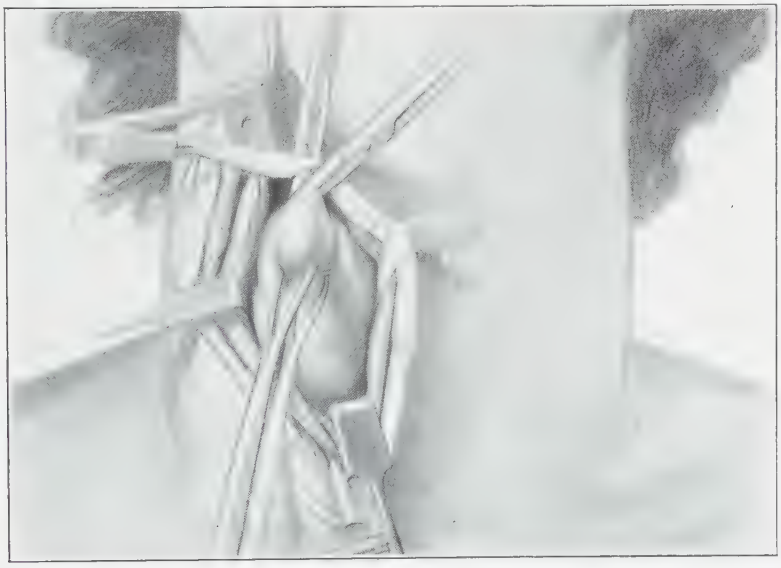

Fig. 104.—The upper pole is completely divided and drawn toward the ceiling before pursuing the succeeding steps which are fully illustrated in the chapter on The Actual Resection.

to carry out, still the latter has the advantage of better automatic subsequent closure (except skin and platysma).

The exposure and amputation of the lobe (Fig. 104) have

been so adequately described in the chapters devoted to the individual technical steps that repetition will be avoided by simply referring the reader to the preceding pages.

Crile and Lower[2] emphasize the importance of leaving the wound wide open in the serious case, dressing it with 1-5000 flavine gauze. They point out three most important advantages: time of operation is shortened, postoperative pain and discomfort are lessened, and absorption of wound secretion is prevented. Aseptic wound secretion causes a "postoperative increase of temperature in normal nonsensitized individuals, but in the hypersensitized exophthalmic goiter patient this reaction may be multiplied many times and become a raging, destroying fever." The wounds are closed under analgesia and local anesthesia in the patient's bed as soon as it seems safe, anywhere from the afternoon of the same day to the second day after operation.

As a rule the pack (Figs. 105 and 106) and clamps (if left) are not touched until two days later when a few stitches are put into the platysma over soft rubber or tube and a few stitches are put into the skin if it is too edematous for clips. They are removed two days later.

The treatment of the stump as well as care of the resultant defect differs in no wise from that described in detail under Simplified Unilateral Resection, Chapter XVI. It must be understood that sutures and ligatures are applied in every favorable case, clamps being left in the wound only when the risk of operation is considered unusually great.

Several wounds after being kept open the best part of a week, had to be supported with adhesive two or three days after secondary suture, since the skin sutures cut through and allowed very slight spreading, although the platysma seemed to hold loosely, at least the flap edges seemed to be in satisfactory though rather loose approximation. Many such patients have eventually presented scars which could not without close inspection be distinguished from primary suture wounds.

Mrs. W. (October 27, 1921) had gut sutures inserted in the platysma and a few skin clips placed on the first side at the time the second lobe was removed, leaving only space for the second deep rubber pack to come out at the lateral angle of the

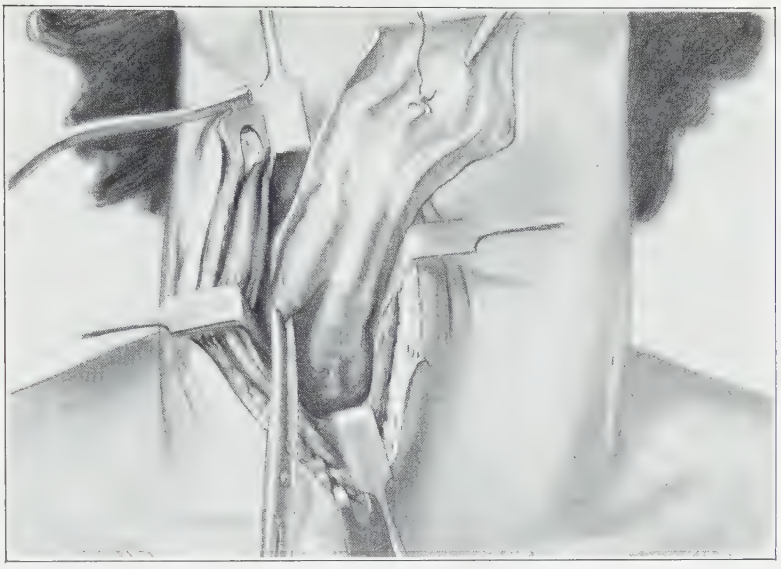

Fig. 105.—Packing with rubber dam the cavity from which the lobe has been removed.

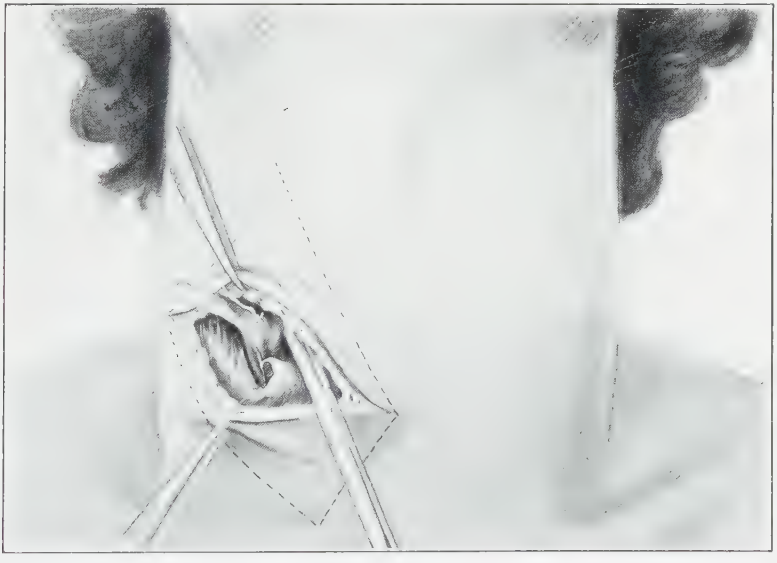

Fig. 106.—Bringing the edges of muscle and skin wounds partly together over rubber pack.

second wound, and hers was the best scar we have obtained in any unilateral case done in separate sittings. Thus, the plan of closing the first half of the incision at the time the second

half is made, seems ideal if only the patient's condition permits two operations separated by only one to three days.

**When Remove the Second Lobe?**—The experience with toxic patients in our goiter clinic shows that marked temporary benefit usually follows the removal of one lobe only, which, however, is almost always followed by a recurrence of symptoms, though this may not come for many months or even a few years. In view of this expectation we never, if it can be avoided, allow a patient to leave the hospital before the second lobe has been removed. The above statement concerns, of course, those toxic or cardiopathic individuals whose condition suggests the wisdom of dividing the operative dose, so to speak, into two parts, as can certainly be done when only half the gland is removed at one time. The reason for completing the second stage during one hospital stay is that these patients are most reluctant to come back after being greatly benefited by the removal of the first half, until convinced by the severity of recurring symptoms that a second operation cannot be avoided. Unfortunately it is then too late in a surprisingly large percentage of such sufferers as have come to us to do anything. Many have died in spite of well-considered medical attempts to put them in condition to withstand the completion of an operation which might have resulted in success if only the second lobe had been removed during the original hospital stay.

This has been impressed upon me by numerous very sick patients who have entered our clinic after unilateral resection elsewhere. They have been unusually toxic. In fact, several of them have died before they were in condition for secondary operation. One must credit the original operator with the intention of ultimately removing the second side; then surely these erratic patients were instructed accordingly, but since no dependence can be placed upon many of them, as we have found in our own experience, it stands to reason that a slight additional risk must be taken if need be, and the hospital stay lengthened as a precautionary measure, in order that a complete operation may be assured.

The secondary operation is never done in less than two days after the first, and is often done on the third day.

Since we have gas analgesia the removal of the second side a day or two after the first, through a half collar skin incision and a lateral muscle split should be much easier than it was when we did not keep the second field absolutely intact at the time of the first operation. It is quite obvious that the second side should be removed in the patient's bed, without her knowing that the operation has been incomplete (first). She does not see the operator before gas is begun, having been led to believe that a pack is to be removed and a stitch inserted. A rubber pack is desirable on the second side since it can come out in one day and the neck thus not be open more than a total of three days. A loose running stitch in the platysma is especially important. With a little infiltration a few clips or stitches may be put into the skin twenty-four hours after the second opening.

Miss K. (February, 1922), had the second lobe removed five days after the first with no more difficulty than if this had been a primary operation. In fact this technic permits of the two procedures being separated by any indicated interval, since the intended second field remains untouched at the first sitting. Miss K.'s neck remained open nine days (first half), then was closed with clips without difficulty. If removal of the first lobe creates a profound disturbance, it will not be safe to remove the second lobe in two or three days, which is probably the allowable period for keeping the neck open. Since it might be impractical to work later on the side opposite granulation tissue, during the period of any normal hospital stay, one will send such a patient home to return a few months later for the essential second lobectomy. In other words never remove the second lobe during the original hospital stay if an extensive long-continued infection has followed the first resection. Miss F. (June, 1924), had such a complication of the original operation that about six weeks were required for complete healing. At the end of that period the second resection was almost impossible by reason of a median perithyroiditis which had spread across the trachea and resulted in the friable lower pole becoming so frozen-in that it could not be dislodged without the use of force and much bleeding as the layers were separated and at the same time the gland tissue torn. On another such occasion I should

wait six months unless the recurrence of symptoms compelled action. (This period was suggested by Kocher as the minimum in which adhesions about a pus appendix might be expected to disappear. May it not also be suggested for other body tissues?)

**Informing the Patient of Partial Resection.**—When the two lateral lobes are removed at two separate sittings, a thing often done in case double resection is considered highly dangerous, the matter of whether to advise the patient that only half of the gland has been removed presents a problem for individual solution.

As a rule nothing is said to the patient about the second lobe until time for its removal as has been stated above. Many manifest no concern, make no inquiry, and can be taken to the operating room heavily drugged under the misapprehension that a few stitches are to be put in or a scar excised. This scheme is probably best when it works, as it saves sleepless nights. Some people like to be petted and soothed and deceived, and readily understand later that the deception was meant for their own good, while others resent an evasive attitude on the part of the surgeon and much prefer a plain statement of facts. The temperament of the patient must be considered in each instance.

On the other hand Mrs. M. (October, 1924), a highly temperamental woman, when informed in the operating room of the necessity of a second operation ten days after the first, became so excited that she had to be returned to bed. The chief cause of her agitation seemed to be that she had not been told that half of the gland remained in her neck. After being fully informed, she quieted down and the next day begged to have the second lobe removed.

On the very day that Mrs. M. was sent back to bed, I removed the first lobe of Mrs. L.'s thyroid. A few hours later she felt pain in one side of the neck only and asked me whether I had removed half or all of the gland. I made a frank statement of facts and told her that only half could be removed with safety and gave her her choice as to carrying out the second procedure during her present hospital stay or after a few weeks' rest at home. She was delighted with my frankness, showed no excitement or disappointment, and continued to cooperate in every way. So it goes in the matter of individual differences.

Younger patients make no inquiry and are much easier to handle; those who are older and more thoughtful usually demand explanations. Frequently, too, in a ward one patient will call the attention of another to the probability that only part of the gland has been removed.

The surgeon must choose his words very carefully in informing a patient that the risk of removing both lobes was too great. Such a statement bluntly made to a very sensitive, nervous patient can do as much harm as the removal of the other lobe. She should without being alarmed be made to feel rather that the surgeon used his best judgment in her behalf and did not do more than her strength would permit at one time.

The choice between the two methods of handling this problem must be left to the reader to settle in each individual case; meanwhile his skill as a strategist will be in no small measure reflected by his ultimate results.

**Indications.**—Roughly, the three types of cases in which this operation is indicated are:

1. Toxic adenoma cases too doubtful for double lobectomy.
2. Exophthalmic cases too good to ligate, but doubtful.
3. Exophthalmic cases that have been ligated but are still doubtful.

The last-named type is well represented by Miss U., in whom it was impossible to obtain compensation and a reduction of her metabolic rate after a trial of four months following ligation. Nothing would help her except the removal of a lobe; she could only stand a minimum of operating; and it was undesirable to badly disfigure the neck of a young lady by a straight lateral incision.

Surely the indication in the average toxic case, since we have no way of accurately classifying them, is to inflict the least possible trauma while destroying the greatest amount of thyroid tissue with some regard for cosmetic considerations.

One may say in general that bilateral resection has been universally accepted as the only means of utterly curing exophthalmic goiter, but in some instances we cannot do this at one sitting in order to minimize operative risk. It is only on rare occasions that we purposely leave a lobe in place; however, the successful treatment of goiter patients, especially those who are toxic, depends in great measure on individualization. The case

of Miss D. S. (August, 1924) illustrates the principle here involved. This girl, less than fifteen years of age with a metabolic rate of 38 per cent, was the subject of such an outspoken exophthalmic goiter picture that something seemed definitely indicated as a preventive of rapid deterioration. On the other hand, one never willingly sacrifices any great portion of both thyroid lobes in an individual who has not attained her complete development; hence, the following procedure was thought to be adapted to the circumstances surrounding this individual case. The left superior thyroid pole was ligated as a test of her ability to stand surgery. No reaction at all was apparent, therefore five days later the larger of the two lobes, the right, was almost completely removed with the idea of benefiting the girl sufficiently to allow of her running along under careful supervision for two or three more years and attaining a fuller measure of development before the almost inevitable secondary flare-up might ensue and necessitate the removal of her second lobe.

One may often look at this subject from many different angles. As an example of the unusual need for a unilateral operation, I have but to call attention to the following:

Not infrequently a patient enters our service with a preexisting lesion of a recurrent nerve, due most likely to pressure. Experience shows this to be more common as an accompaniment of adenoma than of other types of goiter; however, such a lesion is possible no matter what the type of thyroid disease; so that, as a matter of self-protection, to say nothing of the patient's interest, the surgeon must include a laryngoscopic examination in every routine physical examination of the thyroid patient if it is to be considered at all complete and adequate.

While operative damage to the recurrent nerve or one of its branches is not common at the present day, still there are types of goiter so difficult to deliver that no one can guarantee against the possibility of its occurrence in a given instance. Suppose, then, a patient who enters with unilateral abductor paralysis which is unknown to the surgeon, contracts a similar lesion on the second side during the operation. One can readily understand that there ensues immediately a condition which is highly dangerous, one which has resulted fatally in many instances.

The only way to avoid this complication is to do a unilateral

resection on the side where paralysis is known to exist and then postpone further interference until a spontaneous return of function on that side has been observed. Not until then can the normal side be attacked, since it will be seen from the foregoing that the patient who is dependent for breath on half a larynx must never be exposed to even remote possibility of injury to that half, something which cannot be denied as a possibility in any operation done at the present day.

**Advantages of Unilateral Collar Operation.**—The unilateral collar operation has the inestimable advantage of allowing removal of the second side at any subsequent period since it will have been practically untouched at the first sitting, giving at the same time the complete cosmetic collar incision.

The advantages of taking a second lobe through the second half of a collar incision by retracting the sternomastoid and splitting the ribbon muscles instead of through half a complete collar incision previously made are manifold, viz., (1) no more general anesthetic is needed than for handling skin flaps previously cut; (2) identification of undisturbed tissues is, of course, much simpler than where an old wound is invaded; (3) one is not confronted by edema infiltration and shortening of the muscle covering of the gland; (4) the second field is practically a clean one, at least so far as the depth of it is concerned; (5) the medium muscle body formed by the ribbon muscles remains undisturbed in its relation to the trachea, at the same time preserving the contour of the neck as seen in the lateral view.

**Objections.**—There is, I suppose, no procedure in surgery which is not open to some theoretical objections; however, so much more can be said for than against a unilateral resection in the very doubtful risk patient that there is to my mind no choice when confronted by such an individual.

The lobe of a toxic goiter which is left after the removal of a first half may, as many surgeons claim, produce an immediate postoperative flare-up; if this were important, the later removal of this second lobe would become insignificant as compared with the first step, something that has not been observed in my own experience at least. It may be said again in passing that the second lobe is not exposed or in any way disturbed when the first is removed in the way we advise, which may account for the rather mild but similar upsets following the two

procedures. We take both lobes at one sitting in many mildly toxic cases, but feel that we reach an entirely different class of invalids with our unilateral technic; one in which it would seem in the light of experience highly dangerous to double the gravity of the operative endeavor.

There are undoubted minor drawbacks to any form of two-step resection, although some patients remain unimpressed by them to the extent of referring other sufferers to us with the request that the apparently safe two-stage operation be done.

As to surgical cleanliness, it must be admitted that the small unilateral wound packed wide open, and closed in a day or two becomes mildly infected in many instances. This complication naturally causes a lengthening of the interval which must elapse before the patient's general condition permits the second lobe to come out.

In a few cases the postoperative recovery has been so slow (pneumonia in one or two instances) that it has seemed best to send the patient home to recuperate for sixty to ninety days, entailing thus a very unwelcome second hospital visit. Let it be understood in this connection that the second lobe must as a general rule come out, and the chance of a patient deciding not to come back while feeling well, is a matter of extreme importance. As remarked elsewhere, those thyroid patients who have had one lobe out, then improved and broken down a second time, form an almost unmanageable group. A considerable number of them have been inherited from most capable surgeons who have for one reason or another failed to get the second lobe; not one of them lived to experience a second lobectomy.

The scar is somewhat longer after two half collar incisions than after one complete collar opening. It is not often the fine hairline scar which characterizes an "ideal" procedure, still it can always be excised if not satisfactory. However, this has not been suggested by any of our patients, though sometimes considered by us.

## References

[1]Lahey, Frank H.: Multiple Stage Measures in the Surgery of Severe Hyperthyroidism, Jour. Am. Med. Assn., June 17, 1922, lxxviii, 1862.

[2]Crile, Geo. W., and Lower, William E.: Special Points in the Technic of Operations on the Thyroid Gland, Ann. Surg., January, 1922, lxxv, 47.

## CHAPTER XVI

## SIMPLIFIED UNILATERAL RESECTION TECHNIC

The customary bilateral resection which presupposes an approach to the thyroid through a symmetrical collar incision of the skin and platysma followed by midline division (rarely cross-cutting) of the ribbon muscles, is based upon *anatomic* grounds. It has up to the present time been employed wherever a thyroidectomy seemed indicated, and has fulfilled all the requirements of patients carefully chosen, with an assured margin of safety. Many operative experiences in recent years have shown me, however, that the indications for thyroidectomy may be very considerably broadened by the employment of a technic which is based upon *pathologic* principles and calculated to make the minimum demand upon the patient's strength. To this end one waives every consideration of a cosmetic nature (although it may be stated here that the visual end-result is not always so bad as to greatly disappoint the patient, especially if the patient be a man who wears a collar of ordinary height) the sole aim here being to destroy the greatest possible amount of thyroid tissue; this could not be accomplished without risk to life if done in the usual manner. It is the very simplest, easiest route to the thyroid, and has a special value in men, because when they are depleted, they do not recover so quickly or so completely as women do. They are not easily disciplined, not accustomed to restraint, not unselfish enough to accept the situation and devote all of their energies to recovery.

In the past the great danger of thyroidectomy for toxic patients has consisted in our doing too much and thus bringing about a fatal postoperative explosion. We have, in consequence, gradually been driven to primary ligation for most of the serious exophthalmic cases. May it not in some of them be in order to attempt primarily a form of thyroidectomy, the gravity of which has been reduced to something like that of ligation?

This emergency technic may also be especially suited to the doubtful patients who seem so little improved after ligation

that no positive guarantee of safety can be given in case a classical thyroidectomy is done. No less an authority than C. H. Mayo says that ligation is of value only in the exophthalmic hyperplasia type with demonstrable vascular disease, hence the *toxic adenomata* indicate a thyroidectomy only, if operated upon at all. In many of these patients the results following the use of our emergency method have been most gratifying. In short we contemplate here no doubt the type patient generally speaking of whom Crile and Lower[1] feel that "if there is any doubt of the outcome at any point, that is the moment to stop the operation, tie off the ligatures and dress the open wound with flavine. Whether mistaken or not, the operation can usually be resumed and completed on the following morning."

As soon as the doubtful patient has reached the maximum of improvement and becomes sufficiently well acquainted with the surgeon to exhibit any degree of confidence in him, one feels that the time for action has arrived, although the sufferer be not apprised of that fact; and indeed we cannot always decide what technical procedure to follow in doubtful cases until the patient is on the operating bed, sometimes not until we see the effect of the anesthetic.

An emergency unilateral operation is always to be done in the patient's room, and conversely, if a patient is sick enough for "bed" operation, the simplest measures compatible with age and sex should always be employed. There is no mistaking the fact that doubtful patients operated in bed suffer very decidedly less reaction than those taken to the operating room. One may still expect a greater number of deaths among the latter class even though the very worst patients all have the operation done in their beds.

As in Crile's practice, a light nitrous oxide or ethylene anesthesia is instituted before the head of the bed is elevated and the sleeping chamber is transformed very simply into an operating room. After the neck is cleansed and the patient is draped, the face is turned away from the operator, then the site of the intended incision is marked (Figs. 107, 108, and 109) just behind the anterior border of the sternomastoid, being careful not to run down to within one centimeter of the clavicle, else an ugly fixed scar will result.

A diamond-shaped area is infiltrated about the growth, through one needle puncture, one at the middle of the mark just mentioned (Fig. 110). It suffices to infiltrate the subcutaneous fat and the muscle planes with ½ per cent novocaine. As such a patient must under no circumstances have the operation prolonged, it is well not to wait for a nerve block, but infiltrate the skin where marked and proceed with the operation just as quickly as possible after the patient is placed in position.

Fig. 107.—Line $x$—$x$ indicates the approximate location of the skin incision and its relationship to the anterior border of the sternomastoid muscle.

This form of incision (Fig. 111) has a number of advantages. It allows one to approach the tumor by the most direct route; it encounters vastly fewer vessels than does the "collar incision"; it avoids the extensive separation of tissue planes as contemplated in making the Kocher flaps; it is in a line with the axes of the important deep structures; it obviates retraction to a very considerable extent, and insures that the resulting scar will lie upon a preformed prominent ridge; viz., the sternomastoid muscle.



Fig. 108.—The two dotted lines on the woman's neck indicate approximately the relationship of the two incisions and resulting skin scars.

Fig. 109.—Intended muscle incision line and its relationship to the external jugular vein, spinal accessory nerve, and other important structures in the vicinity.

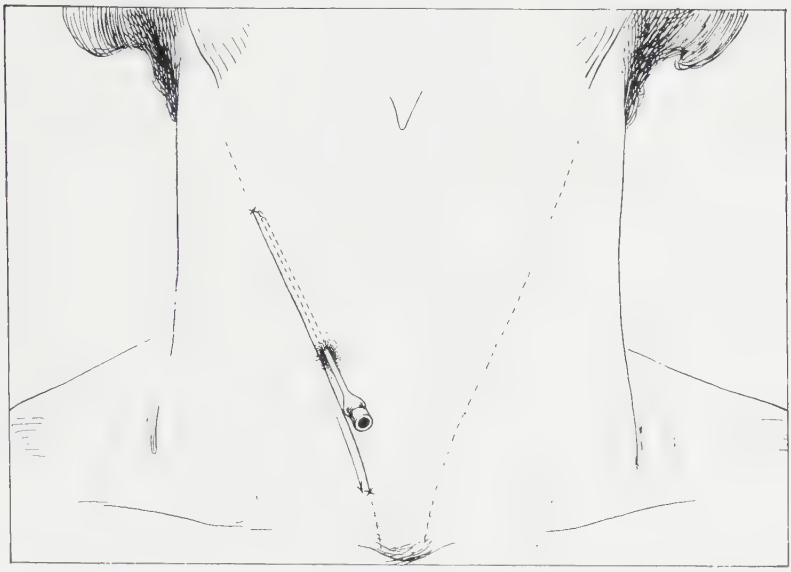

Fig. 110.—Shows how the plane of incision through the skin and deeper structures is infiltrated through a single opening.

Fig. 111.—The skin and fat incision has been made.

The platysma incision corresponds to that in the skin, this unimportant muscle being the only one the fibers of which are divided in any but a line parallel to them. After gentle

retraction of the lower sternomastoid outward (Fig. 112), and of the opposite upper wound lip inward, the ribbon muscles are split longitudinally or the original incision line may be carried down directly through everything (Fig. 113) covering the most prominent portion of the growth below. It will usually be found that the upper pole and superior thyroid vessels lie

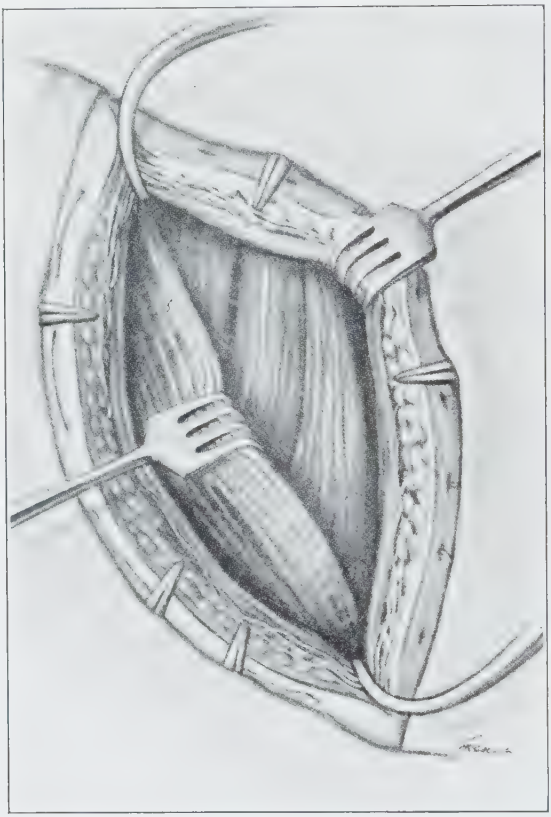

Fig. 112.—The sternomastoid muscle is retracted backward, together with the overlying structures, while the divided platysma and cervical fascia are drawn toward the midline.

directly under the upper angle formed in the divided ribbon muscles, thus greatly facilitating the further progress of the operation. It will be noticed just here that the gentlest possible retraction gives all the room for approach that is needed, quite contrary to the experience which all of us have had when operating through a midline ribbon muscle incision.

The exposed lobe is now caught with two or three light cat-claw clamps and gently lifted. At this point the whole defect is flooded with alcohol to seal up all tissue spaces against absorption of toxic material to be liberated in amputating a moment later. As a further guard against this accident, I often

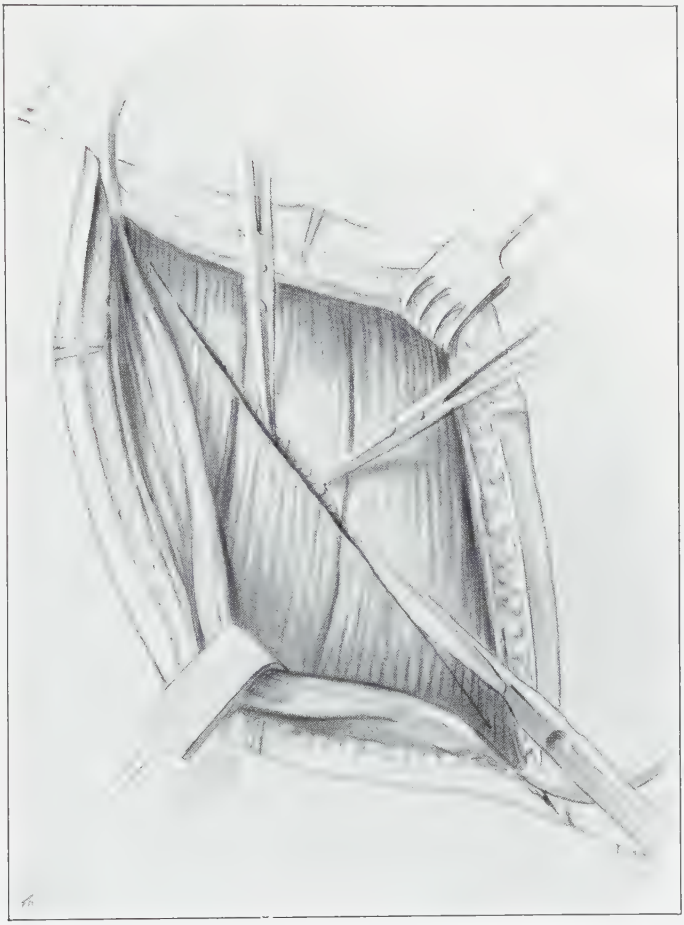

Fig. 113.—The ribbon muscles are incised diagonally in approximately the same incision plane as indicated in all of the figures from Fig. 107 to this number.

pack the furrow around the gland with a roll of dental cotton, provided there is room enough, which is by no means always the case.

The upper pole is now divided and the lobe gently drawn toward the angle of the jaw, while a rubber band is in most in-

stances thrown about the pedicle as described in extreme detail in the special chapter devoted to treatment of the stump.

Nothing works in such a case more satisfactorily and more expeditiously than a rubber strangling ligature about the stem of a lobe, which is tightened automatically as the lobe is cut from the stump of "conical" form. This can be used on a globular lobe which has a perfectly isolated, relatively slender stem *after the superior pole has been divided.* The "stunt" has the great drawback that it can easily mislead a careless operator into leaving too much gland substance behind. Such a ligature (safety) must be passed behind clamps grasping gland substance at several points, else it will slip off after amputation. The field is thus kept very dry and the procedure is materially shortened.

When the lobe is out the operation is practically over since one has only to lift up the handles of the clamps, bring them together over a pad of gauze thrust between their points, left attached where originally caught on thyroid tissue, and encircle them with a tape, the thin rubber ligature meantime approximating their points and causing hemostasis in the cut surface.

In a few cases not found suited to the constriction technic, the capsule and goiter substance are divided after clamping the upper pole from above downward. In this way it becomes surprisingly easy to gently slip out the lobe with the minimum of work about the lower pole, and without roughly luxating the gland with the finger, provided there be no outspoken perithyroiditis. By working in this way, the procedure is rendered practically bloodless and the patient is disturbed very little, if at all.

None of the clamps on thyroid substance are replaced by ligatures in order to reduce tissue necrosis to the minimum. No attempt is made to whip over the cut thyroid surface, fearing retention of toxic products and consequent symptoms. In other words, *all of the clamps are left on the stump,* although in most instances I have ligated the few which were required to control bleeding from the other subcutaneous structures, as well as those holding the superior thyroid. In one instance a total of fourteen clamps were left in place, in another twenty-six,

in another thirty-four, and in one other still a larger number, of which no count was made. The instruments I employ are the lightest which are adequate; viz., the clamps designed by Halsted, and used so commonly in the surgical clinic at the Johns Hopkins Hospital.

Shortening of the operation is a fortunate circumstance when it is recalled that the resistance of some toxic patients under local or gas anesthesia is about gone when this stage of the thyroidectomy has been reached. This practical observation tends to discount the fact that it is *theoretically* far from ideal to leave a large number of clamps in any surgical wound. One who entertains the idea for the first time might be justified in thinking of shock, postoperative discomfort, possibility of infection and cosmetic deficiency; in practice, however, the procedure has not worked out thus. In some instances the resection is much better borne than was anticipated in the beginning, and one is justified in going further and ligating in the ordinary manner, then packing the defect with gauze, or with soft rubber, which we consider better. However, the gain is very slight, excepting in so far as surgical traditions are concerned.

The instruments are bunched together (Fig. 114) by a mass of dressing wrapped about them in such a way as to bring pressure to bear upon the skin of the neck (Fig. 115), and upon their handles thus tending to lift their weight upward instead of allowing them to rest upon the floor of the defect. The whole bundle is now covered with cotton and a bandage is applied around the neck and the arms.

It goes without saying that a wound held open in this manner cannot possibly retain the fluids forming in it, hence the most complete drainage is secured. The individuals who have been operated upon in this way have complained of sore throat in just about the measure one sees it in other forms of lobe resection. I will say that they universally have difficulty in swallowing and experience a sense of weight or pressure until the moment when the clamps are released, then they are at once freed from this minor (?) discomfort. It will be recollected, however, that many an individual whose neck has been sewn

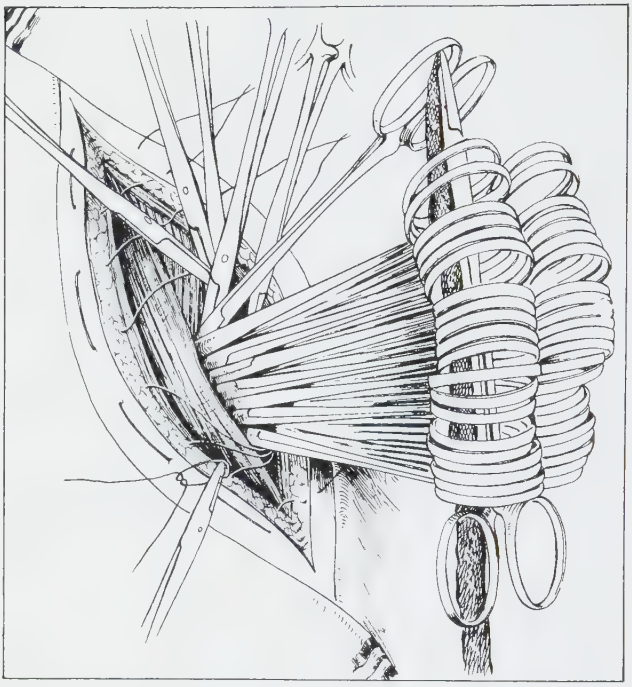

Fig. 114.—Clamps are left in place on the superior thyroid and stump.

Fig. 115.—The clamps are wrapped with dressings.

up in the ordinary way swallows with difficulty for a day or two and is far from happy. (See chapter on Complications.)

Postoperative bleeding and pain have resulted from the removal of gauze which in some of the earlier instances was packed tightly in the spaces left between and around the clamps; it is therefore deemed inadvisable to use much packing where the clamps are left in place unless it is needed for hemostasis. The original dressing should not be touched until the postoperative storm, if there be one, is over, and there is no reason to disturb the clamps before twenty-four hours, when, if the patient is quiet, it is my custom to unlock them if not on superior or inferior thyroid arteries and let them fall off in the next few hours by virtue of their own weight. This causes little discomfort provided it be done with the utmost gentleness. The wound is usually found full of serum when the clamps are removed; but it is expelled by tissue shrinkage, which follows the removal of the instruments, and the defect is automatically obliterated because the longitudinal slit in the ribbon muscles tends to close spontaneously as soon as their function is exerted. The sternomastoid muscle slips forward to cover the defect in them; the thin platysma defect can be disregarded, while the skin is closed by clips well enough the next day for all practical purposes over a rubber tube which emerges at the lower angle of the wound. Some little discomfort always attends this act, which is distinctly lessened by local infiltration anesthesia or a whiff of gas (better). One is surprised at the expiration of forty-eight hours to see how little need there is for any form of skin closure. The application of adhesive plaster would answer all requirements were it not for the tendency that the lips of such a skin wound have to roll inward.

This may, then, for want of a better expression, be termed an *emergency technic*. (1) It contemplates the most direct, rapid and bloodless approach to the tumor; (2) it prevents the tissues from being contaminated by toxic thyroid juices; (3) it saves the time ordinarily spent in ligating vessels and in closing the wounds; (4) it eliminates the accidents which not infrequently cause loss of blood while the operator is ligating the numerous vessels divided. It then quite naturally follows that shock is rendered unlikely, because the efferent nerves are

blocked, the operation is short, and very little retraction is necessary. Likewise postoperative hyperthyroidism is not to be expected because absorption cannot take place, the wound being left wide open. (Absorption is, of course, but a partial explanation of postoperative hyperthyroidism.) However, this phase of the subject cannot lightly be dismissed by one who has seen postoperative temperature invariably drop where fluid was found secondarily in cases characterized as yet by no change in the central nervous system. I can state now, after wide experience with this technic, that one feels justified in thus resecting one lobe on a considerable percentage of patients who were formerly not thought able to bear the operation as done in the commonly accepted manner.

A few days after removing the left lobe, I remove the right on most patients. The first side is thus never disturbed, nor is the second operation different in any way from one in which the first side had not been opened. There is a decided economic, as well as psychic, value in removing the second lobe during the same hospital stay. Only partial recovery is ever possible until the whole gland is removed, and the psychic effect of a repetition of the whole operation several months later is certainly not conducive to the best recovery in highly excitable and nervous individuals. The value of getting out the second lobe while the patient is in the hospital is shown in the case of Mrs. K. (June, 1920). The second lobe was obstructing the neck opening into the chest and no doubt was chiefly responsible for the symptoms, though it had been considered the less important of the two at the original examination. Individual judgment must be used, however, in deciding whether it is wiser to remove the second lobe at the original hospital stay. When a patient does not convalesce promptly from the first operation, a thirty to ninety day respite may be allowed between the two lobectomies, and the patient then be so well at the second sitting that primary skin suture can be made, also the first depressed skin scar be excised if desired.

## Reference

[1]Crile, Geo. W., and Lower, William E.: Special Points in the Technic of Operations on the Thyroid Gland, Ann. Surg., January, 1922, lxxv, 47.

## CHAPTER XVII

## COMPLICATIONS

One is surprised in perusing the literature of this subject to read that complications following thyroidectomy as done by the practiced operator of today are probably less numerous and less serious than those likely to follow any other of the major operations. There are indeed many complications that are peculiar to goiter surgery with which the operator should be thoroughly familiar. To aid in their prevention as well as remedy when they do occur, I shall discuss those with which I have had experience, as well as a few others with which recent writers have dealt.

### Acute Anemia from Hemorrhage on Table

The most distressing condition, next to suffocation, that can complicate a thyroid operation is anemia produced by hemorrhage on the table. Fortunately it is very rare in the hands of experienced operators because of well-trained teams and the use of innumerable hemostats. It is most likely to occur in operations done for recurrence, where there are dense adhesions to all surrounding structures. An enormous vein, and sometimes an artery, is drawn up attached to the surface of the tumor being exposed; the vessel is flattened and completely emptied, and before it is recognized, is cut or torn by mistake. It retracts so deeply into the large wound that it can scarcely be caught at all, especially if the defect has rapidly filled with blood. In one extreme instance in partially substernal goiter, I had to leave three clamps in place, pack an enormous defect with gauze, interrupt a half completed operation, and put the patient to bed because the blood pressure dropped to 80/60 on the table. This certainly illustrates the value of repeated blood pressure readings in all critical surgical operations. It likewise gives warning of impending death at a very early period, while the pulse is still of nearly normal rate and of fair volume. The

treatment cannot be better outlined than by describing in detail what was done in this instance.

The foot of the bed was raised to increase the amount of blood in the brain and in the heart itself. The patient was kept deeply under morphine while 1,500 c.c. of salt solution was run under the skin in two streams, and 1,000 c.c. of 5 per cent glucose solution was allowed to trickle into the rectum. About 300 c.c. of 10 per cent glucose solution was injected into a vein while preparing to do a blood transfusion, and within an hour after she left the operating table, 500 c.c. of blood had been introduced into another vein. By this time the blood pressure was 98/65, the lips had regained their normal color and we no longer had reason to fear the patient's immediate demise. She received an enormous quantity of fluid in a comparatively short time, during which period the heart was carefully observed for acute dilatation and the lungs for acute edema. As soon as she awoke, she was given all the hot tea and coffee that she cared to sip from time to time. There is absolutely no use to temporize with drugs of any kind with the exception of morphine, the treatment being to restore the volume of fluid lost, a very definite portion of which must be blood if the vital functions of the organs are to go on. Morphine merely keeps the patient from whipping out the heart, and by exercise increasing the need for oxygen at a time when red cells and hemoglobin are lacking.

### Surgical Rotation of the Trachea

Surgical rotation of the trachea is mentioned by Pemberton[1] as a rare complication, and is, of course, noticed in any instance in which an enormous distorted adenoma to one side of it or behind it has been removed, allowing this viscus to assume its normal position or indeed to swing past the midline.

### Collapse of the Trachea

Collapse of the trachea, except when it results from the rapid formation of a hematoma, is probably an extremely rare complication after operations for the removal of thyroid tissue. Laryngologists familiar with this kind of work now feel that many cases of suffocation attributed in early times to this source were in reality produced by paralysis of the abductor mechanism

of the larynx due to operative injury of the laryngeal motor nerves. The urgent symptoms in the two instances are not at all dissimilar, although the method of affording relief in the one instance bears no resemblance at all to that in the other. An immediate tracheotomy must be done for double abductor paralysis, while collapse of the trachea the result of hematoma is naturally immediately relieved by the evacuation of the disturbing blood. Three hours after a double lobectomy, Mrs. D. had a sudden hemorrhage which filled a large defect, causing compression of the trachea and apparent suffocation. The trachea must have been soft, as she could not tolerate constriction. Upon removal of the sutures and release of the accumulated blood, she was immediately relieved.

## Shock

When we consider the means at our disposal for the prevention of shock, there is little excuse for its occurrence in goiter surgery, and in fact, very few cases are being experienced. The surgeon must study his patient before he elects to do a thyroidectomy, and build up through palliative measures the patient too weakened to withstand surgical interference. Most goiter patients if properly prepared through rest, diet, etc., will recover promptly without any signs of shock. The patient is directly protected against shock through the use of local anesthesia. Infiltration takes care of the nerves from the point of injection to the brain centers by blocking the pathways over which influences ascend to the brain, thus eliminating shock physically, while the *dream state* produced by luminal and morphine as preliminary drugs and nitrous oxide on the operating table, takes care of psychic shock. Much depends upon the rapidity and gentleness of the operator and upon good teamwork during the operation. Of advantage in goiter surgery is the fact that the operator may stop at any stage of the operation when early signs of shock appear, allow all clamps to remain in position, pack the wound and get the patient into bed and institute measures for relief, such as administration of fluids, blood transfusion, etc.

Rare as it is in thyroid surgery to observe shock pure and simple, I do make an exception of intrathoracic goiter where one may come in contact with vital structures. I remember quite

well one case in which the systolic pressure dropped from 120 to 76 suddenly as a result of forcibly tearing an enormous adherent adenoma away from the region so deeply seated that the pericardium cannot have been far away. The amount of shock in such a case is surely always proportionate to the degree of force employed.

### Postoperative Hemorrhage

Postoperative hemorrhage may occur at any period during the first twenty-four hours following operation, under the influence of coughing, vomiting, or straining of any kind, and is more likely to follow operation for highly vascular goiters in which many large, thin-walled, friable vessels have been encountered. Its likelihood is prevented by allowing the patient to partially awaken just before finishing the operation and asking her to cough or strain, so that in this way one may not overlook a point which is left open and likely to bleed later. In one of our cases it was necessary to remove all sutures eighteen hours after operation for bleeding between the layers with choking. Clots were turned out, the wound packed with gauze, and closure made forty hours later.

An accumulation of dark fluid blood may take place so slowly that several days after operation the neck may look just as it did before anything was removed because the defect left after removal of the goiter tissue is again filled out. Such a case is admirably treated by aspiration through a heavy needle inserted through the suture line without disturbing it. The urgent symptoms are immediately relieved; however, the procedure must usually be repeated.

Hemorrhage has occurred in a few infected wounds several days after the operation. In one or two instances it has been rather alarming, though always easily controlled by a tightly bandaged dressing. In no instance has it recurred after the prompt institution of Dakin treatment.

### Postoperative Hyperthyroidism

The patient rarely ever recovers from postoperative hyperthyroidism after the typical symptoms are apparent. It must be prevented because it cannot often be cured. It is obvious

that irreparable damage to the central nervous system has taken place by the symptoms shown—temperature rising rapidly, sometimes to unbelievable heights, patient becoming restless beyond any possibility of control, rapidity of respiration and pulse beat, phonation becoming more and more difficult as speech center becomes affected, until at the expiration of twenty-four to thirty-six hours the patient succumbs.

Postoperative hyperthyroidism has almost been eliminated in three ways, first by the postponement of the operation until the patient (exophthalmic type) has so nearly reached an intermission in the disease that the metabolic rate is no longer high; second, by the use of Lugol's solution in an acute phase of the disease to the point that the rate is very markedly reduced; and third, by leaving the wound wide open in thyrotoxic individuals, packing it with gauze or rubber in some such way as to assure free drainage.

Evidences of acute thyrotoxicosis in Mrs. P. in spite of local anesthesia and open wound were mumbling speech, respiratory difficulty, unconsciousness, with anesthesia of cornea, rapid pulse, fall of blood pressure, especially diastolic, extreme restlessness when she roused up at all, also involuntary bowel movement and urination.

This complication may come on unexpectedly and insidiously. Mrs. G. (early in May, 1922) had a toxic adenoma with leading symptoms of a psychic nature, a blood pressure averaging 180/80 and a metabolic rate of +7. She so misled us on the table that we made a complete closure. Thirty-six hours later she was in a disturbed psychic state with blood pressure 200/60, the diastolic tending to shade toward 0. We removed every stitch, packed the neck with glycerin gauze, and in an hour the systolic pressure was 190. By the following morning the reading was 160/80. She continued to improve from that time.

### Difficulty of Swallowing

A large amount of mucus in the pharynx with inability to swallow or talk has always been associated with luxation of goiter by the finger. Various other causes of difficulty of swallowing are treated under more specific headings.

### Edema and Paralysis of the Larynx

Strangling on the attempt to swallow fluids occasionally is experienced for some hours after thyroidectomy. This seems to be caused by a temporary injury to the superior laryngeal nerve (infiltration, pressure, edema, etc.) followed by abolition of the usual sensory stimuli which result in automatic closure of the epiglottis. In consequence some fluid finds its way into this highly sensitive structure with immediate spasm of coughing, great general agitation and even damage to more remote respiratory areas.

Inability to swallow without coughing and strangling was present for a limited time after Miss L.'s (August, 1924) unilateral resection, due, no doubt, to this temporary impairment of the nerve supply to the epiglottis. We introduced the small nasal tube into the esophagus to a point somewhat below the level of the cricoid cartilage, then poured nearly a quart of fluid into the stomach every six hours without disturbing the patient in the least. The value of this procedure becomes apparent when one considers the dangers to a badly damaged goiter heart of a prolonged attack of coughing and strangling. A more remote consideration is the risk of bronchitis and even of bronchopneumonia in consequence of prolonged exposure of the lower respiratory tract to foreign body irritation.

Graham[2] relates an interesting case sent to his clinic four weeks after thyroidectomy in which both recurrent nerves had been cut, the patient's condition bordering on suffocation. One of my own cases had so much edema of the glottis that twenty-four hours after operation I had to do a high tracheotomy for obstruction, after which improvement was rapid. There had been deformity of the trachea with an accumulation of much mucus before operation.

### Retention Fever

Retention of fluid in a thyroidectomy wound, no matter what the type of patient, means a sore neck and a toxic state. This has been proved often in our clinic by the immediate relief of both of these conditions experienced as soon as such a neck is reopened.

## Tetany

In the very early days of thyroidectomy Billroth, who attempted a complete operation in his series of more than eighty patients, saw an exceedingly high incidence of tetany. At that time, the anatomy of the parathyroids, and to a less extent their function, was little understood; it stands to reason, therefore, that a total thyroidectomy should in very many instances have resulted as above stated. Tetany is very rarely seen at the present time, since all experienced operators protect the trachea, recurrent nerves, and parathyroid glands by leaving a certain amount of gland structure in front of the posterior capsule, in this way being very certain that this portion of the capsule is never damaged or the three important structures behind it disturbed.

I have seen several light transient cases of tetany, but only one uncontrollable, fatal case. Miss R. (April, 1924) returned to the hospital four weeks after thyroidectomy with pus collection where the lobes had been. The same night she had a violent epileptiform attack. Their frequent recurrence led to a diagnosis of tetany. The patient gradually grew worse in spite of all treatment, and died in a violent attack five weeks after readmission. This case was the result of destruction of the parathyroids by an inflammatory process.

Miss S. presented every symptom of mild tetany twenty-four hours after operation. Calcium therapy, parathyroid feeding, and sedatives were ordered. An assistant cut the bandage when the patient complained that it was too tight, whereupon the tetanic symptoms disappeared immediately before orders for medicine had been carried out. In this instance pressure no doubt interfered with the blood supply to the parathyroids. In another case pressure was caused by gradual increase of blood in the wound, forming a hematoma by the third day. Immediate and permanent relief was obtained by release of the fluid.

The following comment on the treatment of tetany is quoted from an article by Crile.[3]

"During the past six weeks we have been using the hormone discovered by Dr. J. B. Collip of Alberta University and have secured as definite results as he secured with his experimental

animals in both acute and chronic cases of tetany. Five acute cases have been treated with relief in every case. Relief of symptoms is usually experienced within twenty minutes to one-half hour after the intravenous injection of 1 c.c. of the hormone. In one exceedingly acute case, in which not a single one of the classical symptoms of tetany was lacking, the first dose was followed within twenty minutes by a disappearance of the subjective symptoms. Three doses of 2 c.c. each resulted in complete recovery. Among the chronic cases treated relief has been secured in about 85 to 90 per cent. In the cases in which Collip's hormone is not used the following measures are employed: Two grains of thyroid extract are given twice a day, ⅕ of a grain of parathyroid extract three times a day and 20 grains of calcium lactate every four hours. Five cubic centimeters of a 10 per cent solution of calcium chloride is given intravenously once a day for three days. If at the end of this period analysis of the blood shows a normal calcium content this medication is discontinued. If the blood calcium is below the normal, then the medication is continued. If the patient has tingling of the fingers, the dose of calcium lactate is increased to 40 grains. If the symptoms become alarming to the patient, ⅕ of a grain of morphine is given hypodermically and 20 c.c. of a 25 per cent sterile solution of magnesium sulphate subcutaneously. With the latter dose particular pains are taken to spread the injection by using a long hypodermic needle and applying a hot water bottle over the site of the injection. It is a good precaution, to avoid any possibility that any of the solution may enter the veins, to inject the magnesium sulphate into the subcutaneous fat of the abdominal wall rather than into the muscle. This dose is repeated every five or six hours for three or four days, the calcium lactate and thyroid extract being continued for three or four days longer, after which the dose of these substances should be gradually decreased. Of course it is unnecessary to emphasize the necessity for watching the patient carefully for symptoms of magnesium sulphate poisoning."

Miss B. (October 18, 1919) after bilateral resection for simple goiter, showed mild symptoms of tetany on the third day, which increased coincident with growing hoarseness. The posterior capsule had been left liberally covered with thyroid

tissue, so that there was no possibility of operative injury to the parathyroids. We inferred that edema incident to the healing process compromised both the recurrent nerves and the parathyroids. She was never very sick, therefore we contented ourselves with calcium therapy alone. She began to improve two weeks after operation and during succeeding weeks her attacks became less frequent and less severe, until they gradually ceased altogether about the time one would expect repair of the neck tissues to have been completed. When seen eleven months after operation, she had had no calcium for several months, during which period she had remained completely well.

Typical parathyroid tetany was seen in the case of Miss D., (May, 1924) three days after operation. All dressings were off; there was primary union with no external evidence of fluid accumulation in the wound and surely the posterior capsule had been respected during the bilateral resection to the extent of making a direct injury to, or removal of, the parathyroids most unlikely. Administration of calcium lactate gr. x every two hours while the patient was awake exerted no influence during three days, but the spasms promptly and permanently ceased when morphine gr. ¼ and atropine gr. $\frac{1}{150}$ were given every six hours.

### Pulmonary Complications

One of the most frequent lung complications after thyroidectomy is surely bronchopneumonia, which is often very difficult of recognition but fortunately of short duration. This is easily understood when one realizes that handling the trachea and traumatism, however slight, of the nervous and motor mechanism of the larynx interfere some with the automatic protection of that viscus afforded by the epiglottis, hence increase the likelihood of laryngitis, bronchitis, tracheitis, and bronchial pneumonia.

Mr. H. (September, 1924) afforded a good example of the occurrence of this complication. A few days after this operation, although his neck wound looked perfectly clean, his temperature rose to 104°, he had a chill, and was distinctly sick, but gave no clinical diagnostic signs excepting a slight rough breath sound over the lower left lung. Radiograms taken at the time seemed to substantiate a suspicion of broncho-

pneumonia. Fortunately, he made a very satisfactory and sudden, spontaneous recovery. I am sure that many of the unexplained febrile complications, in the absence of wound infection, which complicate thyroidectomy, are due to a mild pneumonia. At least, it should always be looked for when the illness cannot be explained in any other way.

There must be no thyroid operation while hypersecretion remains in the larynx or trachea after acute infection of them. Miss U. (January, 1922) had a moderate amount of mucus before lobectomy. The mere manipulation of these viscera under gas and infiltration caused an unbelievable increase in the amount of mucus at once. There was an outspoken bronchitis in a few hours which developed into bronchopneumonia twenty-four hours later with death in forty-eight hours. This was a toxic patient who had never made a satisfactory recovery from ligation, with whom less than the usual risk was permissible.

### Pulmonary Embolism

Pulmonary embolism so far as I have observed, seems to be a very rare complication of thyroid surgery. This is rather contrary to what one might expect, however, since we often deal with enormous, tortuous veins, such as those which in other parts of the body, particularly the female pelvis, are prone to become thrombosed and produce this complication after operations. Dr. Ralph Thompson and I[4] in a paper in 1908 reported 22 cases; still not one of these had been operated upon for goiter.

Recently, though (May 26, 1925) such an accident occurred in our clinic. An elderly lady presented herself with an enormous, partly intrathoracic adenoma, having most unusually dilated tortuous veins covering the chest wall. Fortunately the possibility of this complication was stressed when she was first examined, whereby the disappointment of all concerned was appreciably lessened when the typical symptoms of it actually occurred, followed by death in a few hours.

### Hematoma

Faulty hemostasis on the operating table is very likely to mean a hematoma in the space from which the thyroid has been removed. This has occurred in my own experience just as fre-

quently where a drain tube was left in place, as after complete wound suture, proving that a wound must be packed wide open if there is any reason to suspect postoperative bleeding, as this alone will prevent the formation of a hematoma. This complication is always undesirable and at times very dangerous. Such a blood collection is practically certain to give rise to resorption fever, is prone to secondary infection, and has led in more than one instance to a compression of the trachea so pronounced as to end in death. In preceding sections several cases of hematoma which led to more serious complications have been mentioned.

### Infection

In this day of rigid aseptic technic wound infection is unlikely to occur; however, goiter wounds are much more likely to become infected than other wounds. Infection should never occur in a goiter wound completely closed without drainage as so many are in nontoxic patients. But there is danger of slight infection when large wounds are packed wide open to avoid postoperative explosions in already toxic individuals. It is theoretically and practically unavoidable in wounds kept open as long as some of these are, twenty-four to forty-eight hours. Rarely, however, in such cases do we see clinical evidences of a general nature such as usually attend wound infection. The most serious feature of them is usually somewhat prolonged drainage with a scar that leaves something to be desired in consequence. In a few instances, there have been the perfectly typical chill, fever, and other well-known evidences of suppuration which have necessitated counter-openings through the lateral aspect of the neck and the insertion of drains at the most dependent portion of cavities, particularly of large ones.

Infection following temporary open treatment of a thyroidectomy wound seems less likely to develop into a real complication after rubber than after gauze packing has been employed. Dakin treatment has been most effective in causing the early expulsion of the tissue shreds which by their necrosis keep up a discharge. The wound is irrigated twice a day with it.

An illustration of the difficulty of determining wound infection is shown by the case of Mrs. K. (April, 1924). A large adenomatous thyroid had been removed three days previously,

the wound being drained with rubber tubes, when her temperature went to 103°, the white count to 30,800, with all the symptoms in keeping. No physical justification could be found in the wound, the respiratory tract, the endocardium, kidneys, etc. After a saline cathartic with bowel movement, the white blood count was 16,000 within twenty-four hours, following which the patient made a rapid recovery, no explanation for her upset ever developing. This case is cited to show how useless, as well as undesirable, would have been any extensive opening up of the neck wound, the operator's first temptation in every such case.

### Referred Pain

Pain in the shoulder region, arm, hand, and fingers of the operated side, as well as that so frequently seen in the upper neck, teeth, and ear, appeared coincident with the accumulation of a large amount of seropurulent material in Miss F.'s large right lobe defect, which was tightly closed after having been packed open for two days following unilateral resection. This continued unabated as long as drainage was insufficient, then the symptoms disappeared like magic as soon as the cavity was widely opened and packed with gauze. No doubt a certain degree of toxic neuritis affecting the whole upper extremity can be produced by an extensive inflammatory lesion not far distant from the large trunks which continue down into the brachial plexus.

### Complicating Acute Surgical Lesion

There is no reason why any one of the common acute surgical lesions which affect normal individuals should not also occasionally strike the patient who is still in the hospital after removal of goiter. Focal infection evidently plays a part in the production of many goiters, particularly those of the exophthalmic variety. This is equally or perhaps even more true of appendicitis, gallstone disease, pyloric ulcer, and other maladies too numerous to mention. When we take this into consideration, it is surprising that the incidence of a second acute surgical lesion is not more frequent during the convalescence of goiter patients than our records indicate it to be.

McCrae[5] reports a case of acute, gangrenous appendicitis,

which occurred in a patient about five weeks after thyroidectomy for exophthalmic goiter. About ten days after the patient had returned to her home after the thyroidectomy, she suffered with a sore throat, to which she paid little attention. Several days later, she was suddenly taken with a severe pain in the right lower abdomen, but she did not complain to her family about it for several days when it was aggravated by an automobile ride. The picture was that of acute appendicitis exaggerated by the thyroid. The blood count showed 33,400 white cells with 90 per cent polymorphonuclears. An emergency appendectomy was performed under gas and novocaine, from which the patient rallied, only to relapse into an extreme condition about twelve hours after operation. She died three hours later. Pathologic examination showed a gangrenous appendix perforated near the end, in which streptococcus was the predominating organism. McCrae does not feel that the patient was allowed to resume activities too soon following the thyroidectomy, but he does feel that she should have been given Lugol's solution during the period in which she was at home. He also feels that the neglect of the sore throat, most likely of streptococcal origin, as well as the neglect of the appendiceal condition for several days, played an important part in the outcome.

### Foreign Body in Wound

So long as we continue to use sponges, packs, and drains during the course of surgical operations and after-treatment, just so long will an occasional foreign body be left buried, and the attendant complications painful to patient and surgeon alike be experienced. With this in mind one should very promptly explore any persistent suppurative focus which does not show spontaneous tendency to complete obliteration within ten to fifteen days following thyroidectomy. As an example of the possibilities of this kind, I know of one instance in which a large gauze pad lay in the recesses of a larger goiter wound four weeks, during which time a persistent fistula should have warned those in attendance of its presence. I have been told by a brother surgeon in another city that he removed a neatly rolled rubber drain from a pocket in a young lady's neck at the expiration of five weeks after the skin wound had completely

healed over with late secondary spontaneous opening of the suture line.

A late neck phlegmon was seen in Miss D. (October 15, 1920) operated upon June 15, 1920. The condition came on suddenly with chill, fever, and sweating. When she was seen six hours later, the entire neck was enlarged, upper flap particularly edematous; there was slight embarrassment of swallowing and respiration, with limitation of motion. A laryngologist found no primary cause in the upper air passages, etc. A purulent discharge through the scar was followed by complete relief. X-ray showed no foreign body in the neck, nor was any found on forceps examination. However, on October 31, 1920, a gauze sponge was removed, four and one-half months after operation.

### Central Nervous System

Fry[6] feels that no particular psychosis is characteristic of any phase of thyroid disturbance. He says the type that is most often associated with thyroid operations is probably a mild manic depressive manifestation. We probably more often see a state of excitability postoperative than a depressive state; however, both conditions may occur. There is no way to determine the probable duration of either of these states following goiter or other kinds of operation, as we cannot check up these states by the somatic conditions of patients with any satisfaction. In this statement a distinction is made between mere delirium and a more fixed psychosis; usually this can be done in the individual case; however, it is better to take a few days in determining this point than to decide it too promptly. A psychosis is not *caused* by a goiter operation, but a previous fixed psychosis is simply brought out by it.

### Intracardiac Thrombosis and Embolism

One of the more remote and highly dangerous complications has to do with the dilated heart so frequently the result of neglected toxic adenoma of long standing. The following case reports will serve as examples of what may occur when mural thrombi form in the left ventricle of such an individual if particles become detached and are swept into and occlude the principal nutrient artery of some important division of the body.

Mrs. M., forty-eight years of age, the mother of four children, had had a goiter for fourteen years which had given no trouble until the year before she came to me. She had been extremely nervous, with marked shortness of breath even when resting, palpitation, and choking sensation. There was a full feeling in the neck, insomnia, loss of strength and weight, poor appetite, and she had headaches and nightsweats. Physical examination showed a greatly enlarged thyroid, the right lobe being especially involved and the trachea forced to the left. It represented the volume of the largest lemon, the left lobe apparently being two-thirds of this size. It was nodular and a diagnosis of toxic adenoma was made.

At the operation the thyroid was removed. It was retroclavicular on the left side and really consisted of three separate portions, a lateral and two median, each somewhat larger than the largest lemon and deforming the trachea into the characteristic "S" configuration. She went home, to return three months later with all the evidence of an acute exacerbation of chronic gallstone disease. She was deemed sufficiently recovered from her former operation to be subjected to what might well be termed a necessary, if not life-saving, procedure. Using spinal anesthesia, we removed an extremely long, thick, fibrous appendix completely hidden by a veil, then took out a gall bladder of large size which was completely adherent to surrounding viscera and which contained three immense nonfaceted stones.

She was considered a typically bad risk, the worst feature of her condition seeming to arise from the heart which was apparently the seat of a mild myocarditis when she came in for the first time. The operation seemed tolerably well borne, as far at least as the heart was concerned. Five days later, however, she was suddenly attacked with violent pain in both lower extremities. They became cold, pale, later mottled in appearance, and showed all of the characteristic phenomena of an interruption of arterial blood supply. Gangrene of both legs slowly developed to a point above the knees. At the expiration of two weeks she died.

The condition, as it happened, was correctly diagnosed during life, confirmation of which was shown by mural thrombi

in all the chambers of the dilated heart with embolism at the bifurcation of the abdominal aorta, completely shutting off both common iliacs. The compensatory anastomotic circulation through the vessels coming down superficially in front and behind had been sufficient to nourish the upper thighs with a limitation of gangrene as above stated.

Mrs. N. died one month after thyroidectomy for toxic adenoma from gangrene of one leg. She had been sent home from the hospital with a mild degree of cardiac decompensation and instructed to remain absolutely quiet for some time. Instead of so doing, she walked up and down a long flight of stairs in her home the day of her arrival there, whereupon one lower extremity suddenly became helpless, cold, and exceedingly painful. An osteopath was immediately summoned who vigorously massaged the offending member. Within a short time gangrene supervened to which she succumbed as might have been expected. While no autopsy was permitted, it is assured that a mural thrombus became detached from her left ventricle and plugged the femoral artery.

### Hypothyroidism and Myxedema

Many of our patients, especially those in middle life, gain astonishingly in weight after removal of the thyroid. Metabolic rate determination in many such individuals has shown them to have slight hypothyroidism, although far from presenting a complete pathologic picture of this malady in its tragic, extreme form.

It is unavoidable in more than a few instances, because we can in the individual patient never determine more than approximately just the amount of thyroid tissue to be removed since we have no means of judging accurately the functionability of the portion left behind, hence it comes about that at one time we leave too much and at another too little, even though the block may be just the same size in the two instances. The amount to be left behind and the conditions which influence our determination of it are very fully considered in connection with thyroid resection (pp. 195, 210). So it comes about that many of our patients in whom we have removed too much thyroid tissue for their own good develop a very mild type of hypo-

thyroidism which is pathologic for them only in so far as disproportionate gain in weight is concerned. It has in my experience been possible to make definite diagnosis of myxedema in only a very few such individuals, although one must admit the possibility of its occurrence following almost any bilateral resection. Reference to the chapter on the History of the Surgery of Goiter will show that this complication was extremely common to Professor Kocher in his pioneer work at Berne early in the last quarter of the nineteenth century, at the same time that tetany was occurring in the hands of Billroth. Both of these masters of the surgery of their times were performing what amounted to a total thyroidectomy, but it has never been satisfactorily explained just why one of them had a high incidence of tetany while the other scarcely ever saw it, but had an equally high incidence of thyroprivia. Fortunately this complication of mild hypothyroidism or even slight myxedema following resection means nothing very serious to us at the present time if detected reasonably early, since these patients can be perfectly controlled by the administration of thyroxin, which can be used very frequently without occasioning the typical toxic symptoms associated with excessive thyroid feeding. It must be noted, however, that the heart can be overstimulated by its use.

Miss G. (August, 1924) reported ten months after the completion of a four-step thyroidectomy for exophthalmic goiter, having almost doubled her weight in the meantime. We could not be sure of any myxedema, her intellect was bright and she made no complaint except of excessive gain in weight. Still, I felt called upon to suggest thyroxin and limitation of diet not only in the effort to prevent more gain, but to reduce her present weight. This case illustrates what can take place as a result of thyroidectomy in an individual with a metabolic rate so high and a toxic condition of such severity that she became a mere skeleton, lay unconscious for weeks and had to be fed through the nasal tube during this period.

Miss E. reported January, 1922, about a year after thyroidectomy for colloid goiter, complaining of weakness, melancholia, dry hair, and scaly skin. Thyroxin was given her in $\frac{1}{160}$ gr.

doses with slight improvement, but the picture was so complicated by overwork and worry that I am not able to give an accurate account of the results.

Frank H. Lahey,[7] reports a case of removal of a lingual goiter in a young woman of twenty-five years of age which was followed by persistent hypothyroidism. History of a tumor at the base of the tongue, gradually increasing in size, having a broad base and lobular of contour, firm of consistency, but freely movable, led to a diagnosis of lingual thyroid. In view of the fact that it had attained the size of an egg and seriously interfered with swallowing and nutrition, its removal was advised. The basal metabolic rate was +2 previous to operation. The tumor was removed from the tongue, after being delivered well out into the mouth through the aid of silk stitches inserted on either side of the tongue, by a wedge-shaped incision. Hemostasis was obtained through clamps applied previous to cutting. The wound was closed by bringing the mucous membrane of the tongue over the defect. Twelve days after the operation, from which the patient had recovered, her metabolic rate was –18. As a result of thyroid feeding over a period of two months her metabolic rate rose to +19, and some time after the cessation of thyroid feeding the metabolic rate again dropped to –15. Lahey feels that in this case the lingual thyroid "represented the entire undescended thyroid gland," in view of the persistent hypothyroidism. I had one such case, which, however, was followed by recurrence. I very much prefer to operate through the floor of the mouth. Dr. Blair states that hypothyroidism may almost always be expected after removal of lingual goiter as in this case.

G. R. Murray, of Manchester, England, was the first (1891), to employ thyroid extract successfully in the treatment of myxedema.[8] The patient, a woman of forty-six, began to suffer from myxedema at the age of forty-two. She presented quite typical features of four years' standing. Realizing the hopelessness of her condition, she agreed to undergo experimental treatment with thyroid extract. Extract of the thyroid gland of a freshly killed sheep was carefully prepared and administered hypodermically, 25 minims twice a week, the interval being increased later. Three months later, during which time the patient

had continued to improve, the injections were given at fortnightly intervals, and later when Fox and Mackenzie showed oral administration to be equally efficient, she was given 10 minims by mouth six nights a week, a dram being taken in one week. She continued to take the treatment and remained in good health and free from myxedema symptoms until she died at the age of seventy-four from cardiac failure.

In order to be well informed should a similar situation present itself, one may with profit read the following paragraphs which are quoted from an article by Reid Hunt[9] on "Pharmacology of the Thyroid Substance":

"Administered in repeated doses to normal animals or men, there is a latent period, then a tendency for a positive nitrogen balance to diminish and then to become negative; there is an increased excretion of water, chlorids, sulphates, phosphates, urea, ammonia and purins; a markedly increased output of carbon dioxide; a diminished sugar tolerance and perhaps glycosuria; a diminution or disappearance of the glycogen of the liver; a loss of weight, chiefly due to loss of water; frequently a rise of temperature, sweating, weakness, headache, and sometimes nausea, irritability, restlessness, muscle tremors and twitchings, palpitation, tachycardia, precordial pain, and even attacks suggesting angina pectoris. * * * * The administration of even a very large single dose of thyroid or thyrotoxin does not, as a rule, produce very marked effects; the latter seem to be dependent on the continued presence of thyroxin in the tissues (Kendall)." Hunt and Seidell proposed that the "official preparation should contain 0.2 per cent of organically combined iodine; this standard has also been adopted by some foreign manufacturers." * * * *

"The unsatisfactory results frequently reported from the use of various special preparations are probably due largely to failure to base the dosage on the iodine content, or, in other cases, to some method of treatment that has altered the normal relations of the iodine in the thyroid."

"The U. S. P. thyroid is very stable; preparations twelve years old have shown undiminished activity by both physiologic and clinical tests."

### Adhesions to Trachea

Adhesions of the skin wound to the trachea with consequent tugging upward of the entire scar area every time the individual swallows is one of the most annoying of the minor unfortunate consequences which follow thyroidectomy. It will be noted as long as an operator continues to employ the midline of the collar incision as the point of issue for drainage material, no matter what sort, which comes in contact with the trachea on its way into the cavities from which the thyroid lobes have been removed. A scar of this sort binding the skin to the trachea can be absolutely prevented by suturing in great part a midline fascia and muscle wound (provided, of course, one has been made) and bringing out drains at or toward the two angles of the collar skin incision. Reference to the chapter on Wound Drainage and the accompanying illustrations will make quite clear these suggestions for avoiding this complication.

### Disfiguring Scar

A skin scar which cannot be hidden by a slender chain necklace may be regarded rightly as somewhat disfiguring. This is a matter, however, within the power of the operator to regulate, as is explained in detail in the section on the Skin Incision. An accessory drain opening is never necessary and is a prolific source of unsightly skin scar. A keloid tends to form in any skin scar in some persons. Just why this is so has never been quite satisfactorily explained; so that there is no known way to prevent its occurrence, and the operator is therefore always blameless in those rare instances when it does follow thyroidectomy. Unfortunately there is no known way of curing one of these disfiguring keloids, although we hoped in the early days of radium a cure-all had been found. It is well that patients differ greatly in susceptibility to the impressions made by scars on their necks. Fortunately the wounds of many of the patients who have the worst looking scars had to be left wide open because of the highly toxic condition of the individual; these patients seem most grateful for recovery from an intolerable condition, and seem to think the unsightly scar a very small price to have paid for their well-being. On the other hand, the patient who has a goiter removed for cosmetic purposes may

be pardoned a certain degree of resentment if the neck in the final analysis seems to her to look worse than it did before she consulted a surgeon. All such reasoning is, of course, trivial by comparison with the real issue which is that an unsightly scar on one woman's neck may prevent another woman from having removed a goiter which is gradually undermining her health or indeed threatening her very existence, hence a subject which at first thought might seem hardly worthy of consideration becomes in some instances at least a very real issue.

I have in a few instances, as has been mentioned, seen a typical keloid occur in the incision scar when there had been nothing out of the ordinary in the making or healing of these wounds to account for such a complication. In one instance the original keloid was excised only to be followed by another, which was also excised, and though the greatest pains were taken with this third closure and afterwards to keep tension off the cicatrix, a third equally large keloid formed in the same spot.

In December, 1921, I excised an enormously wide scar (vertical) from the right side of the neck of Mrs. S., which joined an ordinary collar scar made by another surgeon years before when he had removed the right lobe of her thyroid. The right end of the scar ran straight toward the angle of the jaw and almost up to that point.

This is not an isolated instance, since the patients who come to us for thyroidectomy very frequently present strangely placed scars which are the result of preliminary ligations or earlier attempts at partial thyroidectomy, but in very few instances they result from bilateral resections which have been followed by recurrence.

As a rule a ligation scar, especially one that lies in a fold of the neck, is so small and becomes so obscured with the passage of time that it requires no effort for its correction.

It is often quite another matter with thyroidectomy incisions, especially those done some years ago, at a time when less attention was paid than now to cosmetic considerations in this field. It is almost impossible to correct the line of any scar which is not easily covered by a chain of beads. Most difficult of all are those made by the vertical median or oblique lateral incision. I have only encountered one such midline scar

through which an osteopath had endeavored to remove thyroid tissue. Unfortunately a keloid change had taken place in it, rendering it one of the most unsightly spectacles imaginable.

Another case was observed, after ligation in another clinic, with an oblique scar following the direction of the upper sternomastoid muscle which looked as though the wound might have gradually healed by second intention.

In many others that come to our clinic two-thirds of the scar follows the line indicated by a chain of beads, but one end points upward toward the ear, and with it nothing at all can be done to hide it beneath a narrow necklace. Study of the transverse neck folds indicates in most instances that no attempt was made to exactly reapproximate by suture the divided skin edges, with a result that can easily be imagined.

In still another class of scars the median third or half evidences a collar-like incision corresponding to the approved line, but *both* lateral extremities point almost directly upward like a pair of cow horns, thus rendering any attempt at easy concealment abortive even though there can have been no possible gain to operator or patient by the fact that they were originally so planned.

About the only advantage of excising these malplaced scars —median vertical, lateral oblique, or single and double cow horn incisions—is gained by replacing heavy cordlike scars with accurately sutured wounds which result in a thin, fine, linear cicatrix. Such a scar is always less conspicuous than its predecessor, although there is no possibility of covering it.

In one instance in which I operated for a recurring, slow-growing sarcoma of the thyroid, my properly placed chain of beads by which my incision was marked lay at least three to four centimeters above a rough, heavy scar which at its midline crossed the unfortunate young lady's manubrium sterni. I feared to sacrifice the skin between the two, and so this young person, otherwise quite handsome, has her neck marked by two circular incisions some distance apart, one of which she can cover without difficulty with a chain, while the other is unduly conspicuous because no attempt was made to give it a cosmetic value when her first operation was planned.

(It must be admitted in this connection that we occasionally

in our own clinic remove a thyroid lobe through an oblique lateral incision along the anterior margin of the sternomastoid muscle, but this incision is used only on men for the reason that the resulting scar can be hidden completely by the collar and is therefore not open to serious objection; however, we employ it only on a patient in whom the need of what amounts to emergency surgery may be said to exist.)

No matter where the primary incision has been made, it should be excised rather than split if touched at all, provided, of course, that the patient's condition warrants the expenditure of a very little extra time. A very much better looking secondary scar results from the approximation of soft, normal skin than from the reunion of scar tissue; incidentally, the likelihood of primary healing is at the same time very much greater.

It will be noted that all of our secondary operations on the thyroid are based, like those of a primary nature, upon the choice of the Boeckel collar incision as being absolutely the only one indicated on a woman's neck, for the simple reason that it is the only one which can be hidden during the early period before it becomes inconspicuous as most of them do when the healing process is complete.

## Malignancy

There is an old adage in thyroid surgery that malignant disease, when it can be diagnosed is no longer operable, and for this reason we discover by accident early malignant foci in glands which we have removed under the supposition that they are benign. Since most of the thyroids removed at operation are never subjected to careful histologic scrutiny, the impression prevails that malignant disease of the thyroid is extremely rare, or this may have been said to be true before Wilson and other recent writers called attention to its prevalence which is far beyond what surgeons are accustomed to think. In view of what has gone before, it is quite natural to suppose that metastasis has occurred in many of these patients that are operated upon before the clinical evidence enables us to diagnose the original goiter as malignant. Several cases in point follow:

Miss C., who had been successfully operated upon for goiter

began to decline at a late period. After a diagnosis of general *carcinomatosis,* which was believed to be a recurrence from a pelvic tumor previously removed (Schwarz), new sections were made of her goiter (Ives), and a small cancer focus was found in it.

Another example of metastatic cancer is seen in the case of Mrs. D., a middle-aged woman, upon whom a thyroidectomy was done for the removal of a unilateral adenomatous goiter about the size of a small man's fist. Before the neck was opened, another tumor, about one-fourth the size of the adenoma, was observed on the anterior upper aspect of the sternum. The adenoma was removed, but on account of the weakened heart and general toxic condition of the patient, the smaller growth was left for a second operation. Several sections of the adenoma were carefully examined, but no signs of malignancy were found. The patient was sent home with the understanding that she was to return for the removal of the small tumor as soon as she had fully recovered from the thyroidectomy and had shown the usual gain in health following this operation. She improved markedly for about nine months, when she again began to lose weight and strength, and she returned at the end of one year, in poor health, for the removal of the other growth. The size of the tumor had evidently increased, and it was deemed advisable to operate immediately. Upon exposure, the growth proved to be a large necrotic cancer, already advanced to a point beyond hope of surgical remedy. Upon very careful reexamination of the adenoma removed a year before, cancerous cells were found which had been overlooked upon first examination. It is very evident that the cancer of the sternum was the result of metastasis from the goiter, which had already occurred at the time of the removal of the adenoma. The exploratory wound was closed and the patient sent home. She died shortly after of general carcinomatosis.

### Remote Cardiac Failure

The heart that has been damaged by a toxic adenoma may always be regarded as a permanently crippled organ. The affection is truly anatomic in character, a definite myocarditis being demonstrable as a rule by the electrocardiogram. There

is a remote danger in the long-neglected toxic adenoma to which attention may not have been directed; viz., of death of the elderly patient with marked heart damage in six to nine months following a thyroidectomy which was barely possible after the heart had been "propped up" by experts in the hospital. The myocardium seems to "come back" after a successful thyroidectomy for exophthalmic goiter in a much higher percentage of cases than is true of toxic adenoma. Many of these neglected patients succumb as soon as they are exposed once more to the stress of ordinary existence, no matter how well the primary effects of the operation may have passed off. Moral: Do not neglect the early toxic adenoma.

### The Nursing Mother

An example of avoidance of complications in an infant upon whose mother a thyroidectomy has been performed is given in the chapter on After-Treatment, page 337, case of Mrs. B.

### References

[1]Pemberton, John deJ.: Mortality in Surgery of Exophthalmic Goiter, Surg., Gynec., and Obst., April, 1923, xxxvi, 458.
[2]Graham, Evarts: Personal communication.
[3]Crile: Endocrinology, ix, No. 4, p. 305.
[4]Thompson, R. L., and Bartlett, Willard: Occluding Pulmonary Embolism, Ann. Surg., 1908, xlvii, 717.
[5]McCrae, Floyd: A Case of Exophthalmic Goiter Complicated by an Acute Gangrenous Appendicitis, Piedmont Hospital Bulletin.
[6]Fry, Frank R.: Personal communication.
[7]Lahey, Frank H.: Lingual Goiter, Surg., Gynec. and Obst., March, 1923, xxxvi, 395.
[8]Editorial: Endocrinology, October-December, 1920, iv, 600.
[9]Hunt, Reid: Pharmacology of Thyroid Substance, Jour. Am. Med. Assn., October 18, 1924, lxxxiii, 1244.

# CHAPTER XVIII

# LARYNGEAL COMPLICATIONS

French K. Hansel, M.D., St. Louis

Regardless of the most careful and skillful technic in thyroid surgery, it is quite impossible to avoid certain laryngeal complications. They may manifest themselves in various ways, so the surgeon should always have the cooperation of a well-trained laryngologist to estimate the importance of these complications. His judgment should determine the proper procedure to protect the the patient from immediate danger, and, if possible, to offer a prognosis as to the ultimate outcome of laryngeal function.

## Anatomy

Before considering the clinical phases of the laryngeal complications, it will be necessary to emphasize certain practical points in anatomy which will give an understanding of the action of intrinsic and extrinsic muscles and their nerve supply in relation to the functions of phonation, respiration, and deglutition. Cunningham[1] gives the following description of the action of the intrinsic laryngeal muscles and the closure of the larynx during deglutition.

"*Action of the Intrinsic Laryngeal Muscles.*—By the action of the intrinsic laryngeal muscles the position and tension of the vocal folds are so influenced that, during the passage of air through the larynx, the tone and pitch of the voice is determined. Tension of the vocal folds is produced by the contraction of the two cricothyroid muscles. The straight portions of the muscles pull the inferior borders of the thyreoid cartilage downwards, whilst the oblique portions, through their insertions into the inferior cornua, draw the thyreoid cartilage ventrally, thereby increasing the distance between the angle of the thyreoid cartilage and the vocal processes of the arytenoid cartilages. When the cricothyroid muscles cease to contract, the relaxation of the cords is brought about by the elasticity of the ligaments.

The thyroarytenoid muscles must be regarded as antagonistic to the cricothyreoid muscles (Fig. 116). When they contract they approximate the angle of the thyreoid cartilage to the arytenoid cartilages, and still further relax the vocal folds; and when they cease to act, the elasticity of the ligaments of the larynx again restores the state of equilibrium. They also act as constrictors of the supraglottic region of the larynx. The vocal muscles, by the attachments of their fibers into the vocal folds may tighten portions of these folds, but their main action is relaxation of the vocal folds and ligaments (Fig. 116).

"The width of the rima glottidis is regulated by the arytenoideus transversus (Fig. 117), which draws together the

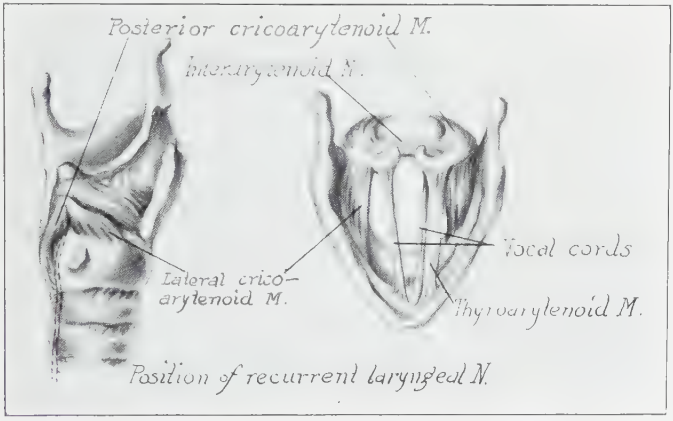


Fig. 116.—Muscles of the larynx. (Redrawn from Spalteholz.)

two arytenoid cartilages, and this may be done so effectually that the medial surfaces of these cartilages come into contact; the pars intercartilaginea of the rima glottidis is thus completely closed. The cricoarytenoideus lateralis and posticus also modify the width of the rima glottidis. When they act together, they assist the arytenoideus transversus in closing the glottis, but when they act independently they are antagonistic muscles. Thus the cricoarytenoideus posticus draws the muscular processes of the arytenoid cartilages dorsally and medially, and swings the vocal processes and the vocal folds laterally, and thereby opens the rima. The lateral cricoarytenoid muscles act in exactly the opposite manner. By drawing the muscular processes of the

arytenoid cartilages ventrally and medially, they approximate the vocal processes and close the rima glottidis (Fig. 118).

"*Closure of the Larynx during Deglutition.*—The muscles of the larynx have, however, another function to perform besides vocalization and regulating the amount of air passing to and fro through the glottis. During deglutition it is requisite that the communication between the pharynx and larynx should be closed, to prevent the fluid or solid parts of food entering the respiratory passages. In the process of closing the laryngeal

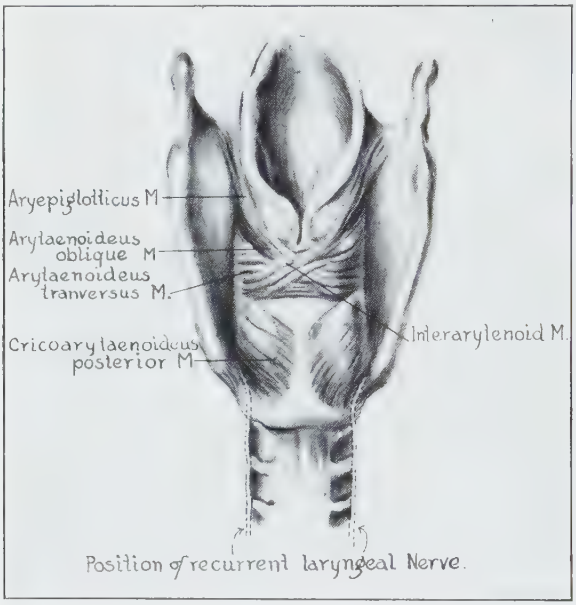


Fig. 117.—Muscles of the larynx. (Redrawn from Spalteholz.)

entrance the epiglottis stands erect, whilst the dorsal wall formed by the arytenoids is carried ventrally, the arytenoid cartilages are closely approximated, glide ventrally, and are then inclined towards the epiglottis. The result of this is that the laryngeal opening is converted into a T-shaped fissure. The median limb of the T is formed by the interval between the closely applied arytenoid cartilages, whilst the cross limb, which lies ventrally, is bounded ventrally (anteriorly) by the epiglottis and dorsally by the aryepiglottic folds. The apices of the arytenoid cartilages, with the corniculate cartilages (Santorini), are pressed against the tubercle of the epiglottis, whilst the

lateral margins of the epiglottis are pulled dorsally so as to make the transverse limb of the fissure distinctly concave in a dorsal direction. The muscles chiefly concerned in producing these movements are the thyreoarytenoid and the transverse arytenoid muscles. These form a true sphincter vestibuli. The thyreoepiglottic and aryepiglottic muscles also come into play (Fig. 117). They pull upon the epiglottis so as to produce tight application of its tubercle to the arytenoid cartilages and

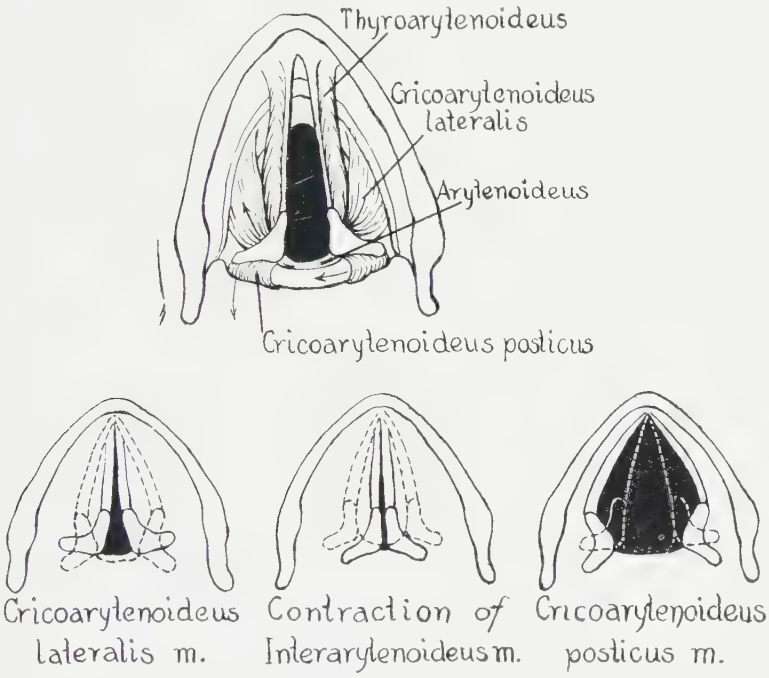


Fig. 118.—Action of the muscles of the larynx. (Redrawn from Judd.)

the corniculate cartilages (Santorini), and they also curve its margins dorsally so as to increase its dorsal concavity."

The dissection of the laryngeal nerves was comprehensively studied on 33 adult specimens by Dilworth[2] (Fig. 119). He divides the superior laryngeal nerve into the internal and external branches. The internal $A^1$ again divides into two branches, the lower of which is called the descending branch $A.^2$ The larger part of the main trunk runs horizontally inwards and divides into four terminal twigs which supply the mucous

membrane of the larynx (Fig. 119-*1, 2, 3, 4*). Three of these twigs end on the epiglottis.

The descending division (Fig. 119-$A^2$) runs downwards in the mesial wall of the sinus pyriformis, giving off two or three branches, to the muscles in the aryepiglottic fold, to the mucous membrane, and to the mucous glands on the posterior surface of the arytenoid cartilage (*5*). Then it gives one and sometimes two branches to the interarytenoid muscle (*6*). This branch was present in thirty-one of the thirty-three specimens

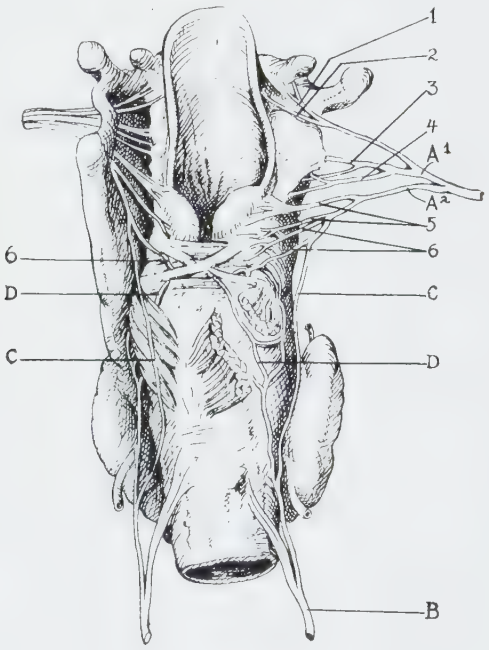


Fig. 119.—Dissection of the nerves of the human larynx. (After Dilworth.)

examined by Dilworth. A small anastomotic twig is sometimes found joining the branch from the recurrent nerve supplying this muscle. The descending division ends by passing downward to join the recurrent nerve as the ramus communicans *C*.

The recurrent laryngeal nerves, *B*, reach the neck from below, passing upwards in the groove between the trachea and the esophagus. In the thyroid region they pass along the posterior border of the gland and are closely associated with the gland capsule. The nerve lies more anteriorly on the right side in relation to the trachea. Each one gives off branches to the

trachea and esophagus in its upward course. About an inch below its point of entrance to the larynx it divides into two divisions, and at the same point one fine twig is supplied to the thyroid gland and another to the upper end of the esophagus.

Of the two main divisions, the smaller one passes upward to join the internal laryngeal as the ramus communicans, *C*. It enters the larynx by piercing the inferior constrictor at the point where the esophagus joins the pharynx. The larger division pierces that part of the inferior constrictor which arises from the cricoid cartilage. As the nerve enters the larynx it is in close relationship to the inferior thyroid artery. After entering the larynx this muscular division runs upward on the lateral border of the posterior cricoarytenoid muscle as far as its attachment to the muscular process of the arytenoid cartilage. In this part of the course a branch is given off to supply this muscle. Then a twig is given off, which passes beneath this muscle to appear again at its upper border. It ends here by supplying the interarytenoid muscle. As it lies beneath the posterior cricoarytenoid muscle, it is joined by a twig which comes from the main part of the nerve, *D*. In this way the interarytenoid muscle receives a double nerve supply on each side. This branch is frequently joined to the one from the internal laryngeal nerve of the same side. As the recurrent nerve continues upward, it lies superficial to the lateral cricoarytenoid muscle, to which it supplies several fine twigs. Occasionally a small twig from the external laryngeal nerve joins it. Finally the recurrent nerve ends by sinking into the thyroarytenoid muscle. Occasionally a small twig from the internal laryngeal nerve joins it.

Dilworth concludes that the laryngeal nerves are really a plexus. The vagus breaks up into a plexus in the larynx just as it does in other localities.

### Disturbance of Laryngeal Function

In 1908 Gleitsmann[3] called attention to the fact that for a full understanding of all laryngeal paralyses, a clear conception of the motor centers in the cortex and medulla, their predominant function, and their connecting fibers, is absolutely necessary.

The larynx has to perform two functions, entirely different from each other, phonation and respiration. The chief center of phonation, adduction of the cords, a voluntary act, is in the cortex; the chief center of respiration, abduction of the cords, a vital process, is in the medulla. In addition there are subordinate centers in reverse order, of lesser importance, for phonation in the medulla and for respiration in the cortex. The connecting fibers run from the cortical to the bulbar center and vice versa, through the internal capsule.

The cortical motor center has been located by Krause[4] in the descending surface of the prefrontal convolution. The bulbar center is located in the fourth ventricle in the ala cinerea, and this center predominates the abductor function.

The influence of the bulbar center on respiration and on the width of the glottis was studied by Semon[5] in an endeavor to ascertain whether or not the vocal cords play an active part during quiet respiration and to determine the cause of the difference between the width of the glottis during life and its cadaveric position after death or after severance of the vagus or recurrent nerves. He concluded that the greater width of the glottis during life is the result of the constant activity of the abductor muscles, caused by tonic rhythmic impulses coming from the respiratory center. He called this physiologic action, the *abductor tonus.*

The lack of this abductor tonus at birth has been recognized as the cause of obstruction to breathing or congenital laryngeal stridor. In 1923 New[6] reported two cases in which the obstruction to breathing was noted at birth. The characteristic symptom was a croaking sound on inspiration, but little or no noise on expiration. The patients seemed to get along well with this difficulty until the second year, when normal laryngeal function appeared. Thomson and Turner[7] hold that the cause of this condition lies in the disturbance of the coordination of the respiratory movements, probably the result of a retarded development of the centers in the medulla which control the abductor tonus. Semon states that the condition is not a paralysis but a clonic spasm of the adductor muscles.

Laryngeal paralyses of central origin are caused by organic affections, while cortical paralysis of a functional nature occurs

in hysteria, psychic emotions, and shock, with concomitant paralysis of the adductors, but not of the abductors.

Complete recurrent or abductor paralyses have been observed, as a result of a number of organic lesions which affect the central tracts or peripheral nerve fibers. Among these various lesions the following diseases are worthy of note: cerebral hemorrhage, meningitis, brain tumors, bulbar and pseudobulbar paralyses, multiple sclerosis, toxic diseases, syphilis, syringomyelia, Avellis' syndrome, Hughlings-Jackson's syndrome, etc. In the laryngeal crisis of tabes the abductor tonus is affected, thus resulting in a contraction of the adductors and causing an interference with respiration.

Semon[8] was the first to proclaim that the abductors suffer before the adductors in central as well as peripheral lesions. But Rosenbach[9] was the first to demonstrate this fact after compression of the peripheral branches of the laryngeal nerves.

Hooper[10] and Donaldson[11] performed a series of experiments on dogs. The recurrent nerves were stimulated by means of an electric current. Hooper demonstrated abduction of the cords. Donaldson showed that a gradually increased current caused the abduction to pass into adduction. After prolonged and strong stimulation, the abductors ceased to act.

Semon and Horsley,[12] in performing experiments on dogs, also demonstrated that the abductor muscles lose their excitability much sooner than the adductor muscles.

The recurrent laryngeal nerve is small but, in spite of this, can be separated into two distinct bundles of fibers (Russell).[13] One of these bundles supplies the muscles of adduction and the other the muscles of abduction. These fibers run in separate bundles throughout the whole course of the nerve. They may be separated so that electrical stimulation may be applied to each set of fibers. Grabower[14] in the examination of the nerve found that the abductor muscles have about 281 terminal fibers and the adductors have 680. He believes that this may explain why the abductors succumb first.

Barwell[15] states that if the recurrent laryngeal nerve is completely paralyzed, the vocal cord assumes the intermediate or cadaveric position (Fig. 120). On the contrary, New[16] says that following injury after thyroidectomy this is rarely seen.

He has noted that in most cases of injury the vocal cord is in the middle line position (Fig. 121). On the other hand, if the vagus is injured as in tumors of the jugular foramen region, the cord takes the intermediate or cadaveric position. The position of the cord in the middle line following injury to the recurrent nerve may be explained on the basis of the action of the

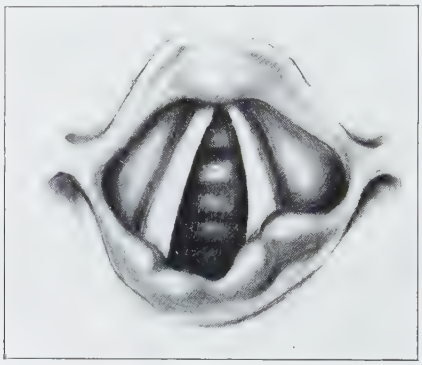

Fig. 120.—The typical image of complete left recurrent paralysis. The vocal cord, in the cadaveric position, appears relaxed, narrowed, shortened, and depressed; the arytenoid, "fallen in," not swollen.

Fig. 121.—The typical image of unilateral abductor paralysis. The vocal cord in the middle or closed position. Arytenoid only slightly "fallen in"; the cord is but slightly depressed or shortened.

arytenoid muscle which has a bilateral nerve supply or it may be the result of loss of abduction and not adduction. This explanation would not hold true in cases of bilateral injury. It may be assumed, therefore, that this position is caused by the action of the cricothyroid muscles or the external tensors of the cords, which are supplied by the internal or superior laryngeal

nerves. Or it may be the result of the combined action of the cricothyroids and the arytenoids, the latter acting through the nerve supply received from the anastomotic branch of the superior laryngeal nerve to this muscle.

In addition to the disturbance of the laryngeal functions of phonation and respiration as a result of injury to the recurrent nerve, there is also a disturbance of the function of deglutition, since the recurrent nerve also supplies the muscles which close the vestibule of the larynx during the act of swallowing. The dysphagia is only temporary, usually disappearing within a few days to a few weeks. Muscular action may be restored by the nerve supply from the superior laryngeal nerve.

On account of the proximity of the recurrent nerves to the posterior capsule of the thyroid, the nerves may be injured by an enlargement of the gland. Because of the tendency of the nerve to remain attached to the capsule, in the gradual enlargement of an adenoma of this region, it is likely to be carried with the gland during any displacement that may occur. In this way the nerve may be injured by stretching. The size of the thyroid enlargement is not necessarily a factor in producing trauma to the nerve, except in cases in which there is a marked displacement of the larynx and trachea. In this instance the nerve on the opposite side may be injured by being stretched or pressed upon. Judd[17] says that paralysis of the recurrent laryngeal nerve caused by goiter apparently occurs in about five per cent of the cases.

The small number of cases in which there has been an injury with resultant paralysis of a vocal cord, previous to thyroidectomy, warrants a careful preoperative laryngoscopic examination of every patient. The gradual onset of paralysis in these cases may produce no definite change in the voice, as compensatory movements of the functioning cord across the midline approximate the vocal cords (Fig. 126); in most instances, however, there is some slight change in the voice. The gradual decrease in the aperture of the glottis during respiration is compensated for by the increased action of the respiratory mechanism. The protection of the functioning cord during operation is of paramount importance, as any injury to it will cause sudden

laryngeal obstruction, resulting in asphyxiation of the patient and necessitating immediate tracheotomy or intubation.

Judd[17] believes that the total loss of the voice in goiter cases is due to carcinoma or hysteria. Bilateral injury from a benign enlargement would be possible but highly improbable. In hysteria some movement of the vocal cords can be observed. In carcinoma there may be a definite injury to the nerves resulting in a total paralysis.

## Technic of Thyroidectomy in Relation to Recurrent Laryngeal Nerve

In 1918 Guthrie[18] described the technic of thyroidectomy with particular reference to the importance of avoiding injury to the recurrent laryngeal nerves. He says, "On the right side the nerve is intimately associated with the inferior thyroid artery, passing either under or over it (Fig. 122). On the left side it is somewhat deeply placed and less often associated with the artery. The nerve on the right side, therefore, is in more danger of being injured than the one on the left.

"To avoid the nerve the dissection should begin well up on the side of the gland and not down underneath it. The vessels are clamped as they enter the capsule of the gland, and if the nonvascular zone described by Crile is entered, it is surprising how the gland may be dissected out of its bed with little loss of blood. It is important always to stay well within the capsule on the gland, because the nerve lies behind it. In attacking the lower poles of the gland the forceps should be placed high up on the gland parallel with the long axis of the neck. Judd often includes some of the gland with the vessel in this step of the operation. Any rough handling, forcible delivery of the gland, or dry gauze dissection in this region should be avoided, for it is here that trauma to the nerve takes place.

"In case of severe hemorrhage, it is unwise to attempt to catch the bleeding vessels in a pool of blood. The vessels themselves should be found and clamped individually. If the gland has been resected, as Balfour advises in large colloid goiters, it is well to remember the proximity of the nerve to the lower pole and to the posterior surface of the gland and make sure that the nerve is not caught in the lock sutures."

### Disturbance of Function After Operation

The disturbance of laryngeal function following thyroidectomy may be permanent or temporary. In the majority of cases it is only temporary. Judd[17] states that those disturbances may be due to one or more of the following factors:

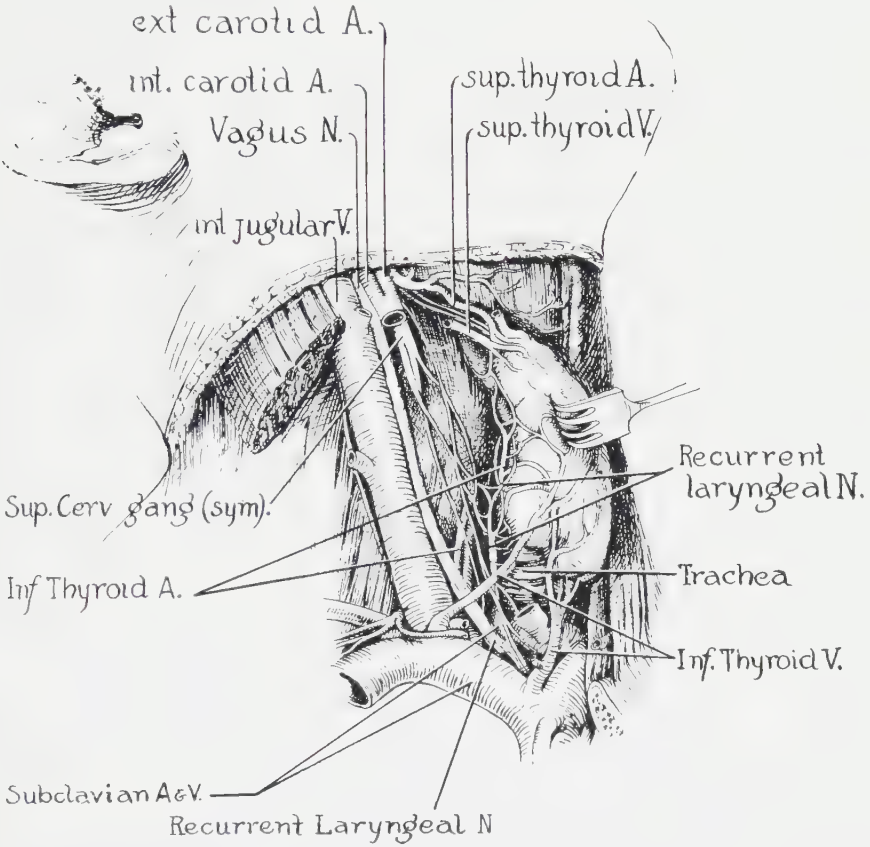


Fig. 122.—Dissection of neck, showing the intimate relation of the recurrent laryngeal nerve to the inferior thyroid artery. The gland has been pulled toward the midline to expose the nerve. (Redrawn from Guthrie.)

1. Change in the position of the muscles and cartilages because of the shifting of the misplaced larynx back into normal position.

Marked displacement is caused by a large adenoma which is situated so as to push the larynx to one side or the other. After removal of the goiter, the larynx returns to its normal

position, and there may be some temporary loss of voice which returns to normal within a few days.

2. Edema of the tissues. There is considerable variation in the amount of edema. It is important during the operation to keep the line of dissection as far away from the larynx as possible, so that the postoperative reaction does not extend into the mucous membrane of the larynx.

3. A true myositis may occur as a part of the edematous process or may follow injury to the extrinsic muscles.

4. Trauma of the recurrent laryngeal nerve. Judd believes that the nerve is more often injured at the point of entrance into the larynx than at the point where it crosses the inferior thyroid artery. While the nerve may not frequently be severed completely, it may be pinched by a hemostat with other tissue or may be caught in a ligature while a vessel is being tied.

In 1917 New, Judd, and Mann[19] performed a series of experiments on dogs in which the laryngeal nerves were subjected to different degrees and types of trauma. In twenty-four cases in which the nerve was pinched, the vocal cord was paralyzed. Function returned in sixty days in the cases in which the nerve was pinched at the lower pole, and in thirty days when it was pinched close to its entrance to the larynx. In all cases complete function returned. In another series of nineteen cases the nerves were ligated with plain and chronic catgut, resulting in complete and permanent paralysis. After a period of 160 days there was no return of function. In a few cases the nerve was cut, resulting in complete and permanent paralysis. In a series of nine cases the nerve was stretched for a few minutes, but in one case only was there a paralysis. In four cases the stretching was maintained by suturing the muscles under the nerves, and in three cases paralysis occurred.

These experiments show, therefore, that cutting or tying the nerve with catgut will cause a permanent paralysis. Pinching or stretching will produce only a temporary paralysis, and function will be restored.

Injury to the superior laryngeal nerve is very uncommon, and may be caused by instrumentation or by the injection of local anesthetic. The results of this injury are, a disturbance of the sensation of the laryngeal mucous membrane and a

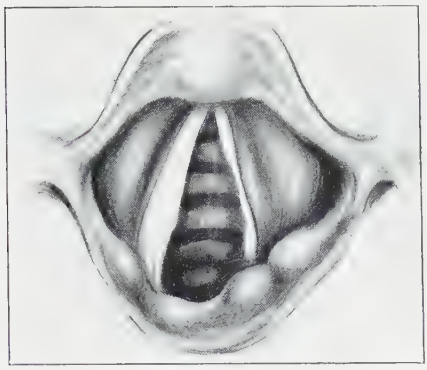

Fig. 123.—A variation from the typical image of recurrent paralysis. The ventricular band is swollen.

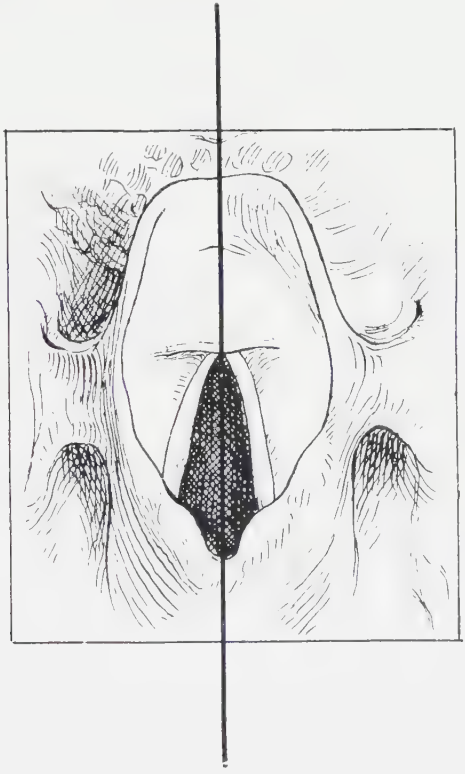

Fig. 124.—Recent left recurrent paralysis during respiration. Cord is in cadaveric position.

paralysis or paresis of the cricothyroid muscles. Therefore, a numbness in the larynx and a relaxation of the vocal cord may be observed.

An injury to one recurrent nerve at the time of the operation immediately shuts off one-half the opening of the glottis and as a rule only slight dyspnea occurs. This disappears within a few days as compensation for the smaller air passage is established.

If the patient has a cardiac lesion or his general condition is poor, the respiration may be considerably embarrassed. Should edema of the larynx occur with a unilateral cord

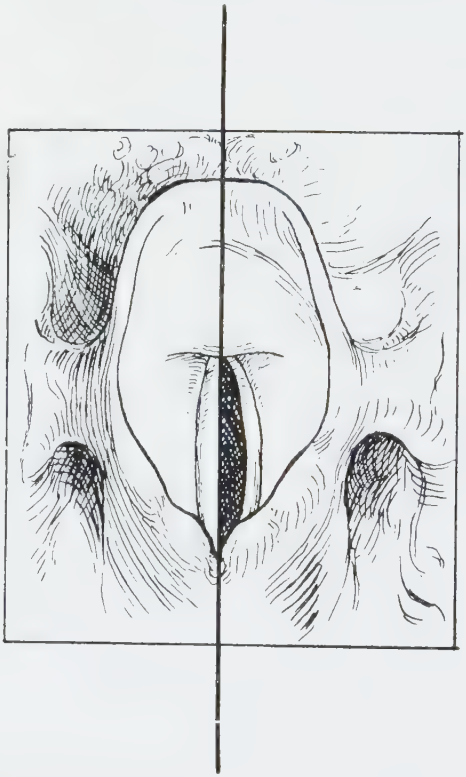

Fig. 125.—Recent left recurrent paralysis. Phonation.

paralysis, the degree of obstruction will be much greater and the dyspnea may be a serious complication (Fig. 123). If the cord is in the cadaveric position, the margin is bowed and the arytenoid process falls forwards. In this position it appears swollen (Fig. 120). If edema is present, it will be much larger; the two conditions should be distinguished from each other. If the cord is not bowed, the enlargement of the arytenoid process is the result of swelling.

If the cord assumes the cadaveric position immediately after injury (Fig. 124), there may be a temporary loss of the voice, when the functioning vocal cord does not cross the midline (Fig. 125). There is a tendency, however, for the functioning cord to cross the midline almost immediately to approximate its fellow, resulting in a restoration of the voice (Fig. 126).

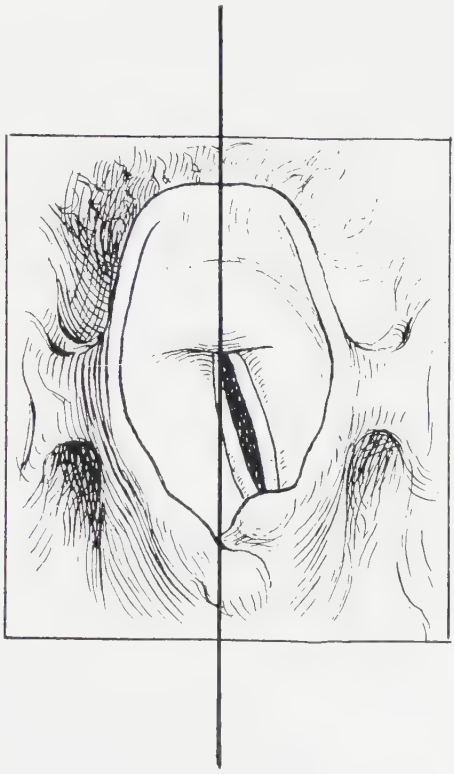

Fig. 126.—Left recurrent paralysis. Compensatory movement of right cord across midline.

## Classification of Cases of Paralysis

New[16] says that the intermediate or cadaveric position of a vocal cord always changes to the middle line position not later than from three to six months following thyroidectomy. This change will result in an improvement in the voice. In cases of unilateral paralysis New believes that this improvement of voice is attributable to one of three conditions: First, change from the cadaveric to the so-called middle line or abductor position

(Fig. 127), resulting in a tense cord which is approximated by the opposite one; second, movement of the functioning cord across the midline to approximate its fellow (Fig. 126); and third, return of function of the paralyzed cord, if the injury is temporary.

Cases of unilateral paralysis are not expected to produce a serious outcome, but in the bilateral paralysis in which the cords assume the middle line or bilateral abductor position, the degree of obstruction is almost complete and the patient's life

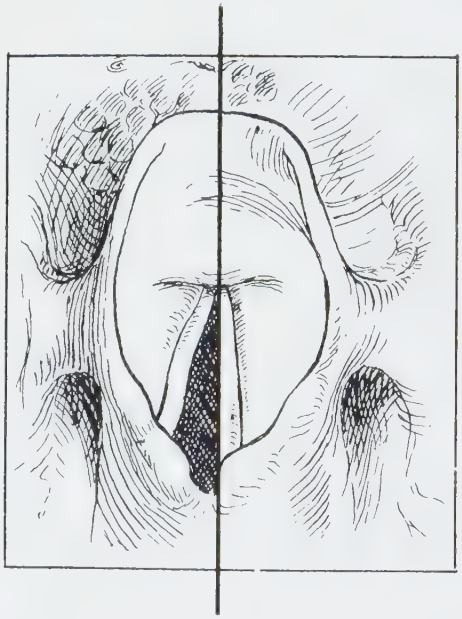

Fig. 127.—Left abductor paralysis during respiration.

may be seriously endangered (Fig. 128). New has classified these cases in three groups:

Group 1. Cases in which tracheotomy is necessary at operation. It is generally believed that the sudden obstruction is due to tracheal collapse, but in most cases it is caused by injury to the recurrent laryngeal nerves.

Group 2. Cases with no paralyses following operation, but within three to six months there is an onset of increasing dyspnea with voice almost normal.

Group 3. Cases in which the cords are in the cadaveric position after operation (Fig. 129). This is the most unusual

type. There is no obstruction, but the voice is absent. Within three to six months gradual obstruction occurs with improvement of the voice as the cords reach the middle line position.

In offering an explanation for the cause of the bilateral abductor position we may assume that it is caused by injury or scarring of the recurrent nerves, in such a way that the abductor fibers are paralyzed and the action of the adductors produces



Fig. 128.—Double abductor paralysis.

this position of the cords. On the other hand, we may assume that this position is produced by the action of the cricothyroid muscles or external tensors which are supplied by the superior laryngeal nerves and by the development of increased function of interarytenoid muscles through its nerve supply from this source. In Group 2 it would seem very improbable that external scarring would so injure only the abductor fibers equally and bilaterally, as to cause this position of the cords. In Group 3 it

is difficult to understand how the adductor fibers regenerate equally and bilaterally. Of course, we do not see these cases until obstruction occurs, then both cords are in the midline. If we were able to follow these cases closely, we might observe unequal regeneration. If one side regenerates first, there may be sufficient restored action of the arytenoid muscles, which have a bilateral nerve supply, to produce this position of the cords.

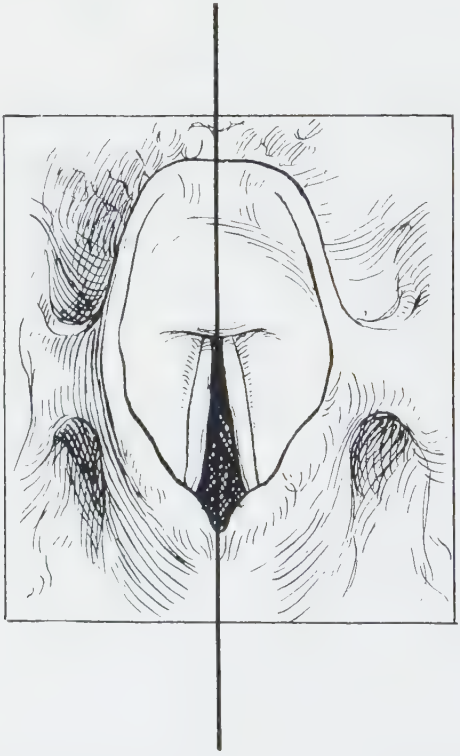

Fig. 129.—Double recurrent paralysis. Cords midway between cadaveric and midline position.

In cases of incomplete injury to the recurrent nerve it is possible to conceive of greater injury to the abductor fibers since they are fewer in number and are more vulnerable to trauma than the adductors.

The control of the adductors and the other muscles concerned in the sphincteric action of the glottis is voluntary, while the control of the abductors is almost entirely reflex. There-

fore we should expect the adductor function to return more readily than the abductor function.

### Treatment

In the treatment of the laryngeal complications of thyroidectomy the conditions with which we are immediately concerned are, obstruction to breathing, difficulty in swallowing, and tracheitis.

Obstruction to breathing is caused by edema of the laryngeal mucous membrane or paralysis of the vocal cords. The edema is acute and usually lasts only a few days. It is generally not of sufficient degree to produce definite obstruction, but if it is associated with a unilateral or bilateral paralysis, the respiration may be considerably embarrassed.

The edema may be treated by the use of one or more topical medications, which will produce a shrinkage of the tissues. Adrenalin inhalant, diluted one-half strength with olive oil, may be applied by syringing or spraying it into the larynx. It produces a marked but temporary shrinkage of the tissues; therefore it must be repeated every three or four hours until the swelling subsides. Compound tincture of benzoin used in the form of a steam inhalation should be employed by the use of a tent or from an inhaler. If the patient is unable to tolerate adrenalin, other astringent remedies, such as menthol, camphor, eucalyptus, etc., may be used as substitutes.

Dysphagia, or difficulty in swallowing, accompanies recurrent nerve injury. It is usually temporary, as the patient soon compensates for the disturbance of muscular action in the act of swallowing. It is very difficult for these patients to swallow when in the recumbent position. If they are permitted to assume the erect position, they will be able to take liquids without very much difficulty. The administration of large doses of narcotics makes the patient stuporous, and the dysphagia is increased.

A mild degree of tracheitis accompanies practically every case of thyroidectomy, and, in some instances, it may be very marked. It is always a great annoyance to the patient. The mucus becomes adherent to the lining membrane, and the patient has to clear it out frequently by coughing. The use of compound tincture of benzoin steam inhalations is very helpful in these cases.

Tracheotomy is resorted to only when the degree of obstruction is such that the life of the patient is endangered. During the operation on the thyroid gland, both recurrent nerves may be injured in such a way that the cords come together in the midline. This results in immediate and serious obstruction, which necessitates a tracheotomy at once. It is generally believed that the sudden obstruction is due to tracheal collapse. In the cases of unilateral paralysis the degree of obstruction is rarely dangerous, but if edema is present, a tracheotomy may be necessary. Treatment of the edema should always be tried first.

**Surgical Repair of Recurrent Laryngeal Nerve.**—In cases of paralysis of the vocal cords there may be some permanent disturbance of the function of respiration or phonation. Sufficient time should be allowed to elapse for return of function in cases of temporary paralysis. When it has been decided that the paralysis is permanent, the surgeon may resort to a means of restoring the integrity of the recurrent nerves.

In 1924 Frazier[20] reported a group of twelve cases, nine of which had paralysis following thyroidectomy. Nine operations were performed in which the recurrent nerve was anastomosed to the descendens noni hypoglossi. In three cases function had begun to return. Sufficient time had not elapsed to warrant a report on all the cases. He emphasizes the importance of making a proper selection of cases for operation. The suitability of a given case depends on (1) the duration of the paralysis, (2) the motility of the cricoarytenoid joint determined by passive motion with laryngeal forceps, and (3) the existence of an undamaged segment of nerve.

The indications for the operation are (1) to enable the patient to dispense with the tracheotomy tube or to relieve glottic obstruction, (2) to restore normal phonation.

In considering an appropriate nerve for anastomosis to the recurrent, Frazier selected the descendens hypoglossi, first because it is easily accessible; second, because it is a pure motor nerve; third, because in the physiologic sense the muscles supplied by the recurrent nerve and ramus descendens hypoglossi are a part of the same apparatus; and, finally, because this nerve could be sacrificed without any ill effect.

In the technical consideration of nerve suture, the type of anastomosis used should depend upon the individual case. Lateral implantation should be the operation of choice if the paralysis is incomplete. If the operation fails, the nerve will not be completely paralyzed. If the paralysis is incomplete and bilateral, total paralysis of one cord would help rather than hinder the patient. In these cases it would be preferable to cut the nerve for end-to-end suture.

If the damage to the recurrent nerve can be repaired and the nerve preserved in its continuity, this should be the operation of choice. By nerve liberation from scar tissue or nerve suture at the site of injury, the function of the nerve may be restored.

## References


[1]Cunningham: Textbook of Anatomy, 1914, ed. 4, Wm. Wood & Co., pp. 1076-1077.

[2]Dilworth, T. F. M.: The Nerves of the Human Larynx, Jour. Anat. and Physiol., 1921-22, lvi, 48-52.

[3]Gleitsmann, J. W.: Recurrent and Abductor Paralysis of the Larynx, Ann. Otol., Rhinol., and Laryngol., September, 1908, xvii, 587-606.

[4]Krause, H.: Arch. f. Anat. u. Physiol., 1884, vol. Physiology, p. 203.

[5]Semon: Proceedings of the Royal Soc., 1890, xlviii, 403.

[6]New, G. B.: Congenital Obstruction of the Larynx and Pharynx, Jour. Am. Med. Assn., August 4, 1923, lxxxi, No. 5, pp. 363-366.

[7]Thomson, J., and Turner, A. L.: On the Causation of the Congenital Stridor of Infants, Brit. Med. Jour., 1900, ii, 1561-1563.

[8]Semon, F.: Clinical Remarks on the Proclivity of the Abductor Fibers of the Recurrent Laryngeal Nerve to Become Affected Sooner Than the Adductor Fibers, or Even Exclusively, in Cases of Undoubted Central or Peripheral Injury or Disease of the Roots or Trunks of the Pneumogastric, Spinal Accessory or Recurrent Nerves, Arch. Laryngol. u. Rhinol., 1881, ii, 197-222.

[9]Rosenbach: Bres. Aertz. Ztg., 1880, Nos. 2 and 3.

[10]Hooper, F. H.: The Anatomy and Physiology of the Recurrent Laryngeal Nerves, New York Med. Jour., 1887, xlvi, 29-35; 63-66; 99-103; 150-152.

[11]Donaldson, F., Jr.: The Function of the Recurrent Laryngeal Nerve, Am. Jour. Med. Sc., 1886, xcii, 93-103.

[12]Semon, F., and Horsley, V.: On an Apparently Peripheral and Differential Action of Ether upon Laryngeal Muscles, Brit. Med. Jour., 1886, ii, 405-407; 445-447.

[13]Russell, J. S. R.: The Abductor and Adductor Fibers of the Recurrent Laryngeal Nerve, Proc. Roy. Soc., London, 1892, li, 102-112.

[14]Grabower: Quoted by Gleitsmann, 1908.[3]

[15]Barwell, H.: Laryngeal Paralyses and Their Diagnostic Value, Lancet, London, 1905, i, 1481-1484.

[16]New, G. B.: The Larynx in Diseases of the Thyroid, Ann. Clin. Med., January, 1923, i, No. 4, 262-265.

[17]Judd, E. S.: Laryngeal Function in Thyroid Cases, Ann. Surg., March, 1921, pp. 321-327.

[18]Guthrie, D.: Temporary Loss of Voice Following Thyroidectomy, Jour. Am. Med. Assn., 1918, lxxi, 715-718.

[19]Judd, E. S., New, G. B., and Mann, F. C.: The Effect of Trauma on the Laryngeal Nerves, An Experimental Study, Ann. Surg., 1918, lxvii, 257-262.

[20]Frazier, C. H.: Anastomosis of the Recurrent Laryngeal Nerve with the Descendens Noni, Jour. Am. Med. Assn., Nov. 22, 1924, lxxxiii, No. 21, pp. 1637-1641.

# CHAPTER XIX

## AFTER-TREATMENT

The after-treatment of simple goiter and of toxic goiter patients will be considered as one, although after the removal of a nontoxic goiter usually very few, if any, of the remedial measures are employed that are used following thyroidectomy for toxic goiter. The sicker the toxic individual, the more complex is the after-treatment, whereas many an uncomplicated, nontoxic patient requires practically no attention excepting removal of wound clips, a dressing or two, with rather careful feeding. It must be admitted that in a very few of the simple goiter patients adequate after-treatment is required for pneumonia, postoperative hemorrhage, tetany, hypothyroidism, etc., still it would be very generally admitted that every toxic patient, by virtue of the mere fact that she is toxic, presents numerous postoperative problems in addition to all of those which are possible to the patient who has had a simple goiter removed. The toxic patient is always a sick patient after operation, whereas the simple goiter patient rarely is, but to avoid the possibility of endless repetition, the problems of the two will be considered as one and the reader left to select the suggestions which may seem to fit his individual patient.

Crile[1] urges that the bad risk surgical thyroid patient be protected against suboxidation, inhalation anesthesia, lack of water, pain, absorption of wound secretion, infection, fear and worry, postoperative hyperthyroidism, and postoperative hypothyroidism. He feels that when the patient is protected from these, the operability of the bad risk goiter patient becomes 100 per cent. Thus it will be seen that after-treatment really begins with these considerations before the operation.

### Sedatives

**Sleep.**—An important element in the after-care of the goiter patient is sleep that insures freedom from pain during the first ten to twelve hours which follow the operation. The preopera-

tive administration of veronal, 20 to 30 grains, during the twenty-four hours preceding the operation meets this requirement in a way which leaves little to be desired. The patient takes little, if any, interest in her transportation from the table to the bed, then settles into a tranquil slumber for several hours. She can be readily awakened, but usually remembers very little of what transpired during the first postoperative day. There is a striking freedom from postoperative nausea, and fluids can be given freely by mouth, though this must be at the nurse's insistence, since the patient is far too drowsy to express her desires if the preliminary narcotization has been carried out in a manner befitting her needs.

**Morphine.**—Every goiter patient who is not already too deeply morphinized to make this procedure dangerous is given a dose of morphine, commensurate in size with the degree of toxicity, on the operating table about the time operation is completed. A nontoxic patient never receives more than ¼ grain. The amount for toxic individuals will average about half a grain. In this way we guarantee the patient against awakening suddenly soon after leaving the operating room and experiencing intolerable discomfort while the traumatic insult is still very recent. Morphine is continued for the first twenty-four hours for several obvious reasons.

The amount varies greatly in the individual instance and can be determined in only one way known to me, that is, by its effect upon the respiration. The older injunction that the respiration shall not go under 16 seems by no means adequate, since the patient who is breathing at the rate of 50 or 60 per minute would probably have life endangered if this rate were reduced to 16; for this reason, we are accustomed to base our treatment on the current rate of respiration, feeling that it is usually safe to reduce it one-third and never more than one-half.

Morphine does not always accomplish the desired results. Smoking an occasional cigarette on the third day did as much as morphine in the case of one of our maniacal patients. In another case in which morphine proved ineffective because of its nauseating effect, an enema containing sodium bromide, gr.

40, with chloral, gr. 40, repeated in four hours quieted the patient.

**Luminal.**—Many physicians at present seem to prefer luminal to veronal when contemplating the use of any of the barbituric acid compounds. If this newer drug is preferred, ½ grain doses will replace the 5 grain doses of veronal; although its action is not quite so pronounced, it has apparently certain advantages over veronal. It seems, in the hands of myself and associates at least, to produce very much less disturbance of equilibrium; nausea seems to be less common with it, and headache is somewhat less frequent.

## Fluids

For thirty-six to forty-eight hours following operation in the extremely toxic patient, the toxicity increases, and it is during this period that administration of fluids is essential to rid the system of the toxic products by elimination. The more toxic the patient, the greater the necessity of forcing fluids.

**Proctoclysis.**—Frequently nausea and vomiting prohibit drinking during the first twenty-four hours. Of several methods of administering fluids, proctoclysis is the simplest and least annoying at our disposal. For this purpose an isotonic fluid is indispensable, as will occur to any one who has administered, or himself taken, an enema of plain water which is so irritating that it is very quickly returned. The two isotonic solutions most readily available are physiologic salt solution and 5 per cent glucose solution. The salt solution is not always advisable, because we have frequently to deal in toxic goiter cases with damaged kidneys where salt-free diet is being carried out. Of the 5 per cent glucose solution, almost invariably a quart will be retained if an hour be devoted to its administration and it may be repeated in six or eight hours. It is practically never rejected unless the lower bowel is packed with fecal material, in which event it acts as might be expected of any sort of enema under such circumstances. To guarantee against its loss, we are accustomed to give these patients an ordinary cleansing enema twenty-four hours before operation. This is done very cautiously because many of them are handicapped and are not to be stirred up by a violent enema or cathartic of any kind.

Proctoclysis may be continued over longer periods unless the patient begins to expel the solution. A rest of several hours will allow the intestine to dispose of what fluid remains and render it capable of further absorption, when rectal administration may again be instituted if the patient is unable by this time to take sufficient fluid by mouth.

Forty grains of chloral hydrate combined with the first quart of 5 per cent glucose solution will keep the average patient quiet and free from the need of morphine or other sedative drugs for the greater part of the day on which the operation is done.

**By Mouth.**—As soon as the patient is wide-awake and able at all to swallow, she should be given fluids by mouth, beginning with cracked ice, water, and as soon as possible, nourishing drinks, the same as are used in encouraging the patient to take an adequate amount of fluid during the preparation.

**Nasal Tube.**—Many patients after thyroidectomy cannot, will not, or should not swallow because of strangling, in which case fluids may be introduced through a nasal tube.

It is in most instances rather easy to pass a small rubber tube through the nose or mouth, half way down the esophagus. In fact such a tube can in most instances be left in place almost indefinitely. This is, however, by no means a universal rule as shown by the example of Mrs. D., October, 1924, who sustained a temporary injury to both recurrent laryngeal nerves during the removal of an enormous adenomatous thyroid which grew very deeply backward into both sides of the neck, as well as downward under both collar bones. She was unable to swallow without coughing or strangling and she manifested every evidence of a severe pharyngitis, laryngitis, and tracheitis. The pharynx remained extremely dry, and apparently as a consequence of this, and possibly other abnormal conditions, three of us failed to pass a fine rubber tube. It was finally necessary for a laryngologist to insert, under direct vision, a tube containing a metal stylet through which fluid in any quantity was administered without difficulty, while the tube remained in place for some time.

The use of the small nasal stomach tube is especially valuable in the transient "recurrence" paresis which sometimes complicates the operation.

**Hypodermoclysis.**—Hypodermoclysis[2] may be used in the event that sufficient fluid cannot be administered by mouth and by proctoclysis.

## The Wound

**Dressing.**—After-treatment may properly be said to begin with the application of the first dressing. This consists of gauze enough to cover the wound, over which is placed a "perineal pad" of cotton (gauze-wrapped), with a second similar pad placed behind the neck and widely overlapping the ends of the first. The second pad catches the drainage which always runs back over the shoulders onto the back of the neck and stains the pillow and bedding unless this pad be used. A towel binder is crossed over the front of the neck and held in place by diagonal adhesive strips carried under the axillae. This makes a most comfortable and agreeable *splint* for the tender neck.

**Skin Clips and Sutures.**—Clips are applied to the skin of open wounds on the second day. The fibrin is scraped off, and the skin edges freed slightly.

The skin clips must be removed at the expiration of twenty-four hours, since they tend to produce pressure decubitus if left in place longer. This is especially true after secondary closure of skin flaps which have become edematous or infiltrated during the one or more days that have intervened since their elevation. It is presupposed that no more pressure will have been employed in a secondary case than the minimum required to hold the parts in place.

Running sutures (silkworm gut) are removed from two to seven days following operation, depending upon when they loosen and become easy to get out. One end is clipped off close to the skin, and the other end is caught by a forceps and pulled in a line with the wound.

**Open Wound.**—An infected neck wound is always treated with exposure to air half of the time in the belief that a dry wound offers less encouragement to the growth of bacteria than does one covered with a "pus poultice." Such patients wear a hygroscopic glycerin pack covered with rubber at night during the period when contamination of such a wound is most likely, but during daylight hours, if the patient be rational and in the

mood to cooperate, such a wound does much better if exposed to the air. If the day be sunny, the rays of the sun are allowed to fall directly upon the wound, or if not, the same thing is accomplished with a carbon filament electric light, although I am not absolutely convinced that heliotherapy does more than stimulate the patient's interest and imagination, a thing which in itself may not be without some therapeutic value.

**Packs and Drains.**—Rubber packs are as a rule to be removed in twenty-four hours, since (1) bleeding ceases within that time, (2) tissue surfaces are sealed by fibrin against absorption, (3) infection is inevitable sometimes if a wound remains open too long, and (4) dysphagia and other symptoms referable to the pack must not be unduly prolonged. The patient is turned on her face for one hour after the removal of the rubber packs so that any serum will run out. After this, secondary closure is done. By no means should the wound be closed immediately after the removal of the rubber pack without allowing the serum to run out.

Gauze packs are left in for forty-eight hours provided there are no toxic or pressure symptoms arising before this time.

As a rule guttered tubes placed in the cavities, crossed in the center and coming out the opposite angles of the wound are removed the day following the operation in the case of all ordinary sized goiters. In extremely large tumors the drain is left in place from one to seven days, depending upon the size of the cavity.

**Blebs and Retained Serum.**—Frequently in thyroid cases in which the gland was very large, there is a quantity of serum formed which finally works its way towards the surface. This is relieved by tapping with a needle connected on a 20 c.c. syringe and withdrawing the fluid (Fig. 130). The time to do this is usually when the cavities fill up and the skin shows signs of fluid beneath under pressure.

**Toxicosis.**—In highly toxic individuals a marked rise in temperature and increase in pulse rate sometimes occurs six or seven hours following operation; for example, the temperature may reach as high a point as 104° in a few hours and the pulse 170 or 180. This condition is usually caused by absorption of

the toxins of the serum which has backed up in the neck. Glycerin packs are tried first, changing them every hour or two, which will very often be sufficient. However, if the temperature continues to rise or does not decrease, then the neck, if closed, should have the clips removed, should be opened wide and poured full of sterile glycerin. A large glycerin pack is then placed over the wound. If the wound is open and packed with gauze or rubber, the packs should be removed so that any serum that may have backed up can flow out and the same procedure as above should be carried out. In case of any bleeding, if it is

Fig. 130.—Removal of a postoperative collection of blood serum.

impossible to catch the bleeding point, the wound is to be repacked only in the area from which bleeding is coming to prevent hemorrhage and still allow serum to drain freely from the remaining portion of it. It is astounding to see how quickly the temperature and pulse will drop following this procedure.

**Infection.**—Gross infections of the neck following thyroidectomy practically never occur at the present day because postoperative rise of temperature accompanied by evident blebs or collection of serum are promptly treated as outlined on pages 282, 329. It must be added that most wounds in thyrotoxic patients which have been left open twenty-four hours or more

become mildly infected, although it is unusual for anything more than local manifestations to appear. These are treated as are infected wounds elsewhere in the body. They are widely opened, hot glycerin packs are applied, rubber packs and drains are inserted and where there is any tendency toward devitalization and sloughing, the wounds are frequently bathed with Dakin's solution. In only one instance in my entire experience has it seemed necessary to make counter-openings behind the sternomastoid muscle and institute through and through drainage in the treatment of pus which had collected in the space formerly occupied by a large thyroid lobe. Whenever suppuration persists in this region, one should be led to suspect that some sort of foreign body has been left behind.

**Secondary Closure.**—Secondary closure is usually made at the end of twenty-four hours. All clots are to be carefully removed to avoid prolonged drainage. If the secondary closure involves a midline muscle-fascia wound after removal of both lobes, we often insert one or two catgut sutures in the ribbon muscles and overlying fascia, and thus prevent a certain degree of flattening. Nothing of the kind happens after the unilateral resection in which the sternomastoid is retracted and the ribbons split, therefore no deep sutures are needed here.

When clips are to be employed, a little gas is usually administered, though this can be done following an infiltration of the skin edges.

Frequently I have inserted a running subcutaneous silkworm suture on the table, which has merely to be drawn tight twenty-four hours later to completely coapt the edges of a skin wound. This causes considerable discomfort, therefore a whiff of gas may well be given to an especially unstable patient. In highly toxic individuals it is well to leave a small rubber drain tube for twenty-four hours longer unless the wound seems particularly dry when the original pack is removed.

**Stiff Adherent Skin.**—The stiff, adherent skin about the collar incision scar of which a patient now and then complains is treated with diathermy or by having her frequently but gently massage it with cold cream, apply gentle warmth to it in the

form of electric pads, or expose it to rays of the sun or of an electric light. This is very soothing to her susceptible nervous apparatus, does the scar some little good, and can do no harm.

## Respiratory System

It is quite to be supposed that the respiratory tract would be more affected following goiter operations than perhaps any other surgical procedure because of manipulation of the structures in direct relation to it.

**Aspiration Pneumonia.**—The treatment of aspiration pneumonia in operations which involve the trachea, larynx, and pharynx should be largely preventive. This means that the patient should be given nothing at all to swallow when one has reasons to suspect that his manipulations have resulted in interference with the sensory nerve supply of the lower pharynx and epiglottis. Just these patients who cannot properly take cognizance of foreign substances entering the larynx through faulty protection by an anesthetic epiglottis rapidly develop tracheitis, bronchitis, and bronchopneumonia. They should, in addition, not attempt to swallow their own saliva and mucus, something that can be prevented to a great extent by placing the patient on her face or even causing the head to hang over the edge of the bed occasionally in order that all fluids may naturally gravitate toward the mouth and nasal cavities.

**Abductor Paralysis of Larynx.**—The treatment of abductor paralysis, which, aside from sudden death on the table, is perhaps most dreaded of all complications in this field, is handled in detail in Chapter XVIII.

**Sore Throat.**—In treating the sore throat which is a typical consequence of manipulation of the trachea and esophagus, we must remember that rest of these viscera will alone predispose to spontaneous subsidence or disappearance of symptoms. The early convalescence is made very much more bearable, however, in many instances by the inhalation of steam, by the patient's holding ice low in the pharynx, by the application of constant heat in the form of an electric pad outside the wound dressings. Very frequently a large glycerin pack kept fairly warm gives considerable relief and is always worth trying where there is sore throat.

The treatment of **suffocation due to reactionary hemorrhage** is taken up under Complications, page 280. In some instances at least it is necessary to hastily remove sutures, turn out a clot which is compressing and distorting the trachea, then ligate the superior thyroid artery from which the ligature has slipped off under the influence of coughing or vomiting soon after the patient has been placed in bed. Such an instance is given in detail in Chapter XVII, page 277.

**Paralysis of the vocal cord and hoarseness** with their treatment are taken up in detail in Chapter XVIII.

### Cardiac Disturbances

As will be seen by referring to the special chapter on goiter heart, it does practically no good at all to digitalize a patient with a rapid heart in exophthalmic goiter because of faulty nervous control mechanism when the electrocardiogram fails to demonstrate myocardial change.

Our problem is to keep the nervous patient quiet with morphine after operation and in this way avoid a load being thrown on the heart, thus preventing a rise in pulse rate. The really damaged heart, on the other hand, must be discovered before operation so that preoperative digitalization may prevent undue rapidity after the procedure has been undertaken.

The typical goiter heart of large adenomata, especially intrathoracic ones, is very prone especially in elderly people to go into fibrillation. The digitalization of such patients combats the condition more adequately than does any other method at our command. Formerly we employed it with a measure of success after fibrillation had set in, but now we feel that a distinct advance has been made in that the suspect patient comes to operation already completely digitalized.

When it is found necessary to give digitalis after operation, we prefer in our clinic to give 1 c.c. of digifolin every three hours intravenously until the massive dose has been given.

There are some heart cases that digitalis will not affect. In them we try quinidin. Mr. G., who had an exophthalmic goiter complicated by auricular fibrillation, was given digitalis over a long period with no effect on the heart condition. Quinidin was tried, with the result that fibrillation ceased.

Through its use the patient was put in good condition for operation. Following each ligation and each lobectomy the patient's heart went into fibrillation, and was brought back to normal by the use of 10 grains of quinidin at the onset of fibrillation, followed by 5 grains of quinidin every three hours until the heart was regular.

### Digestive Disturbances

**Diet.**—Practically the same diet may be carried out in the after-treatment as that used during the preparation for operation (page 102). Of course, it is obvious that during the first few days the patient will have difficulty in swallowing solid foods. Increasing amounts of nourishing liquid foods are given until the patient can tolerate the regular high caloric, low protein diet. This routine obtains during the patient's stay in the hospital; the section covering instructions to the patient upon going home (page 342) includes information regarding the diet after leaving the hospital.

**Vomiting.**—Vomiting (without dilated stomach) is due to some toxic influence, thyroid or drug, and is not benefited by lavage. It is well to remember that the patient vomits more easily with something in the stomach, therefore one must not fail to give as much water as is vomited to prevent retching, which is very distressing, especially to a goiter patient. Frequently food does much toward stopping such vomiting, though in a measure it is self-limiting. *Be sure to keep the fluid intake up to the output* by hypodermoclysis when vomiting persists. Chloral by rectum will quiet the patient and will not increase the vomiting. Morphine in extreme doses will stop the vomiting as a rule, as well as keep the patient quiet, an important measure on account of the heart. Of course its administration is contraindicated in persons in whom it is known to cause vomiting, a fact that will have been discovered long before the necessity for after-treatment.

**Care of the Bowels.**—Care of the bowels is of special importance in these toxic patients who are so abnormally sensitive to the action of drugs because the leading symptom of many of them is a tendency to diarrhea, in many instances of an exhausting character. The same type suffer so frequently from

nausea and vomiting that mineral oil cannot be employed because it tends to incite or increase an already existing nausea. Enemas are frequently badly borne because their action tends to exhaust the sensitive, toxic patient; in consequence of their use a hyperperistalsis is produced which would be no more than extremely unpleasant for the normal individual.

My own feeling is that the toxic patient is better let alone so far as the bowels are concerned up to the point where urgent abdominal symptoms are caused by constipation or where fecal impaction can actually be demonstrated. In our clinic in such instances we try to employ enemas alone if this can be done, using warm physiologic salt solution which gives the gentlest possible response and is frequently all that is needed. If this does not suffice, we give an enema of 3 ounces of saturated magnesium sulphate solution which acts in many instances promptly and efficiently by completely relaxing tonic spasm of the lower bowel, thus permitting the intestines to function more or less in their own way. It is only under most exceptional circumstances that we employ any of the more drastic enemas such as soapsuds or glycerin. We have very rarely had to employ a cathartic in a toxic individual, and certainly never used anything more potent than compound licorice powder or aromatic cascara sagrada.

Diarrhea is an expression of vasomotor relaxation. It occurs in the worst type of patient and is very exhausting in character. It not only interferes profoundly with nutrition, but becomes frequently very serious, depleting the water reserve of the body to the danger point and beyond. These are two very clear-cut indications for maintaining the intake of fluid above the level of the output, which can be done in the several ways already treated extensively under the heading of "Administration of Fluid." The second step, and of equal importance, is, if possible, to check the diarrhea. This is done in two ways: first of all through every effort to control the nervous mechanism at fault, namely, by physical and mental rest, which have been treated extensively; second, through drugs which have to be relied upon when the situation becomes extreme, it being utterly useless to temporize with any of the newer or highly recommended remedies other than the opium derivatives. The

higher the metabolic rate, the higher the opium tolerance. One is often astonished at the excessively large amount of opium taken before its physiologic action is apparent.

### Deprivation

The acute deprivation which results from sudden almost complete removal of a large amount of functioning thyroid is to be considered very much more in detail than has been the case in the past. Acute hypothyroidism may be precipitated by removal of a high percentage of thyroid tissue, especially in the case of a young person. During youth the physiologic function of the thyroid is to influence growth. Before puberty the tendency of thyroid deficiency is to cause cretinism, and after sexual maturity, myxedema is caused by thyroid depletion. Because of the close relationship of the thyroid and the ovary, the thyroid has a periodic influence during puberty, menstruation, pregnancy, and lactation. It is obvious from the foregoing arguments, that a sufficient amount of thyroid gland should be left to maintain approximately the function of the normal gland if at all possible. When it is impossible to leave an amount that will take care of the needs of the patient during youth or over one of the particular periods of life in woman, the administration of thyroxin is indicated. On October 24, 1924, I removed most of the thyroid gland of Mrs. B., a young woman of twenty-six, nursing a two-months-old baby. She was subsequently given $\frac{1}{160}$ grain of thyroxin every day for about a month, then on alternate days for another month, and then every third day for a third month, by which time her residual thyroid tissue had supposedly accommodated itself fairly well to its load. Actual conditions may be determined by occasional metabolic rate tests.

We are accustomed in many very young patients to administer thyroxin in diminishing doses for from one to three weeks after thyroidectomy, always keeping in mind, of course, the patient's symptoms. We thus prevent what may be termed physiologic shock, which may, I am sure, in many instances be of serious import. As soon as the patient can swallow, three doses a day of $\frac{1}{160}$ gr. of thyroxin may be given the first week, two doses a day the second week, and one dose a day the third

week. After this, for at least one year such patients should have a small dose of iodine every day. It matters not in what form it be used. It is my custom to use one tablet of Oridine (Eli Lilly), this being iodine combined with fatty acids. It looks and tastes like a small piece of chocolate candy. In this way the likelihood of recurrence is practically eliminated, as explained in detail in the chapter on that subject.

Crile uses syrup of iodide of iron for one year after removing a large amount of thyroid to prevent secondary hypertrophy by having so much iodine in the system that the residual thyroid has very slight demand made upon it.

### Miscellaneous

**Pain and stiff neck** are perhaps best treated, aside from the use of sedative drugs, by a form of splint dressing. This consists of enormous gauze-wrapped cotton pads which encircle the neck, being just as thick behind and on the sides as they are in front, impinging strongly upon the head and upper chest, the motive being to gently limit all spontaneous movements and thus render the individual more comfortable than she would otherwise be if she had to splint her own neck wholly by keeping the neck muscles upon tension.

**Lactation.**—Mrs. B., a young mother twenty-six years of age, nursing a two-months-old baby, had a large adenoma causing partial obstruction of the trachea and I felt that operation could not be delayed on this account. A combination anesthesia was given consisting of infiltration masked by extremely light ethylene anesthesia. The customary amount of the thyroid was removed, and since no morphine had been employed, the patient was never nauseated. No morphine, ether, or other drug which might go over from the mother's blood into the milk having been used, the child's nursing was practically uninterrupted. One feeding time was passed because it coincided with the period that the mother was on the operating table. A second was passed because we had failed to notify a nurse of the old school that the feeding should be uninterrupted, and instead of finding the baby at the breast when we made rounds after the morning clinic, we discovered the nurse in the praiseworthy attempt of using the breast pump. After these two interruptions, the

nursing continued as usual. Meanwhile the mother made an uneventful recovery, the baby showing no symptoms at any time which might have been explained as a result of the ordeal through which the mother had passed.

**Treatment of Postoperative Hemorrhage.**—Following operation every wound must be watched for evidence of hemorrhage, which is often brought on by the strain of coughing, vomiting, etc. The closed wounds are to be even more closely watched, for hemorrhage has been somewhat anticipated in the open wound by the use of packing.

Frequently slight external pressure will stop a hemorrhage. This may be applied in the form of a pressure bandage, which amounts to a figure-of-eight bandage around the neck. If this does not stop the hemorrhage, the dressing is to be removed and the bleeding points sought and clamped. Sometimes the source of the bleeding is just under the skin where the vessel can be very easily clamped.

If these measures fail to check the hemorrhage and it is becoming profuse, the wound must be opened wide, packing must be removed, and the bleeding point sought and clamped or ligated and the wound repacked. Frequently upon opening the wound the point from which the hemorrhage is coming can be found, in which case only the area from which the hemorrhage is coming should be packed individually and the remainder of the packing should not be disturbed. In severe hemorrhage, however, it is necessary to remove all packs and clean out the clots and repack the whole wound.

Along with these special procedures, general measures are carried out as for general hemorrhage, such as administration of morphine, etc. If from the start it is evident that the patient is losing much blood, all preparations must be made for blood transfusion.

**Treatment of postoperative tetany** depends, of course, upon a definite knowledge of the cause in the individual instance. In one case mild symptoms appeared twenty-four hours after operation and were instantly relieved by loosening a tight constricting bandage which evidently interfered a bit with the blood supply of the parathyroids. In a second similar instance the evacuation of a large blood clot twenty-four hours after the

operation gave immediate relief to pronounced tetanic manifestations. On a third occasion a large dose of morphine caused the permanent disappearance of very mild tetanic symptoms, the origin of which was never explained. The use of calcium lactate controlled mild symptoms in an eighteen-year-old girl for six months after operation, during which period symptoms reappeared as often as the use of the drug was stopped. After the expiration of this time, she remained perfectly well without any treatment; one is led to suppose that mild tetany may at times be transient and without any very definite significance.

Parathyroid feeding has in my own hands been absolutely without avail, therefore I cannot from my own experience recommend its use. Complete removal or destruction of the parathyroids is an unthinkable accident at this time when we all leave a thin layer of thyroid tissue covering the posterior capsule behind which the parathyroids lie and respect the integrity of the inferior thyroid arteries from tiny branches of which they receive their blood supply.

It will be assumed from the foregoing that parathyroid tetany must, then, in nearly all of the rare instances where it is observed be due to some slight transient interference with the nutrition of these little bodies, therefore the ultimate prognosis is good, except when diffuse suppuration has led to necrosis of all of them as related in the chapter on Complications, page 283.

## Hygiene

**Special Nurse.**—It is well during the after-treatment to have with the patient a nurse familiar with goiter cases of all types. This is especially true in toxic and exophthalmic cases. She must be able to recognize the symptoms of pressure and choking, which are so often caused by bleeding even though there is no external evidence of it. It is the duty of the nurse to know the positions in which to place the patient as to comfort, and if the patient is sleeping from drugs, the position to free the throat from mucus, as well as the position for the best possible drainage. It is essential that she know and watch the effect of different drugs on different patients. It is she who is in closest touch with the patient and able, for instance, to detect whether

it is the effect of morphine that nauseates a patient, in which case she can advise the physician so that some other sedative may be used. Upon the nurse depends the successful administration of fluids—by mouth, proctoclysis, and hypodermoclysis. She alone can be sure that these procedures are properly carried out.

It is necessary that the nurse be familiar with the dressing procedures in the different types of closure. She must have a definite knowledge as to when it is necessary to call an interne for dressing should the dressings become saturated with drainage material.

The nurse plays a very special rôle in the prevention of postoperative complications, especially pneumonia. It is frequently within her power to prevent this complication by seeing that the patient is dressed properly, that she wears the same sort of clothing in the hospital to which she is accustomed at home, underwear, gowns, etc., by changing the patient's position frequently, and by so ventilating the room as to have plenty of fresh air without drafts.

If patients do not feel strong enough to have a bath, they should not be aggravated by forced bed baths for several days following operation simply because the nurse feels that it will make them feel better, this being especially true if clamps are left in position. A partial bath sometimes tends to quiet the nerves if it can be done quickly and quietly without materially disturbing the peace and quiet of the patient.

After operation the same precautions should be taken as during the preparation, to keep the patient and her surroundings quiet until the first time she sits up, when she may be permitted to have a limited number of visitors. She should never have too many visitors while she is in the hospital.

**Getting Out of Bed.**—The nontoxic patients who show little ill effect of the operation are permitted to get up on the first, second, or third day after operation. In fact, some of them have sat up within a few hours, although this is hardly to be recommended in general. Breathing is facilitated by lifting the head up, and as a rule various forms of discomfort in the neck are more relieved by getting the patient out in a chair than by any other procedure known to us. There is no better guide as to when such a patient shall get up than the return of

appetite. One should never be permitted to get up until she has eaten her first hearty meal, after which she is not likely to become unduly faint or fatigued from the effort.

Mrs. K., from whom a large colloid goiter had been removed with perfect hemostasis, was up the day after operation, walked at will on the second day and went home on the third day. This represents our ideal.

The importance of maintaining the life habits of an elderly bad risk patient is shown in the after-treatment of Mr. J. (May, 1922). After the removal of an enormous adenomatous thyroid, he ate a hearty lunch, then sat on the porch during the afternoon. He was a man of seventy-seven with a chronic aortic lesion thoroughly compensated, being always up and around.

In the case of the toxic patient, this matter of getting out of bed assumes a totally different aspect. Here a premium is put on keeping the individual quiet as long as he can be kept content in bed. We have here to deal not only with a damaged heart, but almost always with loss of strength and an emotional state which responds badly to the least strain or fatigue.

**Exercise.**—Under the old obsession that one must exercise to gain strength, toxic patients simply increase their toxicity instead of gaining strength and they tear down everything that has been built up. These patients have a distinctive restlessness with a tendency to want to exercise. The fact must be impressed upon them that through conserving their energy they will gain their strength, and that so long as exercise fatigues them, they will simply increase their toxicity. It is not well to insist on the patient's remaining in bed while she is still too weak to exercise if she becomes too discontented there, as this only entails for her a mental strain in addition to the physical strain of remaining quiet against every impulse to get up. Such patients should be permitted to sit out of doors in the sun, or if the weather is too hot, in partial shade, but in the fresh air. This will often bring peace and contentment and at the same time assure a maximum amount of rest. Further exercise, such as walking, etc., should only begin when the feeling of strength has returned. Of course, I have due regard for the fact that permanent disuse of the muscles leads to a lack of strength, and I am not urging anything of that kind, but a distinction must be

drawn between the patient who refuses to use the muscles and the one who desires to use them but who is really too weak and who needs building up through rest and nourishing food.

**Going Home.**—The nontoxic patient goes home after being up sufficiently long to know that she can climb stairs, eat her meals, dress herself, take her bath, and not be too much dependent upon skilled nursing care. Usually in about three or four days after operation she can leave; in very rare instances is the total hospital stay longer than one week.

In the toxic patient the matter of going home has quite another phase. These sensitive, temperamental individuals must be carefully guarded against every sort of nervous upset, in addition to the damaging physical possibilities just mentioned. It is my custom to keep them in the hospital until a certain mental equipoise has been established. If this be not possible, I like to send them back to the old time environment by degrees. It is well for such a woman not to return directly to the old surroundings when hospital protection is given up, but to go at first to the home of a relative or friend for a few days where she will learn to depend upon her own resources to a certain extent before she returns to the scene of her nervous and physical collapse and encounters the very irritations which did their part in breaking her down.

Dr. Stuart McGuire gives his patients the following printed instructions upon dismissing them from the hospital:

The full benefit of your operation may not be experienced at once. Your improvement should be progressive, but you can do much to get well and stay well by observing the following instructions:

It is important to avoid undue mental excitement and physical overstrain. If anything worries you, put it off. If you get tired, stop and rest.

Get an abundance of rest by going to bed early, getting up late and taking a nap in the afternoon.

Fresh air day and night is important. Sleep with the windows open. Be careful, of course, to avoid cold by being comfortably clothed or covered.

Use nothing that irritates the nervous system. Tea, coffee, alcohol, and tobacco should be avoided.

Your diet should be generous and wholesome. It should be adapted to increase your weight. Eat white meat sparingly and avoid red meat entirely. Do not take beef tea or meat broths.

Live principally on milk, buttermilk, cream, butter, eggs, bread, cereals, fresh vegetables and cooked fruit. Grape juice and other drinks prepared from fruit will be found palatable and beneficial.

Drink an abundance of water. If there is any doubt as to its purity, boil

it for twenty minutes and allow it to cool before using. Distilled water is desirable if it can be obtained.

Take regular but very moderate exercise.

The bowels should be regulated as far as possible by natural means, such as water, food, exercise, and the establishment of a regular hour of going to stool. Occasionally a mineral oil may be necessary.

If in doubt about anything, consult your physician, who has been acquainted with your condition and advised as to the treatment you are desired to follow.

Please report your condition by mail at the end of three months. If you are well, the information will help us; if you are not well, we may be able to help you.

**When Patient Should Go to Work.**—As a last consideration in after-treatment comes the important matter of advising the toxic patient about the time he or she should return to work. There is somewhere a very fine distinction to be made between working too early, the risk of overfatigue with second collapse, and too long idleness attended by melancholy reflection on permanent incapacity. No general rule can be drawn concerning all cases. This matter must be worked out in detail by an intelligent physician and patient in each instance. In any case, the approach to a full day's work must be gradual and the few hours allowed in the beginning must be well within the individual's tolerance, the load to be increased as the capacity is seen to grow.

## References

[1]Crile, George W.: The Protection of the Patient in Surgery of the Thyroid, Surg., Gynec. and Obst., March, 1921, xxxii, 213.

[2]Bartlett, Willard: Hypodermoclysis, Ann. Surg., February, 1921, lxxiii, 161.

## CHAPTER XX

## RECURRENCE

Many patients to whom thyroidectomy is suggested ask me whether goiters ever recur. This is a question which every surgeon doing this work must be prepared to answer. Undoubtedly there have been many recurrences in the past, as will be seen by a perusal of what follows; still I am firmly convinced that we can, for the future, assure one whose goiter is about to be removed that she has this matter largely in her own hands; in other words that she has little to fear provided she will keep in touch up to forty years of age with a physician familiar with the physiology of the thyroid. After forty she may be assured that this accident does not take place. This claim is fortified by the statement of DeQuervain[1] that 94 per cent of all recurrences are in persons under forty, and that the younger the individual, the greater the likelihood of recurrence.

Forty per cent of the 167 thyroidectomized patients examined by Klose and Hellwig[2] either had recurrent goiter or had been reoperated upon. More than two arteries had been ligated in 20.5 per cent of these cases. In 13 per cent both lobes had been resected. Klose and Hellwig find colloid goiters most likely to recur. (Of course, they mean adenomatous goiters containing a large amount of colloid substance.)

Dubs[3] reports that 6.2 per cent of his 840 goiter operations were for recurrence. The interval of recurrence ranged from one to twenty years, while the period was from six to twelve years in seven cases in which a second recurrence necessitated operative interference.

Dr. Halsted[4] told me that he had seen a bilateral regrowth after subtotal thyroidectomy which was practically the size of the original. I have frequently taken out a larger lobe, then bitten out a piece from the opposite side, and later seen the second side develop to a size greater than the original mass, but recurrence in the stump of the lobe which has been resected is in no sense to be confused with the overgrowth of a lobe which has been left untouched at the time when most of its mate was removed.

Recurrence of the growth must be kept in mind as a possibility after almost complete removal of any type of thyroid enlargement. This is no doubt to be explained as a rule by the dictum so forcefully quoted by Crile, that the residual thyroid tissue finds its iodine function too difficult, hence it hypertrophies; but this task can be rendered very easy by simply surcharging the blood with iodine. This gifted author believes that he prevents or limits a secondary enlargement by administering the syrup of iodine of iron after operations likely to be followed by this late complication.

The possibility of malignant growth in a thyroid stump is by no means to be lost sight of, whether or not such disease has been present or recognized at the time of the original operation. Miss K. (May, 1924) furnishes an example of this kind. Her thyroid had been removed in large part at least three years before she came to us, then one and one-half years later a similar tumor started to grow and when we saw her, it had attained the size of about half her head without impairment to her general health. It was hard, large, nodular, moved with swallowing, and was free of surrounding tissue. The removal was most difficult as was the diagnosis after inspection and microscopic examination. The pathologists finally concluded that the growth was a fibrosarcoma which had shown a very low degree of malignancy, though to the operator there appeared many extensive areas of thyroid tissue in which were patches presenting every evidence of what is commonly called woody thyroiditis. This picture will not be forgotten in the presence of a future recurrence.

My own thyroid work has been characterized by relative freedom from recurrence which I have attributed to the custom of making a more extensive resection than has been done often by others whose work I have had the privilege of observing. It has been my plan, for instance, to expose the tips of the upper poles, to isolate and divide the superior thyroid vessels well away from the goiter and thus be sure of getting the entire pole. This is only one example of attempting to remove as much tissue as possible without uncovering the important structures which lie immediately behind the posterior capsule. It has always seemed preferable to risk removing too much rather

than too little, since most patients I believe will be found to prefer the use of a little thyroxin to a second surgical operation for recurrence. All authorities seem to agree that the likelihood of recurrence is increased in proportion to the amount of goitrous lobe left behind.

As to the type of goiter in which recurrence is to be expected, Hotz[5] reports thirty-two histologic examinations of recurrent goiter of which all but one were nodular. In two cases there were two recurrences, so that the author procured in each instance three tumors for examination, and he states that the histologic picture was invariably the same as in the original growth.

An adenoma is essentially a form of tumor and there is a time when every adenomatous nodule is too small to be seen with the naked eye. Is it any wonder, then, that recurrence should be seen by far most frequently in the adenomatous form of goiter when we are constantly leaving behind thyroid tissue which is doubtless studded with these undeveloped tumor foci too small for the eye to detect? Simple enucleation of a single predominating adenoma or cyst of adenomatous origin is very likely indeed to be followed by recurrence, since it is hardly thinkable that a thyroid lobe should contain but one such focus, although the others may be too small to be noticed.

I am inclined to believe that we frequently overlook tiny single adenomata near the midline of the neck either above or below the isthmus. These may or may not be truly accessory thyroids, but the point is that they frequently enlarge when left behind and have to be removed secondarily. As an illustration of this possibility in a toxic young girl, the following case report from my own experience is submitted.

Miss V. D., seen November 4, 1924, presented a very noticeable tumor of the right thyroid lobe almost five years after a bilateral subtotal thyroidectomy. At the time of operation the right lobe is said to have been the size of an ordinary lemon and the left lobe the size of a very large lemon. At that time a moderate shell of thyroid tissue was left covering the posterior capsule on both sides. She was eighteen years of age at the time of the operation and considered mildly toxic as shown by the fact that she was nervous, had a tremor, palpitation, pulse

ranging about 125, blood pressure 128/66, insomnia and loss of general strength. In spite of the patient's youth, her symptoms were apparently due to mildly toxic adenoma. Her weight one week after the thyroidectomy was 111 pounds. She gained very rapidly in strength; her hyperthyroid symptoms gradually cleared up; she went to college where she excelled as an athlete and her weight went up to 130 pounds. The neck remained free from any evidence of recurrence for about three and one-half years.

She returns now stating that for about a year and a half the lower right neck has shown what she calls "lumps." They have been increasing in size and she is becoming nervous. She says she is very easily irritated, which was not formerly the case, and she suffers much from what she terms "nervous headaches." She has lost five pounds in weight; her physical strength is markedly decreased and she complains bitterly of a lack of energy in work, play, study and social activities. When I talked to her she could hardly hold back the tears, and it was plain that this robust athlete of eighteen months ago had deteriorated rapidly.

Physical examination today shows no specific exophthalmic goiter eye signs, pupils are equal, medium, and react to light. Her teeth are perfect; her tonsils have been removed. The thyroid gland is very perceptibly enlarged, apparently this being confined to the right lobe alone. The trachea is slightly deflected to the left. The left lobe cannot be palpated, nor is there any dullness in either upper chest region. The thyroid tissue is hard, distinctly nodular, and the lobe approximates a small lemon in size; it moves very readily in swallowing and no thrills or bruits are detected. There are no tremors.

My explanation of the recurrence is as follows: In operating on an eighteen-year-old girl, I naturally left behind somewhat more thyroid tissue than would ordinarily be done on a patient in more advanced years. No doubt there were buried in this tissue rest adenomatous nodules too small to see or feel which in the course of time have exerted their inherent tendency to enlarge and produce mild thyrotoxic symptoms.

My adenoma recurrences have all been at a rather remote date, that is, a few years at least after the operation in every

instance. They always occurred in patients who were dismissed from observation prior to the time, several years since, when we made it a routine practice to administer iodine in small doses for a protracted period to every patient leaving the hospital after a goiter operation. It must be remembered in this connection that the administration of iodine has no influence on the development of adenomata in the first incidence, hence its value in this connection would seem to be concerned with hypertrophy of the parenchymatous tissue in which these tiny tumors are sown or else in exophthalmic goiter it would be useful as a preventive in much the same sense that Plummer uses Lugol's solution in treating the developed case of exophthalmic goiter based upon hyperplasia.

All experimenters have found that iodine usually protects animals, in which three-fourths of the thyroid has been removed, against recurrence. Loeb went still further than this and found that thyroid feeding would definitely protect in guinea pigs where he went beyond the iodine limit. Marine agrees with Loeb that one can remove nine-tenths of an animal's thyroid and still gain immunity from regeneration by thyroid feeding.

There is but scant reference in the literature, to anatomic recurrence in hyperplasia of the thyroid with the outspoken picture of exophthalmic goiter. In spite of the fact that writers of note seem to feel that nearly all recurrences follow the removal of adenomatous goiters, still I have seen this complication twice after the bilateral resection of exophthalmic goiters.

Miss D. M. returned January 2, 1925, one year after the first half of her thyroid had been removed, and nine months after the same treatment of the second half. Hers was a typical case of exophthalmic goiter in a girl of seventeen when first seen. During the nine-month interval she had continued to improve, having gained ten pounds, and being free from the previous symptoms of nervousness, palpitation and sweating. Palpation indicated that there was a symmetrical recurrence in both lobes; however, the enlargement was not so great as that of the original goiter. In spite of this, the girl was still at her maximum of improvement, although she had not gained in weight (112 pounds) for the last few weeks, as she had steadily done up to that time. Palliative measures were decided upon in the hope

of checking the growth. All stimulants, as well as red meat, were withheld, and she was requested to obtain a maximum amount of rest. Administration of Lugol's solution, five drops a day, was started and later cut down to two drops, which was continued over a period of three months. Deep x-ray treatment was applied to the thyroid area—for three weeks, two exposures a week; then for six weeks, one exposure a week. Following this period, she spent three weeks in a small Kentucky town where her appetite became voracious, and with rest, she has gained nine pounds, looks considerably better, and has improved in all particulars. Her present weight is 116 pounds, blood pressure 138/80-75, pulse 116. The thyroid enlargement can no longer be noted save in front of the trachea where a large, thickened residual isthmus can be palpated, but not seen when she swallows. She was dismissed April 8, 1925, as cured.

Another case of recurrence of exophthalmic goiter was that of Mrs. H., a middle-aged woman who had about half of each lateral lobe removed at two separate sittings, the reason for so incomplete a resection being that her condition seemed to warrant only the minimum of operative trauma. The symptomatic improvement was splendid and continued for about two years, at the end of which time both lobes commenced to enlarge again with a return of all the typical symptoms, which increased in severity until I saw her at the expiration of five years after the operation, when the thyroid was larger than it had ever been and the patient was in a deplorable condition. At this time she refused to have anything further of an operative nature undertaken.

### Operative Considerations in Recurrence

There are definite operative indications in recurrent cases just as in primary cases, and many of the same considerations should be taken into account.

Why operate for recurrence? Certainly not merely because the patient has a goiter. There is no more reason for doing this than there would be for operating on a new mass merely because of its presence. The matter should be considered along the lines originally considered as affecting the particular patient. Are there pressure symptoms of great enough moment to war-

rant operation? Is toxicity increasing in keeping with the growth of the tumor? Is operation justified for cosmetic purposes? This is a point of much greater importance in secondary goiter than in primary, because the patient once relieved of an unsightly goiter, insists upon remaining free of it.

It is not always a simple matter to **establish indications** for secondary resection. A few years ago I was consulted by an American woman who had had one lobe removed five years previously by the most prominent European goiter surgeon of his time. Upon the development of marked pressure symptoms with slight enlargement of the neck, she returned to him, and because he was too busy to take care of her, she was referred to his former first assistant, then in charge of another goiter clinic. The second surgeon removed the opposite lobe with no relief of symptoms. An x-ray examination made in two planes at my suggestion revealed the larynx and upper trachea lifted forward and pushed slightly away from the side of the original lobectomy. Upon this evidence I explored the thyroid region and enucleated an adenoma the size of a walnut hull which had recurred in the depths of the original lobe residue, with immediate disappearance of all symptoms. The gland has given her no more trouble though several years have elapsed and she is in excellent health. Careful analysis of the findings must be made in each case and the surgeon's best judgment exercised, as will be seen from a comparison of this case with that of D. M., (page 348) who responded to x-ray treatment, Lugol's solution, diet and rest, and was spared the strain of a second operation, which, by the way, presents many more difficulties, to be discussed later, than the primary operation.

**The length of time that should elapse before a second operation is undertaken** naturally presents one of the first problems. This is a matter wholly of selecting the period most favorable for separating the lobe from the structures which surround it. Kocher's original advice for abdominal operations was to wait six months at least. The same is probably true for the neck as well as other parts of the body. At the end of six months granulation tissue has long since become completely organized, excessive vascularity has disappeared, and fibrous adhesions have probably become as elastic as they ever

will. It is pretty safe to say that one should never perform a second thyroid operation in less than six months, and that there is probably nothing to be gained after waiting a year. This presupposes a very early recurrence, which is usually infrequent, but the statement is made to cover the subject in general.

Second resection is always incomparably more **difficult** than the first. The ease or difficulty with which the operation is done is almost entirely dependent upon the selection of the planes of cleavage while in the primary operation there is nothing to do but to follow the anatomic planes already established. Any surgeon who knows the anatomy of the blood vessels entering the thyroid, as well as its relation to the trachea and to the more minute structures between the trachea and the thyroid should be able to do a creditable goiter operation as far as technic is concerned. It is a totally different matter, however, in operations for recurrence. Instead of finding his way, he has to make his way, with every guiding plane obliterated, the lobe being definitely fixed in position by fibrous adhesions to every surrounding structure with which its relationship was disturbed by the first operation. What this means no mere description can express for the operator who is not experienced with these difficulties. These are certainly not operations for beginners, and in many instances they will tax every resource of the most accomplished thyroid surgeon—something which that master thyroid surgeon, Professor Kocher, sought to impress upon us.

Of the technical points involved, the **skin incision** deserves first mention. Generally it should follow the line of the original incision and should include excision of the primary scar provided it is unsightly or deforming. This is an especially important point to be considered in operating upon women, the surgeon having much more latitude when dealing with men. Again, age is a factor, since in older individuals less attention should be given to cosmetic features, all possible ingenuity being devoted to simplifying access to the tumor and facilitating its removal, thus subjecting the elderly patient to the least possible operative strain.

Real difficulties are encountered when the operator begins to **manipulate the small muscles** normally in contact with the thyroid gland. The region of their midline separation presents

sufficient difficulty, but this is slight in comparison to the area where the scar resulting from cross division of the ribbon muscles has plastered itself to the thyroid. More especially is this true if there has been any sort of interference with primary healing. For these reasons a surgeon should never attempt a second operation on the thyroid by the midline muscle approach; this statement assumes, of course, that the primary operation has dealt with a midline separation of the structures covering the thyroid. As a consequence of this, adhesions and scars reaching all the way from the skin to the trachea become so dense that it is next to impossible for the operator to find his way a second time in this region. The most extensive distribution of widely dilated veins is also noted here, which further complicates orientation because of excessive hemorrhage. This was especially true in the case of Miss R. (October 4, 1924) to the end that we gave up after trying to get into the depths between the midribbon muscles, closed the incomplete muscle incision, and carried out our usual lateral muscle procedure which contemplates a longitudinal split in the anterior portion of the sternomastoid muscle. This lateral method is to be recommended in nearly all operations for recurrence. In such patients the muscle coverings are always adherent to the lobes, but it is at least a physical possibility to separate them if one begins to work at a sufficient distance from the midline scar.

The adhesions around the thyroid are very much stronger than is the thyroid substance; therefore attempts to forcibly separate the two simply result in tearing into the gland with consequent hemorrhage and likelihood of leaving large portions of the gland behind. In many instances the best way to keep the lobe intact while removing it, is very slowly, with utmost care, to dissect it free from surrounding structures with a sharp knife, hemostasis being accomplished by continued gentle pressure of gauze under broad retractors against the wall from which the thyroid is cut. Gauze pressure on the tumor will prevent back bleeding from obscuring the field. If this is properly carried out, the tumor when removed, will be covered at many points with an exceedingly thin layer of muscle tissue. It seems to do little permanent harm measured by muscle function afterward, and is far preferable to tearing the tumor to pieces

with the attendant risks previously mentioned. In using this procedure one must always bear in mind the possibility of drawing out of the depths to the outer side of and behind the tumor and wounding one of the great veins which have become firmly attached to it. Such a vessel retracts very deeply, bleeds profusely and greatly embarrasses further steps of the operation. It has in at least one instance known to me rendered the patient's condition so desperate that the operation could not be finished.

Secondary thyroidectomy is always rendered **more bloody** than the primary one because the essential thyroid vessels have been destroyed at the first sitting, thus rendering the blood supply absolutely atypical in the secondary tumor. Another reason for its being more bloody and unsightly is that one is continually tearing across gland tissue and rupturing newly formed blood vessels which are numerous, apparently thin-walled, occupy wholly atypical positions, and are not well supported by newly formed thyroid tissue, hence their control is exceedingly difficult in contradistinction to what we find in working on the primary goiter.

This tearing into the gland may in many instances finally resolve itself into a procedure somewhat like a curettement of all the available thyroid tissue, perhaps better said, a blunt shelling out of everything within the thick, stiff connective tissue capsule. An operator who permits a surgical operation to degenerate into a procedure of this character is forced to abandon any attempt at hemostasis by the ordinary means and is obliged to pack the resulting cavity full of gauze and depend upon the pressure of the packs and bandages which surround the neck for ultimate control of the bleeding.

In one such case where the tumor projected well under the left clavicle I gave up in despair the attempt to shell it out and contented myself instead with thrusting a soldering iron down into what I considered the centrally located portion, hoping thus to devitalize most of the lobe and accomplish the cure of a toxic patient. The attempt was an utter failure and is by no means to be advised. It only rendered more difficult the later dissection of the lobe which proved absolutely necessary for the relief of the toxicity.

Not only is the use of curetting-like procedures, thermo-

cautery applications, etc., of little value, but these agencies prove extremely dangerous as a source of injury to the trachea, parathyroids, recurrent nerves, great vessels, and other structures in the vicinity of the thyroid gland.

The ultimate outcome of all fragmentary or incomplete operations for recurrence is, of course, likely to be a second or multiple recurrence. Inspection in a bloody field is unsatisfactory and small adenomata are overlooked, which later develop into thyroid growths comparable in size to the original tumors or perhaps even larger.

Repeated operations upon the thyroid gland are invariably followed by a characteristic **deformity of the front of the neck.** Such procedures involve an inevitable partial destruction of the thin muscular layer which covers the thyroid region in front. After this layer has been divided in different directions, and perhaps thin layers of it removed when adherent to the tumor, it later becomes the seat of contracting scars, resulting in a flattening deformity. This is a cosmetic rather than a functional damage; however, the importance of this consideration, so far as women are concerned at least, is so great that it furnishes another of the arguments for the exertion of every precaution for the prevention of recurrence.

**Conclusions.**—The whole subject of recurrence seems to resolve itself largely into a study of adenomatous goiter and hyperplasia. Surgeons in general have not given the possibility of recurrence due consideration. Its importance is being forced upon me at least by a large percentage of patients whose first question is after operation has been proposed, "Can the tumor return?" Our answer, I believe, should be based upon the following eleven conclusions which seem to develop naturally as one studies the subject.

1. Authors disagree greatly on the percentage of recurrence. Lack of experience and faulty surgical technic as well as difference of opinion regarding postoperative care may account for this variation in findings.

2. Slight recurrence may amount merely to a regenerative answer to the functional need—a splendid argument for postoperative anticipation of this need by the administration of specific drugs.

3. Recurrence is not to be confused with malignancy in which case the prognosis is much more grave.

4. There seems to be no limit to the number of times a goiter may recur. It is well to realize this when operating for a first recurrence, to be sure to remove as much of the gland tissue as possible and to take all precautions against a second or multiple recurrence.

5. Recurrence is found in adenomatous goiters more frequently than in any other type, and this, as pointed out throughout the chapter, is accounted for by the fact that tiny adenomata are sometimes unavoidably left in the residual tissue and later develop into tumors.

6. The younger the patient the greater are the possibilities of recurrence. This is explained partly by the fact that through necessity a greater amount of thyroid tissue is allowed to remain in a young person to meet the requirements of the active processes of growth. The response to this demand in regeneration of the gland affords still further explanation of the greater frequency of recurrence in youth.

7. In patients over forty the surgeon need have no fear of recurrence. If the younger patient can be kept under the care of a competent physician who by means of preventives can eliminate the chances of recurrence up to the age of forty, there is no likelihood of further trouble.

8. Of course, the more complete the resection, the less likelihood is there of recurrence. This, then, would place the responsibility of recurrence largely upon the surgeon.

9. Postoperative administration of iodine over a long period protects against recurrence in a great measure, while

10. Postoperative thyroid feeding is an absolute preventive.

11. Recurrence is comparatively frequent in patients whose ultimate postoperative care is neglected.

## References

[1]DeQuervain, F.: Goiter, 1924, Wm. Wood & Co.

[2]Klose, H., and Hellwig, A.: Ueber Kropfrezidive, Klin. Wchnschr., 1922, i, 1885. (Abst., Endocrinology, Sept.-Nov., 1923, vii, 890.)

[3]Dubs, J.: Klinische Erfahrungen bei 840 Kropfoperationen, mit besonderer Berücksichtigung der Kropf-Recidive und Recivid-Operationen, Schweiz. med. Wchnschr., 1922, lii, 901-908. (Abst. in Endocrinology, Sept.-Nov., 1923, vii, 877.)

[4]Halsted, W. S.: Personal communication.

[5]Hotz: Schweitz. med. Wchnschr., 1920, No. 1.

## CHAPTER XXI

## THE IDEAL GOITER CLINIC

The ideal goiter hospital would be one situated in a quiet section of the city, where the patients might enjoy absolute rest during their preparation and convalescence; however, since it is not always possible to obtain such a spot for a goiter clinic, it is necessary to create as nearly as possible the ideal in a general hospital best suited to this work. In the chapter on Preparation, page 98, the matter of selecting the best section of the hospital for the goiter work was taken up in full, that is, one that is quiet, free from the noise of elevator, operating room, x-ray laboratory, obstetric and pediatric wards; also one that affords plenty of sunshine and fresh air.

A few rooms on the operating room floor reserved and equipped with essentials for emergency treatment, gas machine, instruments for tracheotomy, etc., will aid materially in taking care of the patient who leaves the operating table in a serious condition, the one in whom bleeding or suffocation might be anticipated if ever.

Of far greater importance than the physical arrangement of the clinic in the hospital is the personnel. The secret of success in this special line of endeavor is possessed by no single individual; it lies rather in the practical ability of an entire hospital personnel experienced in the study and care of goiter patients,—every one who comes in contact with the patient from her entrance to her dismissal a goiter psychologist.

An agreeable **room clerk** who assigns the patient to her room and shows a personal interest in seeing that she is satisfied and comfortable is essential. One can readily understand the advantage of having the patient's mind put at ease by the first person with whom she comes in contact upon entering the hospital. It is preferable to have a room clerk who has had a satisfactory thyroid operation and thus shows an ideal scar; she not only understands the psychology of the goiter patient, but her very living presence together with the lack of a disfiguring scar inspires confidence as nothing else will.

In the ideal clinic as soon as the patient is placed in her room, she is met by a **nurse** thoroughly familiar with goiter work, whose quiet, reassuring manner adds further to the patient's peace of mind. The duties of the special nurse have been discussed in full in the chapters on Preparation and After-Treatment. She may further instill confidence into the patient by introducing her to other goiter patients in the hospital who have been operated upon the day before or several days previously and who are doing well, frequently able to walk into the new patient's room, if any visitors can be allowed. This tends to ease the patient's mind so far as disfiguring wounds and rapid perfect recovery are concerned. It is the duty of the nurse to do all within her power to free the patient from the usual hospital fear.

It is by far preferable to have an **interne** devote his entire time to the goiter service. He is to meet the patient as soon as she has been made comfortable by the nurse, to reassure her, and to cooperate with the different physicians on the staff, notifying them that the patient is in and what the general findings are. He plays a very important part in the successful treatment. He becomes well acquainted with the patient, accompanies her through the various examinations made by other physicians, metabolic rate determination, electrocardiographic examination, etc., constantly reassuring her. He sees her every day throughout the preparation, becomes familiar with her reaction to various drugs, sees her on the morning of the operation to be sure that she is properly prepared and sufficiently drowsy, and in the operating room she welcomes the quiet assurance of his familiar voice as she goes under the anesthetic. He also looks after the patient from day to day after operation, dresses the wound, and watches for any complications so that he can immediately advise the surgeon. When the surgeon values the part played by the really interested interne, he will exercise his best judgment in considering well the personality of the man he chooses for this service.

A supporting group of specialists is indispensable in a goiter clinic. The three signed chapters for which I am indebted to my coworkers give a very definite idea of what is meant by teamwork as far as attending physicians is concerned.

One of the first specialists necessary in consultation on the goiter case is the man skilled in **metabolism** studies. This work is usually done by the internist who observes the patient before and after operation and treats her for her medical needs during her hospital stay.

A **heart specialist** familiar with hearts in general and especially with goiter hearts is the next requisite. It is he who makes the electrocardiogram immediately after the patient's entrance into the hospital, and advises the surgeon of the condition of the heart in relation to operative risk, and suggests measures to put the heart in such condition as to withstand the shock of operation. He keeps watch over the heart of each patient and treats it both before and after operation. He is a constant consultant of the surgeon's.

A trained **laryngologist** is essential to every goiter staff. It is his duty to examine the larynx of each patient before operation and immediately following operation and at any time that symptoms arise leading one to suspect disturbance of laryngeal function. Should intubation be indicated, it is the laryngologist who performs the operation.

The **roentgenologist's** services are sought to aid in determining the position and contour of the trachea and in finding out whether there is a subclavicular or a substernal projection. His value varies directly with his experience in this special field. Frequently he is required to give x-ray treatments in cases of exophthalmic goiter, following ligations, etc., something which presupposes knowledge of a definite technic having in mind protection of the trachea and other objectives.

In this day when so much reliance is placed upon the laboratory worker, no staff would be complete without its **pathologist**, who confirms, or gives further information on, the diagnosis made, by gross and microscopic examination, and preserves the specimen for future study. It is well that every goiter surgeon keep in close touch with the pathologist's observations so as to keep himself well informed in goiter pathology.

Every member of the staff must be a goiter psychologist to some extent, as has been mentioned in the beginning of this chapter (toxic patients), if the ideal clinic is to be created.

# INDEX


A

Abductor paralysis, unilateral, 310
after-treatment, 332
tonus, 308
Acidosis, prevention of, 103
Adenocystoma, large multiple, removed by cross-cutting resection, 245
Adenoma, distinguishing from hyperthyroidism, 77
fetal, 41
indications for surgery in, 80
malignant, 44
thyroid and gallstone disease and appendicitis, operative sequence, 91
and postoperative hernia, operative sequence, 90
prolapse of uterus, operative sequence, 86, 89
toxic, and appendicitis and chronic metritis, operative sequence, 91
and myoma uteri, operative sequence, 87
and tuboovarian abscess, operative sequence, 87
hydrosalpinx, operative sequence, 88
Adenomatosis, 37
Adenomatous endemic goiter, 43
goiters, surgery in, 75
Adenomedullary carcinoma, 46
Adherent skin, stiff, after-treatment, 331
Adhesions, difficulty of displaying goiter in presence of, 189
encountered in recurrence operation, 352
to trachea, 296
Adhesive plaster to protect dressing, 232
Adrenalin test for hyperthyroid patients, 164
After-treatment, abductor paralysis of larynx, 332
aspiration pneumonia, 332
blebs and retained serum, 329
bowels, 334
cardiac disturbances, 333
deprivation, 336
diet, 334
digestive disturbances, 334
dressing, 328
exercise, 341
fluids in, 326
getting out of bed, 340
going home, 342
hygiene, 339
After-treatment—Cont'd
hypodermoclysis in, 328
in ligation, 138
infection, 330
lactation, 337
luminal in, 326
morphine in, 325
nurse for, 339
open wound, 328
packs and drains, 329
pain and stiff neck, 337
postoperative hemorrhage, 338
tetany, 338
proctoclysis in, 326
respiratory system, 332
retained serum, 329
secondary closure, 331
sedatives in, 324
skin clips and sutures, 328
sleep, 324
sore throat, 332
stiff adherent skin, 331
suffocation due to reactionary hemorrhage, 333
toxicosis, 329
vomiting, 334
work, resuming, 343
wound, 328
Age incidence in consideration of indications for surgery, 79
Anatomy of larynx, 302
Anemia from hemorrhage on table, 277
Anesthesia, 152
for simplified unilateral resection, 267
general, 158
ether, 158
ethylene gas, 152
infiltration with, 160
nitrous oxide, 152
infiltration, 160
in ligation, 126
local, 165
luminal as preliminary sedative, 155
morphine as preliminary sedative, 156
preliminary sedatives, 152
veronal as preliminary sedative, 154
Appendicitis and chronic metritis and adenoma thyroid, toxic, operative sequence, 91
Aspiration pneumonia, after-treatment, 332
Atropine as preliminary drug, 158
Automatic spreader for retracting lips of goiter wound, 241

B

Bacterial invasion in thyroiditis, 34
Basal metabolism, thyroid influence, 64
Bed, leaving, after operation, 340
Bilateral bloc resection, 206
  resection, cross-cutting, drained, 236
    ideal, 236
Blebs and retained serum, after-treatment, 329
Bleeding, control of, in resection without tourniquet, 206
Blood pressure in goiter, 67
Bloodiness of secondary thyroidectomy, 353
Boiling novocaine injections in preparation of patient, 112
  water, injection of, in preparation, 111
Bowels in after-treatment, 334

C

Cadaveric position of vocal cord, 315
Carcinoma, adenomedullary, 46
Cardiac disturbances, after-treatment, 333
  failure, remote, 300
  symptoms, cause of, in goiter, 49, 51
  treatment in goiter, 59
Cautery in preparation of patient, 113
Central nervous system, 290
Circulation in preparation of patient, 105
Clamps and rubber ligature, 197
  fewer, in rubber ligature technic, 201
  left in place, 208
  left in place on stump in emergency technic, 272
  marking resection plane, 204
  removal of, 209
Classification of histologic conditions of the thyroid, 47
Clips in wound closure, 224
Closure and dressing, 222
  in cross-cutting bilateral resection, 242
  partial primary, 226
  primary, 222
  secondary, 229
Collapse of trachea, 278
Collar incision, half, in unilateral resection, 251
    types of thyroidectomy, 234
Colloid goiter and prolapse of uterus, operative sequence, 89
    surgery in, 74
Complications, 277
  acute surgical lesion, 288
  adhesions to trachea, 296
  anemia from hemorrhage on table, 277
  cardiac failure, remote, 300
  central nervous system, 290
  collapse of trachea, 278
  disfiguring scar, 296
Complications—Cont'd
  edema and paralysis of larynx, 282
  following ligation, 139
  foreign body in wound, 289
  hematoma, 286
  hypothyroidism and myxedema, 292
  infection, 287
  intracardiac thrombosis and embolism, 290
  lactation, 301
  laryngeal, 282, 302 (*See* also Laryngeal complications)
  malignancy, 299
  postoperative hemorrhage, 280
    hyperthyroidism, 280
  pulmonary, 285
    embolism, 286
  referred pain, 288
  retention fever, 282
  shock, 279
  surgical rotation of the trachea, 278
  swallowing difficulty, 281
  tetany, 283
Congestive heart failure, 61
Constriction technic, 191
Cosmetic consideration in indication for surgery, 82
Cretinism, pathology, 39
Cross-cutting bilateral resection, closure of, 242
    drained, 236
  ribbon muscles, 180
Cyanosis in relation to general anesthesia, 160

D

Damage, type of, in consideration of indications for surgery, 82
Deformity of front of neck from repeated operations, 354
Deglutition, action of larynx during, 304
Deprivation, thyroid, after-treatment, 336
Diarrhea, after-treatment, 335
Diet, high caloric, low protein, 103
  in after-treatment, 334
  in preparation of patient, 102
Digestive disturbances, after-treatment, 334
Digitalis in treatment of heart, 59
Disfiguring scar, 296
Display of goiter, 184
Disturbances of laryngeal function, 307
Divergent strabismus, 70
Double vision, 70
Drainage in cross-cutting bilateral resection, 243
  indications for, 213
  materials, 214
  of intrathoracic goiter defects, 214
  routine, dangers of, 213
  rubber tube, method of introducing, 215

Drainage and packing, 212
Drains and packs, after-treatment, 329
Draping patient, 146
Dream state, 159
Dressing, 222, 227, 232
as splint for neck, 233
in after-treatment, 328
Drugs, preliminary, 152
Dyspnea in edema of larynx, 316

E

Edema and paralysis of the larynx, 282
of larynx as cause of dyspnea, 316
Electric treatment in preparation of patient, 109
Electrocardiography, 55
Elevators for use in exposing upper pole, 183
Embolism and thrombosis, intracardiac, 290
pulmonary, 286
Emergency technic, 265
Endemic goiter, 38
Endocrine activity, associated, in women, 70
Eradication of foci of infection in preparation of patient, 114
Ether anesthesia, 158
Ethylene gas, 152
Exercise in after-treatment, 341
Exophthalmic goiter and gallstone disease, operative sequence, 90, 92
indications for surgery, 81
pathology of, 35
preparation of patient, 111
surgery in, 75

F

Fetal adenomas, 41
Fever, retention, 282
Fibrous thyroiditis, 34, 35
Fluids, forced, in preparation of patient, 103
in after-treatment, 326
Foci of infection, eradication of, 114
Forced fluids in preparation of patient, 103
Forceps, for display of goiter, 185
Foreign body in wound, 289
symptoms in consequence of packing, 217

G

Gallstone disease and appendicitis, and adenoma thyroid, operative sequence, 91
and exophthalmic goiter, operative sequence, 90, 92
Gastrointestinal symptoms, risk in presence of, 76
Gauze left in wound, 209
packing, 216
advantages, 216
disadvantages, 217
General anesthesia, 158
Goiter clinic, ideal, 356
diet, routine, 103
endemic, 38
heart in, 49
hernia of lung complicating, 69
lingual, 294
malignant tumors, 44
pathology of, 32
recurrence, 344
surgery, history of, 21
mortality in early, 23
present era, 28
sepsis in, 25
technic of exposing, 184
unusual manifestations of, 64
Graves' disease, pathology of, 35

H

Heart failure, congestive, 61
in goiter, 49
prognosis, 57
morbid anatomy, 51
physical signs of failure, 53
specialist in goiter clinic, 358
treatment of, in goiter, 59
Hematoma, 286
Hemorrhage on table, acute anemia from, 277
postoperative, 280
treatment of, 338
Hemostasis by rubber ligature, 193
in resection without tourniquet, 206
Hernia of lung complicating goiter, 69
Histologic conditions of thyroid, classification of, 47
History of goiter surgery, 21
Home, returning after operation, 342
Hospital, management of patient after leaving, 117
Hydrosalpinx and adenoma thyroid, toxic, operative sequence, 88
Hygiene in after-treatment, 339
Hyoscine as preliminary sedative, 157
Hyperplasia in thyroid, term explained, 36
Hypersecretion in larynx or trachea, danger in operation, 158
Hypodermoclysis in after-treatment, 328
Hypothyroidism and myxedema, 292
distinguishing adenoma from, 77
mild, pathology of, 39
postoperative, 280
Hypertrophy of thyroid, term explained, 36

I

Ice bags in preparation of patient, 102
Ideal goiter clinic, 356
Incision, skin, 169
Indications for surgical treatment of goiter, 74
Infection, 287
  after-treatment, 330
  eradication of, in preparation of patient, 115
Infiltration anesthesia, 160
    alone, 165
    technic, 161
    under partial gas anesthesia, 161
Inflammations of thyroid, 33
Injection of chemicals in preparation of patient, 111
Interne in goiter clinic, 357
Intracardiac thrombosis and embolism, 290
Intrathoracic goiter, defects, drainage of, 214
    pole division, 183
Isthmus, adenomata in, 203

K

Karell diet in edema, 62
Knee and hip flexion as index of toxicity, 70
Knife angle in making incision, 174

L

Lactation, 301
  after-treatment, 337
Laryngeal complications, 302
    edema, 314
    myositis, 314
    recurrent paralysis, complete left, 310
    trauma to laryngeal nerve, 314
    treatment, 321
    unilateral abductor paralysis, 310
  function, disturbances of, 307
  functional disturbance after operation, 313
  muscles, intrinsic, action of, 302
  nerve, recurrent, surgical repair of, 322
  paralysis, classification of cases of, 317
    in goiter surgery, history of, 27
    of central origin, 308
Laryngologist in goiter clinic, 358
Larynx, anatomy of, 302
  closure during deglutition, 304
  edema and paralysis of, 382
  muscles of, 303
  nerves of, 306
Ligation, 122
  after-treatment, 138
  and thyroidectomy, interval between, 142
  anesthesia for, 126
  benefit to patient, 140
Ligation—Cont'd
  closure, 136
  complications, 139
  double, at one sitting, 125
  en masse in preparation of patient, 113
  incision, 130
  Lugol's solution limits, 124
  marking the neck, 128
  of second side, 125
  passing ligature, 135
  selection of patient, 122
  skin wound closure, 137
  technic, 128
  test of patient's power to cooperate, 123
Lingual goiter, 294
Local anesthesia, 165
Lower pole, resection of, 197
Lugol's solution in preparation of patient, 105
    limits ligation, 124
Luminal as preliminary sedative, 155
  in after-treatment, 326
Lung hernia complicating goiter, 69

M

Malignancy, 299
Malignant disease, in indication for surgery, 83
  growth in thyroid stump, 345
  tumors, of thyroid, pathology, 44
Mania from hospital fright, 116
Marking neck for ligation, 128
  skin for incision, 172
Mechanical considerations in indications for surgery, 82
Menstrual irregularities associated with goiter, 70
Mental attitude of toxic thyroid patient, 116
Metabolic rate, influence of Lugol's solution on, 108
Metabolism studies in goiter clinic, 358
Midribbon muscle split, 179
Mischel wound clips, 224
Morbid anatomy of heart in goiter, 51
Morphine as preliminary sedative, 156
  in after-treatment, 325
Mortality in goiter surgery, early, 23
Muscles of the larynx, 303
Mydriasis as manifestation of goiter, 70
Myoma uteri and adenoma thyroid, toxic, operative sequence, 87
Myxedema and hypothyroidism, 292
  pathology, 39

N

Nasal tube for administration of fluid in after-treatment, 327
Neck deformity from repeated operation, 354

Nerves of larynx, 306
Nitrous oxide gas, 152
Novocaine as infiltration anesthetic, 168
  boiling, injections in preparation of patient, 112
Nurse in goiter clinic, 357
  rôle of, in preparation of patient, 99
  special, in after-treatment, 339
Nursing mother, 301
Nutrition, state of, as guide to surgical procedures, 119

O

Open wound, after-treatment of, 328
Operation, secondary, and thyroidectomy, 85
Operative considerations in recurrence, 349
  (exophthalmic) preparation of patient, 111
Ovarian activity associated with goiter, 70

P

Packing and draining, 212
  gauze, 216
  removal of, in emergency technic, 275
  rubber dam, 218
  vaseline, 217
Packs and drains in after-treatment, 329
Pain and stiff neck, after-treatment, 337
Paralysis, laryngeal, classifications of cases of, 317
  of vocal cord from pressure, indication for surgery, 83
Parasitic thyroiditis, 35
Parathyroids, protection of, in display of goiter, 186
Parenchymatous goiter, indications for surgery in, 80
Partial primary closure, 226
  resection, informing patient of, 260
Pathologic anatomy of thyroid gland, as indication for surgery, 79
Pathologist in goiter clinic, 359
Pathology of exophthalmic goiter, 35
  of goiter, 32
Phonation, recurrent paralysis, 316
Physical signs of cardiac failure, 53
Platysma, cross-dividing, 239
  incision in simplified unilateral resection, 269
  muscles, division of, 176
Pneumonia, aspiration, after-treatment, 332
Position on table and draping of patient, 146
Postoperative collection of blood serum, removal of, 330
  hemorrhage, 280
    after-treatment, 338
Postoperative—Cont'd
  hernia, and adenoma thyroid, operative sequence, 90
  hyperthyroidism, 280
  laryngeal function disturbance, 313
  tetany, treatment, 338
Preliminary sedatives, 152
Preparation of patient, 95
    cautery in, 113
    circulation in, 105
    diet in, 102
    electric treatment in, 109
    eradication of foci of infection, 114
    ice bags, 102
    injection of chemicals in, 111
    ligation, 122
    ligation en masse, 113
    Lugol's solution in, 105
    management of patient, after leaving hospital, 117
    nurse in, 99
    operative, 111
    radium in, 109
    rest in bed, 97
    sedatives in, 101
    stimulants prohibited, 104
    veronal in, 101
    x-ray in, 109
Primary closure, 222
Proctoclysis in after-treatment, 326
Ptyalism as manifestation of goiter, 69
Pulmonary complications, 285
  embolism, 286

Q

Quiet spot for preparation of patient, 98
Quinidine in treatment of heart, 60

R

Radium in preparation of patient, 109
Recurrence, 344
  adhesions encountered in operation for, 352
  indications for second operation in, 350
  operative considerations in, 349
  skin incision in operation for, 351
  time that should elapse between second operation, 350
Recurrent laryngeal nerve, anatomy of, 306
    surgical repair of, 322
    thyroidectomy technic in relation to, 312
  paralysis, complete left, 310
Referred pain, 288
Resection, 191
  clamps left in place, 208
  coughing to test for bleeding points, 207
  ideal bilateral, closed, 236

Resection—Cont'd
partial, informing patient of, 260
plane, marking, 204
suture material, 207
suturing stump, 196
with tourniquet, 191
contraindications, 202
without tourniquet, 203
Resistance, lack of, in exophthalmic goiter patients, 66
Respiratory system in after-treatment, 332
Rest after leaving hospital, 118
in bed, 96
Retained serum after-treatment, 329
Retention fever, 282
Ribbon muscles, cross-cutting, 180, 240
division of, 178
Riedel's disease, 34, 35
Roentgenologist in goiter clinic, 358
Room clerk in goiter clinic, 356
Rubber dam packing, 218
ligature in actual resection, 192
in simplified unilateral resection, 272
technic, contraindications, 202
tube drain, method of introducing, 215

S

Sand pillow under shoulders, 146
Scar, disfiguring, 296
Secondary closure in after-treatment, 331
wound closure, 229
Sedatives, hyoscine, 157
in after-treatment, 324
in preparation of patient, 101
luminal, 155
morphine, 156
preliminary, 152
veronal, 154
Sepsis in goiter surgery, history of, 25
Shock, 279
Simplified unilateral resection, 265
anesthesia, 266
platysma incision, 269
removal of second lobe, 276
ribbon muscles divided, 271
upper pole divided, 271
Skin bridge in unilateral resection, 250
clips and sutures, in after-treatment, 328
incision, 169
angle of knife important, 174
cosmetic considerations, 169
in cross-cutting bilateral resection, 241
in goiter surgery, history of, 28
in operation for recurrence, 351
in second operation, 351
in simplified unilateral resection, 267
in unilateral resection, 252
marking, for ligation, 128
for thyroidectomy, 172
slipping of, in unilateral resection, 251
Sleep in after-treatment, 324
Sore throat, after-treatment, 332
Specific, exophthalmic, in preparation of patient, 105
Split sheet in draping patient, 150
Spreader for retracting lips of goiter wound, 241
Stealing the goiter, 152
Sternomastoid muscle, moulding of goiter by, 72
Stiff neck, after-treatment, 337
Stimulants forbidden after leaving hospital, 118
in preparation of patient, 104
Strain as test for bleeding points after resection, 207
Strumitis, 33
Stump, clamps left in place, 208
in relation to surrounding structures in rubber ligature technic, 200
testing for bleeding points, 207
Subcutaneous silkworm suture, 225, 227
Substernal goiter, 83
Suffocation due to reactionary hemorrhage, 333
Sugar in urine in thyroid disease, 70
Surgery of goiter, risks considered, 76
Surgical lesion, complicating acute, 288
repair of recurrent laryngeal nerve, 322
rotation of trachea, 278
Suture material in thyroidectomy, 207
subcutaneous silkworm, 225, 227
Suturing stump after resection, 196
Swallowing, difficulty of, 281
Symptoms, cardiac, in goiter, 51

T

Table, position on, 146
Tachycardia, 51
Technic, actual resection, 191
closure and dressing, 222
display of goiter, 184
draining and packing, 214
dressing and closure, 222
of thyroidectomy in relation to recurrent laryngeal nerve, 312
packing and draining, 212
platysma muscle division, 176
ribbon muscles, 178
skin incision, 169
unilateral resection, 246
upper pole, 181
Teeth, infection of, eradication of, in preparation of patient, 115
Tenaculum forceps for grasping goiter, 185
Tetany, 283
in goiter surgery, history of, 26
postoperative, treatment, 338
Thrombosis and embolism, intracardiac, 290

Thyrocardiacs, indications for surgery in, 77
Thyroid, administration of, 295
inflammation of, 33
surgery, present era, 28
tissue, allowed to remain, 210
Thyroidectomy, analysis of various types of procedure, 235
and another operation, 85
and ligation, interval between, 142
choice of type, 234
emergency technic, 265
four types of, 234
preparation of patient for, 95
technic of, in relation to recurrent laryngeal nerve, 312
Thyroiditis, 33
parasitic, 35
Riedel's disease, 35
Thyropriva in goiter surgery, history of, 26
Tourniquet, resection without, 203
use of, in resection of goiter, 191
Toxic adenoma, indications for surgery in, 76
Toxicity, knee and hip flexion as index of, 70
Toxicosis, after-treatment, 329
Trachea, adhesions to, 296
collapse of, 278
protected by rubber ligature technic, 193
surgical rotation of, 278
Tracheitis, 321
Treatment, cardiac, 59
of laryngeal complications, 321
Tuboovarian abscess and adenoma thyroid, toxic, operative sequence, 87

U

Unilateral collar operation, advantages, 263
resection, 246
advantages, 263
development, 246
dissecting skin flaps, 252
indications, 261
objections, 263
packing, 257
removal of second lobe, time for, 258
simplified, 265 (*See* also Simplified unilateral resection)
skin incision, 252
stump treatment, 256
technic, 246
upper pole division, 255
Upper pole divided in unilateral resection, 255
division of, 181
Uterus, prolapse of, and adenoma thyroid, operative sequence, 86, 89
and colloid goiter, operative sequence, 89

V

Vaseline packing, 217
Vasomotor manifestations in goiter, 69
Veronal as preliminary sedative, 154
in preparation of patient, 101
Visitors, limitation of, in preparation of patient, 98
Vocal cord, cadaveric position, 315
Vomiting, after-treatment, 334

W

Wire guard on operating table, 149
Work, resuming after operation, 343
Wound, after-treatment of, 328
open, after-treatment of, 328

X

X-ray in preparation of patient, 109

LANE MEDICAL LIBRARY

To avoid fine, this book should be returned on or before the date last stamped below.

MAR 30 27
SEP - 1 1927
FEB 23 1928
JUN 18 28
OCT - 4 28
OCT 24 1928
FEB 11 1929
JUN 19 29
APR 22 30
MAY 20 30
APR 21 1931
MAY 10 1933
MAY 23 1932
MAY 30 1932
NOV 29 1932
MAY - 7 1934
SEP - 1 1934
FEB 16 1935
JUN 11 1935
JAN 21 1936
DEC 7 1951
JAN 15 '81
JAN 22 1981

1926 goiter.

| NAME | DATE DUE |
| --- | --- |
| J. H. Davis | JAN 21 1936 |
| E. Mayd | JAN 25 1936 |
| L. Davis | DEC 7 1951 |
| | FEB 22 1952 |